

— Abstract —

Simple Anterior Dislocation of the Elbow - Case Report

Bong-Jin Lee, M.D., Sung-Rak Lee, M.D., Seong-Tae Kim, M.D.*

Department of Orthopaedic Surgery, Halla General Hospital, Jeju, Korea

An anterior dislocation of the elbow without a fracture of the olecranon is an extremely rare injury. This paper reports a 36-year-old male who stumbled and fell on his outstretched hand during a soccer game. The anteroposterior and lateral radiographs indicated a simple anterior dislocation of the elbow, which was reduced using a closed method. The elbow joint was stable in the range of motion, but the sensation of the two ulnar digits was still reduced. MRI was useful for the identification of the pathoanatomy. At the follow-up examination three months after the initial trauma, the hypesthesia has fully recovered and the patient regained the full range of the elbow and forearm motion without pain and instability. After 18 months, the patient had a normal elbow function, and could play various sports. If an anterior elbow dislocation is detected early, a closed reduction with careful pathoanatomical considerations would be successful.

Key Words: Elbow, Anterior dislocation, Closed reduction, MRI

Most dislocations of the elbow occur posteriorly. An anterior dislocation of the elbow is extremely rare and is usually encountered in children. In adults, the olecranon is usually fractured^{5,10).}

We experienced a case of an anterior

elbow dislocation without a fracture, which was treated with a closed method. This case stresses the importance of an early closed reduction and the usefulness of MRI in delineating the pathoanatomy.

: *

1963-2

Tel: 064) 740-5111, Fax: 064) 743-3110, E-Mail: schstk27@hanmail.net

CASE REPORT

A 36-year-old male stumbled and fell on his outstretched hand during a soccer game. He complained of severe pain in his right elbow, which was swollen, bruised, and deformed. The elbow was held in 50° of flexion with the palm facing forward. The elbow could be flexed passively, whereas an extension was limited to 40°. The circulation in his right hand was normal, but there was reduced sensation in his ring and little finger. The anteroposterior and lateral radiographs indicated a simple anterolateral dislocation of the elbow (Fig. 1).

The reduction was performed at 30 minutes after the injury, without any analgesics or anesthetics. After gentle traction of the forearm was applied in 50° of flexion of the elbow whilst an assistant stabilized the arm and a downward and

backward force was applied to the forearm, the elbow appeared to be reduced with a clunk being heard. The passive motion of the elbow was fully restored and the elbow joint was stable in the range of motion. The subjective power of the adduction and abduction of the fingers was unaffected, but there was still reduced sensation of the two ulnar digits. The radiographs taken after the closed reduction revealed a complete reduction without abnormal findings (Fig. 2). MRI was taken to identify the pathoanatomy and to decide if surgery is needed. MRI revealed the medial collateral ligament and the lateral collateral ligament were injured, but the bony structures were preserved (Fig. 3). And there were partial tear of the brachialis muscle, well preserved biceps and triceps muscle, and diffuse edema of soft tissue in posterior part of the elbow (Fig. 4).

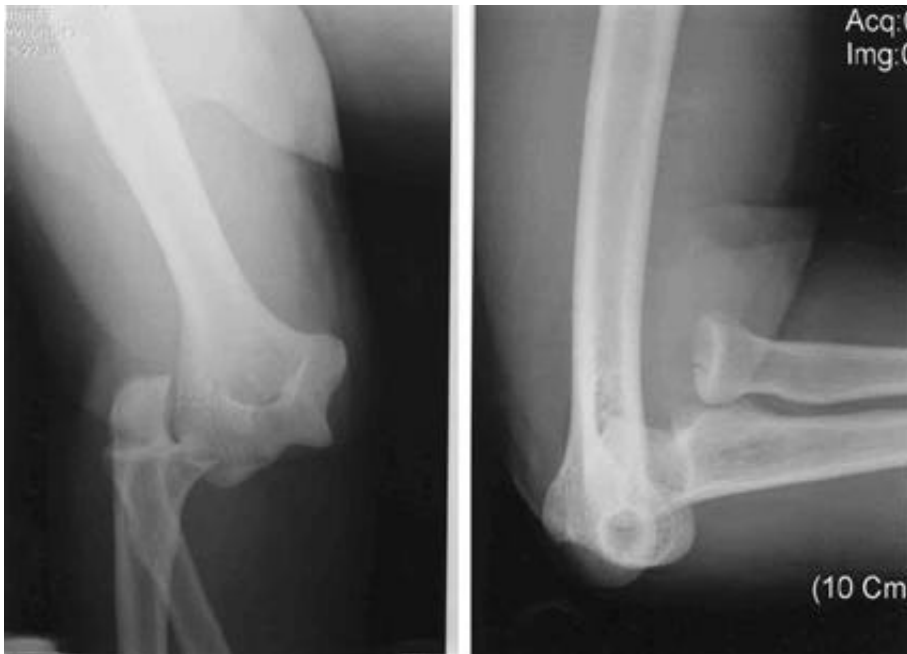

Fig. 1. Initial radiographs show a simple anterolateral dislocation of the elbow.

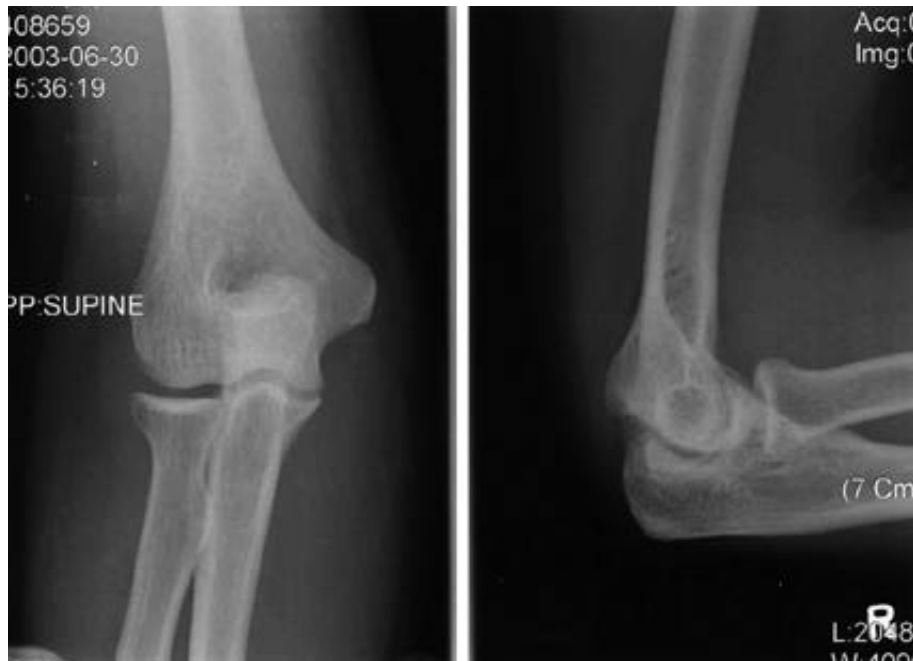

Fig. 2. Radiographs taken after the closed reduction reveal a complete reduction of the elbow without an associated fracture.

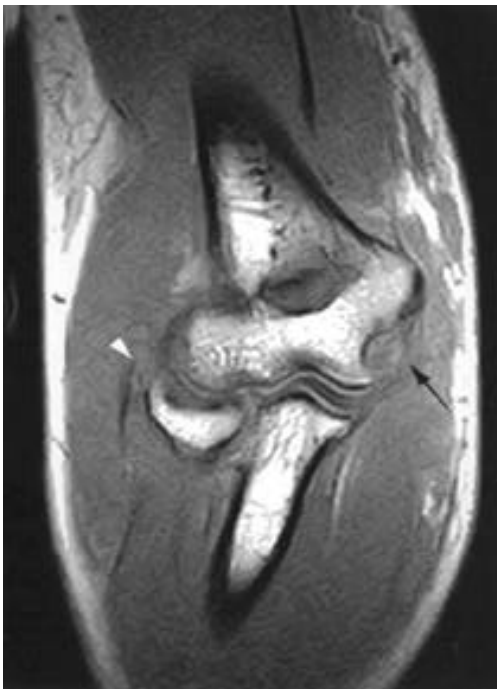


Fig. 3. T1-weighted coronal MRI reveals that the medial collateral ligament (arrow) and the lateral collateral ligament (arrow head) were injured, but the bony structures were preserved.

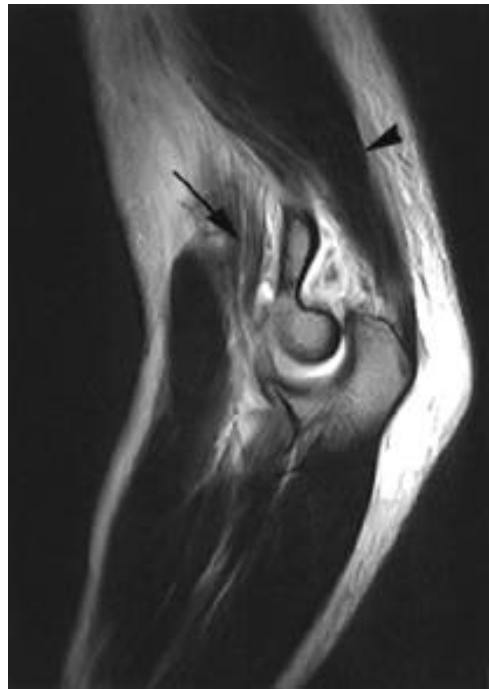


Fig. 4. T2-weighted sagittal MRI reveals that partial tear of the brachialis muscle (arrow), well preserved triceps muscle (arrow head), and diffuse edema of the soft tissue in posterior part of the elbow.

Initially, the elbow was immobilized for one week in a long arm splint at 90° flexion and forearm in full supination due to the swelling, and was then immobilized in a long arm cast in neutral rotation for an additional two weeks. Indomethacin was prescribed for three weeks in order to prevent heterotopic ossification. At the three weeks after the trauma, the patient was instructed to perform an active flexion and extension exercise of the elbow, with a functional hinged brace. At the fifth weeks after the trauma, an active range of motion exercise of the elbow and the forearm was progressively performed without protection.

At the six weeks after the trauma, ulnar neuropathy was demonstrated on an electromyography and a nerve conduction study despite the subjective improvement in sensation. At the follow-up examination three months after the trauma, the hypesthesia was fully recovered and the patient regained pain-free full range of motion of the elbow and the forearm. There were no valgus instability and varus instability in the elbow joint. At the one and half years follow-up, the patient had a normal elbow function, and could play various sports. According to Broberg and Morrey's index, the functional performance score was excellent (Motion, 38 points; Strength, 20 points; Stability 4 points; Pain, 35 points).

DISCUSSION

A posterior dislocation is the most common dislocation of the elbow. An anterior dislocation of the elbow with a fracture of the olecranon is uncommon, whilst an anterior dislocation of the elbow without a

fracture of the olecranon is quite rare¹²⁾. Linscheid and Wheeler reported 110 elbow dislocations, of which only two were anterior⁷⁾. Mehlhoff, in a more recent review of a simple elbow dislocation in adults, listed fifty-two cases, none of which were anterior⁸⁾. Only sporadic case reports associated with vascular or nerve injury have been presented^{2,6)}.

The classification of elbow dislocations, which is based on the direction of the dislocation, includes the following 5 types: posterior (which is subdivided into direct posterior, posterolateral, and posteromedial), anterior, lateral, medial and divergent¹¹⁾. The current case is an anterior one, especially anterolateral one. The available radiographs of various anterior elbow dislocations were reviewed, and there was only 1 case of an anterolateral dislocation with an olecranon fracture⁵⁾.

Colson reported that an anterior dislocation without a fracture of the olecranon occurs in three ways: first, by the forced flexion of the forearm; second, by fixing the upper arm and a turning the forearm around the axis of the arm; and third, by hyperextension of the forearm²⁾. Torchia reported that external rotation of the humerus, extension of the elbow, supination of the forearm, and extension of the wrist combined with high valgus load on the elbow was a mechanism of an anterior dislocation in an arm wrestler¹³⁾. Ligamentous and capsular laxity including Ehlers-Danlos syndrome¹⁾, and an anatomic variation including increased inclination of the humeral trochlear groove or the shallowness of the ulnar notch³⁾ were thought to be the predisposing factors of the elbow dislocation.

Most reports agree that the most com-

mon mechanism in an anterior dislocation is a force directed forward on the flexed elbow, most commonly resulting from a fall. The mechanism of injury in the current case, which was investigated by the patient's history, radiographs and MRI, is believed to be a turning the forearm laterally around the axis of the arm.

Complications of an anterior dislocation are rare. However, when encountered, they usually include brachial artery and ulnar nerve injuries. The latter may be manifested by a persistent sensory and motor loss, although transient deficits are more often noted, and are relieved by an expedient reduction^{2,6)}. In our case, the ulnar nerve palsy recovered three months after the injury. Heterotopic ossification in the periarticular tissues, such as capsule, ligaments, and muscle, occurs in up to 55% of elbow dislocations⁴⁾. Indomethacin, 25 mg orally three times per day for 3 weeks, was prescribed in order to prevent heterotopic ossification.

A reduction of an anteriorly dislocated elbow is usually accomplished under adequate anesthesia. In complicated dislocations, it may be impossible to achieve and maintain reduction due to the extensive capsular disruption or the interposition of ligaments, muscles or bony fragments. In such cases, an immediate open reduction is essential²⁾. Various opinions exist as to the duration of immobilization. Three to four weeks of immobilization has been generally advised. However, in a stable reduction, initiating motion within the first week of injury is associated with the most favorable result⁴⁾. The medial collateral ligament usually heals after an elbow dislocation, perhaps because of the vascularized muscles that surround it⁹⁾. We con-

sider that the healing capacity of the medial collateral ligament and less damage of the lateral collateral ligament contribute the stability of the elbow joint in our case.

It is believed that if the anterior elbow dislocation is detected early, a closed reduction with careful pathoanatomical considerations would be successful.

REFERENCES

- 1) **Blatz DJ**: Anterior dislocation of the elbow. Findings in a case of Ehlers-Danlos syndrome. *Orthop Review*, 10:129-131, 1981.
- 2) **Colson A**: Essai sur la luxation de l'extremite superieure du cubitus en bas et en avant sans fracture de l'olecrane. These de Concour, Paris, 46:1-28, 1842 (cited from Oury JH, Roe RD and Laning RC: A case of bilateral anterior dislocations of the elbow. *J Trauma*, 12:170-173, 1972).
- 3) **Habernek H, Ortner F**: The influence of anatomic factors in elbow joint dislocation. *Clin Orthop*, 274:226-230, 1992.
- 4) **Hildebrand KA, Patterson SD and King GJW**: Acute elbow dislocations. *Orthop Clin North Am*, 30:63-79, 1999.
- 5) **Jaber S and Liebergall M**: Anterior dislocation of the elbow joint with fracture of the olecranon. *Contemp Orthop*, 24:714-716, 1992.
- 6) **Jackson JA**: Simple anterior dislocation of the elbow joint with rupture of the brachial artery. Case Report. *Am J Surg*, 47:479-486, 1940.
- 7) **Linscheid RL and Wheeler DK**: Elbow dislocations. *J Am Med Assoc*, 194:113-118, 1965.
- 8) **Mehlhoff TL, Noble PC, Bennet JB and Tullos HS**: Simple dislocation of the elbow in the adult. Results after closed treatment. *J Bone Joint Surg*, 70-A:244-249, 1988.
- 9) **O'Driscoll SW**: Classification and evaluation of recurrent instability of the elbow. *Clin Orthop*, 370:34-43, 2000.
- 10) **O'Driscoll SW**: Elbow dislocations. In: Morrey BF ed. *The elbow and it's disorders*. 3rd ed. *WB Saunders*: 409-420, 2000.
- 11) **Sheps DM, Hildebrand KA and Boorman RS**: Simple dislocations of the elbow: evaluation and

- treatment. *Hand Clin*, 20:389-404, 2004.
- 12) **Srivastava KK and Kochhar VL**: Forward dislocation of the elbow joint without fracture of the olecranon. *Austr N Z J Surg*, 44:71-74, 1974.
- 13) **Torchia ME, DiGiovine NM**: Anterior dislocation of the elbow in an arm wrestler. *J Shoulder Elbow Surg*, 7:539-541, 1998.