

Knotless Suture Anchor Bankart

— Abstract —

Results of Arthroscopic Bankart Repair Using Knotless Suture Anchor

**Bo-Hyun Kim, M.D., Sang-Bum Kim, M.D., Jae-Yong Byun, M.D.,
Chang-Wha Hong, M.D., Chan-Ha Hwang, M.D., Ju-Seok Yoo, M.D.**

Department of Orthopedic Surgery, CheongJu St. Mary Hospital, ChoengJu, Korea

Purpose: This paper analyzes the results of arthroscopic bankart repair for anterior recurrent dislocation following a trauma on shoulder.

Material and Methods: The subjects were twenty-three (23) cases that were available to follow up for more than eighteen months during the period from November 2001 to June 2003 and were chosen from patients to whom arthroscopic bankart repair was applied using a knotless suture anchor for their traumatic anterior recurrent dislocation on the shoulder. Their average age was 28 (ranging from 15 to 60) with 20 males and 3 females. The injury from sports activities accounted for the most cases with 14 subjects. The average follow-up period was 27 months (ranging from 18 months to 35 months). There were 19 cases of bankart lesions, 4 cases of ALPSA lesions and associated with 5 cases of partial tear in the rotator cuff. The anchors employed were knotless anchor (Mitek) for all the cases. Rowe scoring scale was adopted to judge the results after operations. Patients' subjective satisfaction and range of motion of external rotation were addressed together.

Results: Rowe scores showed that 20 cases (87%) reaches the level of ' good ' and hinger. The average patients' satisfaction accounted for 90 points out of 100. It was also found that external rotations averagely decreased by 6.5 degree when the range of motion was in at the side.

Conclusion: There were satisfactory results of arthroscopic bankart repair using knotless suture anchors as an operative treatment for traumatic anterior recurrent dislocation on shoulder.

Key Words: Shoulder, Traumatic anterior instability, Arthroscopic bankart repair, Knotless suture anchor

589-5

Tel: 043) 219-8140, Fax: 043) 213-8227, E-Mail: sangbume@hitel.net

*
2004

Bankart 1938 가 3
 Bankart가 “essential lesion”
 , Rowe¹⁹⁾ 1980 가
 Bankart 가 2
 (MRI) 18
 (MRA)
 anchor knotless anchor
 , 4 . 8
 suture anchor Mini-Revo (Linvatec Inc.,
 Largo, Florida) FastTak (Arthrex
 Inc., Naples, Florida)
 2.
 anchor suture
 가

Knotless anchor(Mitek, West-wood, MA)
²³⁾ (Fig. 1)

knotless suture anchor
 Bankart 가

1.
 2001 11 2003 6
 knotless anchor
 Bankart 23
 18
 29 (18 ~ 37)

1 가 ,




Fig. 1. Metallic knotless suture anchor design

— : Knotless Suture Anchor Bankart —

Largo, Florida)

shuttle relay

15 utility loop anchor slot

outside anchor loop anchor

to inside Bankart utility loop

liberator knife(Lin- anchor loop anchor

vatec Inc., Largo, Florida) utility loop anchor

rasp burr anchor

Grasper - 3 5 (Fig. 2).

90

Arthrocare coblation (Arthrocare, Sunny- 1

vale, California) anchor 3

punch T

anchor 5~6

anchor 가 6 (Theraband)

가 6

suture punch suture hook anchor

shuttle-relay(Linvatec Inc.,

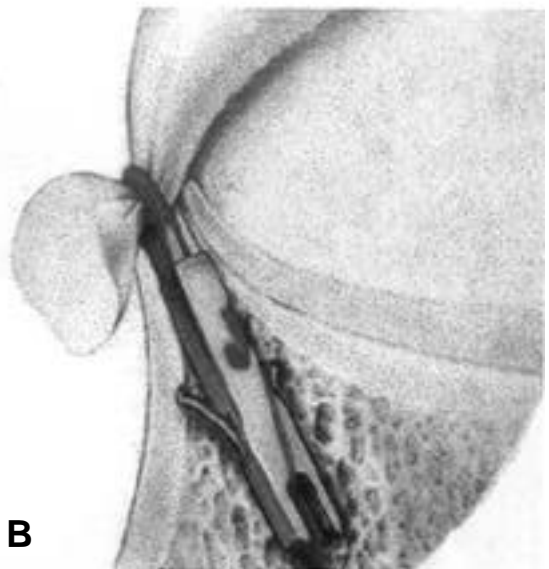
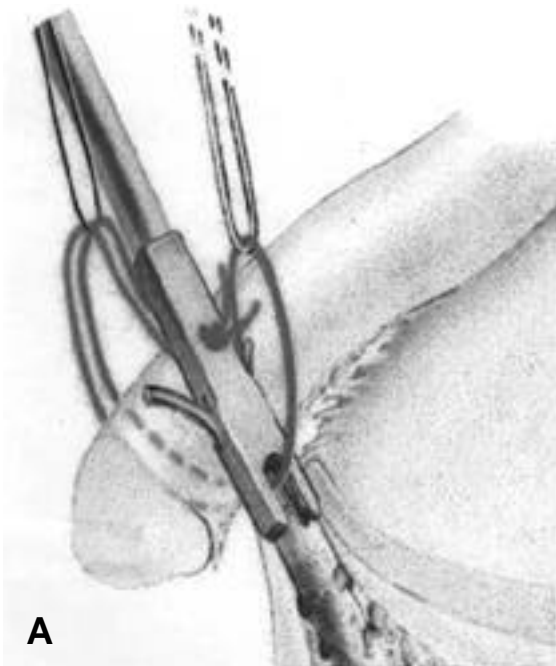


Fig. 2. (A) The Utility loop and balancing loop are used to balance the Anchor loop during anchor insertion (B) The Utility loop and inserter rod are removed after a secure , low profile repair is achieved

3. 가 , Hill-Sachs 23 , SLAP 6 , 5 , 5 Rowe³⁹⁾ 가 , ALPSA 4 , 1 , Visual analogue scale (Anchor) 2 , Anchor loop 가 6 . Anchor 가 1 가 . Anchor 3 anchor (Fig. 3). ALPSA Hill-Sachs Bankart 10 , Bankart SLAP (Fig. 4). Rowe³⁹⁾ 가 가 20 (87%) , Rowe 88.5 (33~100) . 6.5 (0 ~ 20) , 100 62 91 가 . Bankart 19



Fig. 3. The anchor is Broken during insertion at lowest hole

8 1 - , Hill-Sachs 23 , SLAP 6 , 5 , 5 , ALPSA 4 , 1 (Anchor) 2 , Anchor loop 가 6 . Anchor 가 1 가 . Anchor 3 anchor (Fig. 3). ALPSA Hill-Sachs Bankart 10 , Bankart SLAP (Fig. 4). Rowe³⁹⁾ 가 가 20 (87%) , Rowe 88.5 (33~100) . 6.5 (0 ~ 20) , 100 62 91 가 . Bankart 19 가 가 Bankart Bankart 8). 55% 100% . Berg Ellison⁸⁾ 69 89% Bankart , 59% Hill-Sachs , Adams⁴⁾ 97% Bankart , 82% Hill-Sachs Hill-Sachs large bone defect, superficial bony lesion, cartilage scuffing , Bankart 19 (83%), ALPSA 4 (27%), Hill-Sachs 23 (100%) . , Hill-Sachs Bankart

pullout strength 가 1 Ethibond 가
(Ethicon, Somerville, NJ) anchor loop가
anchor anchor Bankart
anchor loop가 anchor 가
Knotless anchor knotless anchor가 suture
suture anchor anchor
anchor anchor
suture anchor 가
anchor anchor 3 6 가
가 가 knotless 1,11,12,13)
anchor anchor 가 2,6,24)
knotless anchor
1990 suture
anchor 가
20,21) 1
90
3
suture anchor T
anchor , suture , anchor 5~6
, anchor (Theraband)
15,25) Antonogiannakis
5) knotless anchor 12
anchor
1 , anchor
Thal²⁴⁾ 27 anchor loop
3 , anchor , knotless anchor
가 2 , 3 5,24)
anchor anchor 1 (4.3%)
가
anchor Bankart
Anchor loop가 가 6 SLAP suture anchor
5 5 knotless anchor
anchor loop Hill-Sachs
anchor Hill-
, anchor slot anchor loop가 Sachs Hill-
Zumstein³⁰⁾ Sachs
knotless anchor가

20
가 , knotless anchor
Bankart 가

knotless anchor Bankart
가 가

REFERENCES

- 1) , , : Bankart , 2:149-153, 2002.
- 2) , , , , , : Bankart , 1:79-88, 2002.
- 3) **Abrams JS, Savoie FH, Tauro JC**: Recent advances in the evaluation and treatment of shoulder instability: Anterior, posterior and treatment of shoulder instability. *Arthroscopy*, 18:1-18, 2002.
- 4) Adams JC : Recurrent dislocation of the shoulder. *J Bone Joint Surg*, 30B:26-38, 1948.
- 5) **Antonogiannakis E, Yiannakopoulos CK, Karliaptis K, Karabalis C**: Case Report Late disengagement of a knotless anchor. *Arthroscopy*, 18:40-44, 2002.
- 6) **Bacilla P, Field LD and Sovie FH**: Arthroscopic Bankart Repair in a hing demand patient population. *Arthroscopy*, 13(1):51-60, 1997.
- 7) **Bankart ASB**: The pathology and treatment of recurrent dislocation of the shoulder-joint. *Br. J Surg*, 26:23-29, 1938.
- 8) **Bankart ASB**: Recurrent or habitual dislocation of the shoulder joint. *Br Med J*, 2:1132, 1923.
- 9) **Berg EE and Ellison AE**: The inside-out Bankart procedure. *Am J Sports Med*, 18:129-133, 1990.
- 10) **Caspari RB and Savoie FH**: Arthroscopic reconstruction of the shoulder: the bankart repair. In:McGunity JB ed. *Operative Arthroscopy*, 2nd ed. Philadelphia, *Lippincott-Raven Co*: 695-723, 1966.
- 11) **Cole BJ, L Insalata J, Irrgang J, Warner JJP** : Comparision of arthroscopic and open anterior shoulder stabilization. *J Bone and Joint Surg Am*, 82:1108-1114, 2000.
- 12) **Gartsman GM, Rodkey TS, Hammmerman SM** : Arthroscopic treatmentof anterior-inferior glenohumeral instability. *J Bone Joint Surg Am*, 82:991-1003, 2000.
- 13) **Grana WA, Buckley PD, Yates CK**: Arthroscopic Bankart suture repair. *Am J Sports Med*, 21:348-353, 1993.
- 14) **Green MR and Christensen KP**: Arthroscopic versus open Bankart procedures : a comparison of early morbidity and complication.. *Arthroscopy*, 9(4):371-374, 1993.
- 15) **Ho E, Cofield RH, Balm MR**: Neurologic complications of surgery for anterior shoulder instability. *J shoulder Elbow Surg*, 8:266-270, 1999.
- 16) **Kandziora F, Jager A, Bischof F**: Arthroscopic labrum refixation for post-traumatic anterior shoulder instability. Suture anchor versus trnsglenoid fixation technique. *Arthroscopy*, 16:359-366, 2000.
- 17) **Kim S-H, Ha K-I, Kim S-H**: Bankart repair in traumaticanterior shoulder instability: Open versus arthroscopic technique. *Arthroscopy*, 18:755-763, 2002.
- 18) **Morgan CD and Bodenstab AB**: Arthroscopic Bankart suture repair: Technique & early results. *Arthroscopy*, 3:111-122, 1987.
- 19) **Rowe CR, Patel D and Southmayd WW**: The Bankart procedure: Long-term end-result study. *J bone joint surg*. 60-A: 1-16, 1978.
- 20) **Sperber A., Hamberg P, Karlsson J**: Comparison of an arthroscopic and an open procedure for posttraumatic instability of the shoulder: A prospective, randomized multicenter study. *J Shoulder Elbow Surg*, 10:105-108, 2001.
- 21) **Tamai K, Higashi A, Tanabe T, Hamada J**: Recurrences after the open Bankart repair: A Potential risk with use of suture anchors. *J Shoulder Elbow Surg*, 8:37-41, 1999.
- 22) **Tauro JC**: Arthroscopic inferior capsular split and advancement for anterior and inferior shoul-

- der instability: Technique and results at 2- to 5-year follow-up. *Arthroscopy*, 16:451-456, 2000.
- 23) **Thal R.**: A Knotless suture anchor: Technique for use in arthroscopic Bankart repair. *Arthroscopy*, 17: 213-218, 2001.
- 24) **Thal R.**: Knotless suture anchor fixation for shoulder instability, In: Miller MD and Cole BJ ed. Textbook of arthroscopy. 1st ed, Philadelphia, Saunders:113-121, 2004.
- 25) **Wall MS, Warren RJ, Barkin DE, Carrol MP**: Infected suture anchors in the shoulder. *Arthroscopy*, 14:973-1000, 1995.
- 26) **Warner JP and Warren RF**: Arthroscopic Bankart repair using a cannulated absorbable fixation device. *Op Tech Orthop*, 1:192-198, 1991.
- 27) **Weber SC**: A prospective evaluation comparing arthroscopic and open treatment of recurrent anterior glenohumeral dislocation.. *Orthop Trans*, 15:763, 1991.
- 28) **Wolf EM**: Arthroscopic capsulolabral repair using suture anchor. *Orthop Clin North Am*, 24:59, 1993.
- 29) **Zuckerman JD, Matsen FA III**: Complications about the glenohumeral joint related to the use of screws & staples, *J Bone Joint Surg Am*, 66:175-180, 1984.
- 30) **Zumstein M, Jacob HA, Schneeberger AG**: In vitro comparison of standard and knotless metal suture anchors. *Arthroscopy*, 20:517-520, 2004.