

— Abstract —

Arthroscopic Treatment of Stiff Elbow

**Kwang-Jin Rhee, M.D., Hyun-Dae Shin, M.D., Kyung-Cheon, Kim M.D.,
Chang-Hwa Hong, M.D., Ho-Sup Song, M.D.**

Department of Orthopaedic Surgery, Chungnam National University, Daejeon, Korea

Purpose: Limitation of motion of the elbow joint due to stiffness affect on life quality of the patients. So contracture of the elbow should be treated as soon as possible. Among the many treatment modalities, we described the result of arthroscopic treatment.

Materials and Methods: From Mar. 2000 to Mar. 2003, 40 patients, who received the arthroscopic treatment by author for contracted elbow, were the subjects. We estimated the range of motion (ROM) of elbow joint before and after surgery by goniometer. The clinical result was evaluated by Severance elbow scoring system. The final ROM was evaluated at the point of no further increasement of joint motion. Male ware 30 cases, female ware 7 cases, average 42.6 years old and mean follow up period were 31 months. During arthroscopic treatment we had done release of the joint capsule or resection, synovectomy, removal of loose bodies. We used traditional portals.

Results: The avarage preoperative ROM of elbow joint was 72.5 degree(range, 5 - 132 degree) and the increase-ment of ROM was totally 49.3 degree in flexion 26.5 degree and extension 22.8 degree. There was no other compli-cation.

Conclusion: Arthroscopic treatment for contracted elbow permit early joint ROM and it decrease the secondary injury to the elbow joint. Also there are few complications. It is thought to be a good treatment modality in contracted elbow joint.

Key Words: Stiff elbow joint, Elbow arthroscopy

:

640

Tel: 042) 220-7345, Fax: 042) 252-7098, E-Mail: hyunsd@cnu.ac.kr

— : —

2000 3 2003 3

0

145 가 40

100 30 130 가 30 가 7

¹⁰⁾ 42.6 (, 27~62) ,

31 (, 15~42) .

27 , 4 ,

9 ,

7 , 8 ,

5 ,

가 2 , 5 ,

1 ,

5 , 3 .

goniome

가 ter ,

가 가 ,

24

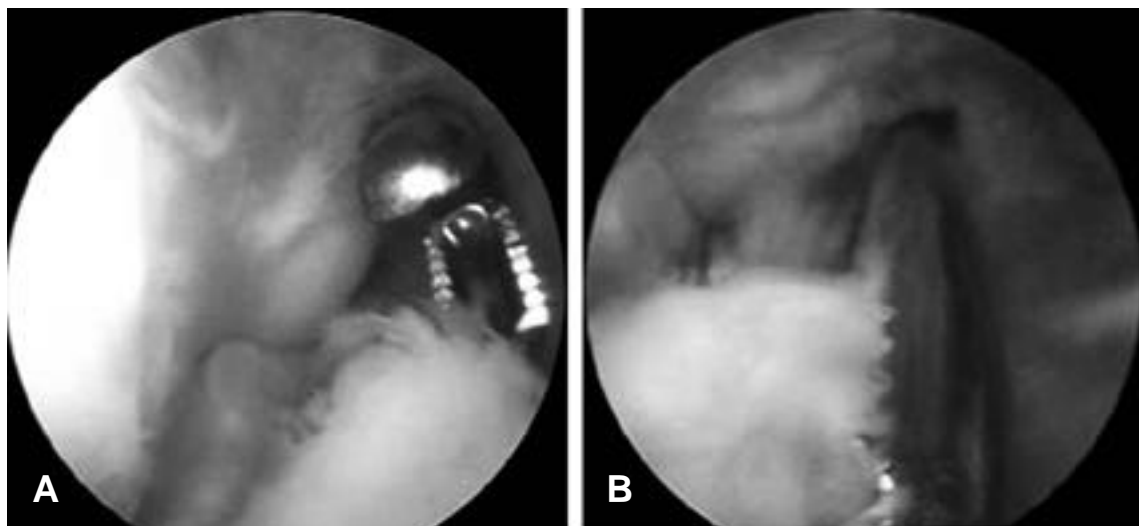


Fig. 1. (A) Arthroscopic synovectomy for release of contracture. (B) Arthroscopic capsulectomy for release of contracture.

(CPM) 가 , 가 6 가가 23 (57.5%), 18 (45%) 14 (45.2%) 7 (77.8%) 90 66.5 (, 45 ~ 85) 93.1 (, 80 ~ 100) 가 , 29 (72.5%), 8 (20%), 2 (5%), 1 (2.5%) 37 (92.5%) 가 (P< 0.05). 32.5 (, 5 ~ 55) 9.6 (, 0 ~ 30) inside-out 105 (, 65 ~ 132) 131.5 (, 100 ~ 145) 가 . 72.5 (, 5 ~ 132) 121.8 (, 0 ~ 145) 49.3 가 (Table 1, P<0.05). 가가 가 Severance Elbow Scoring System¹⁾ 37 (, 26 ~ 55), 28 (, 5 ~ 38) 가 Students 27.3 (, P-value 0.05 , 22 ~ 42) 가 18.2 (, 5 ~ 26) 가

Table 1. Final results

	Preoperation	Post operation	P-value
Elow Score	62.5 (35-85)	93.1 (80-100)	<0.05
Flexion contracture (°)	32.5 (5-55)	9.7 (0-30)	
Maximium flexion (°)	105 (65-132)	131.5 (100-145)	
Total range of motion (°)	72.5 (5-132)	121.8 (0-145)	<0.05

가 : 가 . 27 ,
 (P<0.05). 4 , 9
 , indomethacin 가 가 30

4,7,13,14) 30 , 30
 , 120 가 , Husband Glynn
 가 8) Niebauer⁴⁾ , Hastings⁷⁾
 13) , Urbaniak
 , Wilner¹⁴⁾

50% 80% Wilson¹⁵⁾
 8) 0 146 , Mor-
 rey ¹⁰⁾ 가 11,13)
 30 130 가 ,
 90%가 가 ,
 50 1,2)

가 26.5
 22.8 가 49.8
 30 , 45 가 가

가 100 가 가
 3) Mohan⁹⁾
 가 가
 20% , 가 가
 20% , - 38% ,
 10% 5,12)
 . Cooney³⁾ 가 가

Penlose drain

가
가 5 (12.5%)
3

(7.5%),

2 (5%) ,

가

REFERENCES

1) , , : , 34:1147-1152, 1999.
2) , , , : , 1:72-77, 1988.
3) **Cooney WP**: Contractures of the elbow: The elbow and its disorders, WB Saunders Co. Philadelphia, 2:464-475, 1993.
4) **Glynn JJ and Neibauer JJ**: Flexion and exten-

sion contractures of the elbow. *Clin Orthop*, 177:289-291, 1976.
5) **Haapaniemi T, Berggren M and Adolfsson L**: Complete transection of the median and radial nerves during arthroscopic release of post-traumatic elbow contracture. *Arthroscopy*, 15:784-787, 1999.
6) **Hertel R, Pisan M, Lambert S and Ballmer F**: Operative management of the stiff elbow. Sequential arthrolysis based on a transhumeral approach. *J Shoulder Elbow Surg*, 6:82-88, 1997.
7) **Husband JB and Hastings H 2nd**: The lateral approach for operative release of post-traumatic contracture of the elbow. *J Bone Joint Surg*, 72A:1353-1358, 1990.
8) **Jens OS**: The stiff elbow. How I do it. *Acta Orthop Scand*, 67:626-631, 1996.
9) **Mohan K**: Myositis ossificans of the elbow. *Int Surg*, 57:475-480, 1972.
10) **Morrey BF, Askew LJ and Chao EY**: A biomechanical study of normal functional elbow motion. *J Bone Joint Surg*, 63A:872-877, 1981.
11) **Morrey BF and An KN**: Articular and ligamentous contribution to the stability of the elbow joint. *Am J Sports Med*, 11:315-319, 1983.
12) **O'Driscoll SW and Morrey BF**: Arthroscopy of elbow; Diagnostic and therapeutic benefits and hazards. *J Bone Joint Surg*, 74A:84-94, 1992.
13) **Urbaniak JR, Hansen PE, Beissinger SF and Aitken MS**: Correction of post-traumatic flexion contracture of the elbow by anterior capsulotomy. *J Bone Joint Surg*, 67A:1160-1164, 1985.
14) **Wilner P**: Anterior capsulectomy for contractures of the elbow. *J Int Coll Surg*, 11:359-361, 1948.
15) **Wilson PD**: Capsulectomy for relief of flexion contractures of the elbow following fractures. *J Bone Joint Surg*, 26:71-86, 1944.