

# Posterior Interosseous Nerve(PIN) Syndrome Caused by Anomalous Vascular Leash

Tae Koo Cho, M.D., Jae Min Kim, M.D., Ph.D.,  
Koang Hum Bak, M.D., Ph.D., Choong Hyun Kim, M.D., Ph.D.

Department of Neurosurgery, Hanyang University Medical College, Guri Hospital, Guri, Korea

Posterior interosseous nerve(PIN) syndrome is an entrapment of the deep branch of the radial nerve just distal to the elbow joint. It is caused by acute trauma or masses compressing the nerve. We report an unusual case of PIN syndrome with wrist drop caused by compression of the nerve by anomalous vascular leash. The patient has recovered with the surgical decompression of the offending vessels and arcade of Frohse.

**KEY WORDS :** Vascular leash · Arcade of Frohse · Posterior interosseous nerve.

## Introduction

Entrapment or compression neuropathies are important and widespread debilitating clinical problems<sup>1)</sup>. Radial nerve palsy is less frequently occurred peripheral nerve disease on the upper extremities<sup>4)</sup>. Most commonly, it is caused by fractures at the midhumeral level<sup>4,5)</sup>. Posterior interosseous nerve(PIN) syndrome is an entrapment of the deep branch of the radial nerve just distal to the elbow joint. It may result in the paresis or paralysis of the fingers and thumb extensor muscles<sup>2,3)</sup>.

We present a case of PIN entrapment syndrome with wrist drop caused by the compression of the nerve by anomalous vascular leash and dense fibrous bands.

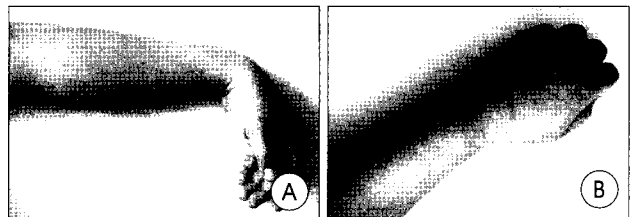
## Case Report

This 33-year-old man was presented with the complete left wrist drop. Six months earlier, he had experienced an acute aching pain on anterolateral surface of the left arm. After several days, he was unable to extend his wrist and all five fingers. The patient had no familial history of metabolic, chronic inflammatory, or allergopathic disorders.

On admission, the complete palsies of the extensor muscles of the left wrist and fingers were noted. The patient showed

the complete wrist drop and the flexor muscle power of the left wrist was Grade I. The patient was unable to expand his five fingers and the grasping power of the hand was Grade II (Fig. 1). The sensory of the left arm and hand were normal. Electromyography(EMG) revealed signs of abnormal spontaneous activity in the left extensor indicis, extensor carpi radialis, extensor carpi ulnaris, extensor digiti minimi, supinator, and brachioradialis muscles. Also, the decreased amplitude and delayed conduction velocity of the left radial nerve complex motor action potentials(APs) across the elbow were found.

Under general anesthesia, the patient underwent surgery 6 months after onset of symptoms. Skin incision was made about 10cm on radial side distally from elbow joint. The muscle dissection was carried in the layer by layer fashion until the appearance of the deep branch of the radial nerve. After identification of the PIN of the radial nerve between the brachioradialis and brachialis muscle bundles, we found multiple veins and adhesive bands laid across the radial nerve. We divided this offending vascular leash and adhesive bands with bipolar coagulator and silk-tying technique. After then,

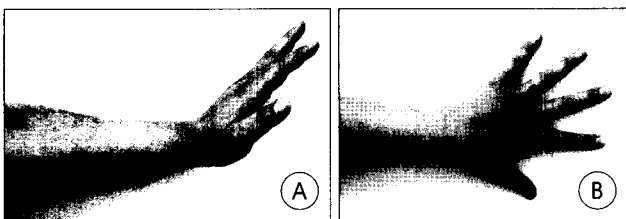


**Fig. 1.** Preoperative photographs of the posterior interosseous nerve syndrome patient. (A) The patient showing the complete wrist drop and the Grade I flexor muscle power of the left wrist. (B) The patient is unable to extend his five fingers (finger drop) and the grasping power of the hand showing the Grade II.

• Received : September 10, 2004 • Accepted : October 5, 2004  
• Address for reprints : Jae Min Kim, M.D., Ph.D., Department of Neurosurgery, Hanyang University Medical College, Guri Hospital, 249-1 Gyomun-dong, Guri 471-701, Korea  
Tel : 031)560-2323 Fax : 031)560-2327  
E-mail : kjm2323@hanyang.ac.kr



**Fig. 2.** Intraoperative photographs of the posterior interosseous nerve (PIN) syndrome patient. (A) Note the vascular leash and adhesive bands constricting the PIN across it at the just proximal to the arcade of Frohse. (B) The abnormal crossing veins which across the PIN are coagulated and tied. (C) After division of the vascular leash and bands, arcade of Frohse is excised widely for an adequate nerve decompression.



**Fig. 3.** Postoperative photographs of the posterior interosseous nerve syndrome patient. The left hand demonstrating a marked improvement of the dorsiflexion of the wrist (A) and the complete fanning of all fingers after 10 months follow-up period (B).

the arcade of Frohse was also divided widely for an adequate decompression (Fig. 2). Postoperatively, the patient's left arm and hand functions, especially the dorsiflexion of the wrist and fanning of five fingers, were improved to the nearly normal grade after 10 months follow-up period (Fig. 3). The follow-up EMG findings also showed the improvement of the left radial neuropathy around the elbow.

## Discussion

The most common peripheral entrapment or compression neuropathy is median nerve entrapment in the wrist which is so-called carpal tunnel syndrome<sup>1,7,9</sup>. Radial nerve entrapment is the least common occurring group of peripheral nerve neuropathies, and its most common cause is the fracture in the midhumeral level<sup>9</sup>.

The PIN, a deep branch of radial nerve, is most liable to entrapment just beyond its origin as it passes through the fibers of the supinator muscle in the upper forearm<sup>7,9</sup>. At this point, a fibrotendinous band from which some of these muscle fibers originate (arcade of Frohse) is frequently found<sup>3,10</sup>. Lipomas, ganglions, rheumatoid synovial overgrowth, and dislocations of the elbow may account for compression of the nerve at this site<sup>2,10</sup>. These are rare but include adhesions between the brachialis and brachioradialis muscles, and the edge of the extensor carpi radialis brevis, fibrous bands associated with the supinator muscle and a set

of vascular branches sometimes termed the "leash of Henry"<sup>11,6</sup>. An additional rare PIN entrapment occurs as the nerve exits the distal supinator<sup>1</sup>. In our case, the PIN was compressed by multiple anomalous vascular leash and the fibrous bands just above the arcade of Frohse site.

Entrapment of the PIN may be presented in one of two distinct

ways : as a painless palsy, sometimes preceded by transient extensor forearm aching, or as a painful condition that is often difficult to distinguish from lateral epicondylitis, usually called the radial tunnel syndrome<sup>7,10</sup>. With the typical pattern of paralysis, there is no wrist drop, because the extensor carpi radialis longus and brevis are supplied by the radial nerve proximal to its terminal branching. However, when the patient attempts to extend the wrist, the wrist deviates to radial side because of the paralysis of the extensor carpi ulnaris supplied by PIN<sup>2,3,6</sup>. The cardinal finding of the PIN syndrome is the inability to extend the metacarpophalangeal joints of the finger and thumb, usually called "finger drop"<sup>9</sup>. And also, extension of the thumb at the interphalangeal joint is not possible because of paralysis of the extensor pollicis longus<sup>7,10</sup>. Sensory disturbances are entirely absent<sup>1</sup>. However, the occurrence of complete wrist drop as in our case is very rare finding in PIN syndrome. The cause of the wrist drop is speculated that the branches to the extensor carpi radialis longus and brevis gives off just below the compression level or there is anatomical variation of PIN. Usually, the PIN gives off two long branches, a medial one to the extensor pollicis longus and extensor indicis, and a lateral one supplying the abductor pollicis longus and ending in the extensor pollicis brevis. In this study, there may be possibility of neural anastomosis between aforementioned two branches<sup>8</sup>. EMG shows the marked slowing of conduction and low amplitude across the lesion, which affects the severity and location of the deficit of the radial nerve APs<sup>2</sup>. This case also showed the decreased amplitude and delayed conduction velocity of the left radial nerve across the elbow.

Although a course of conservative therapy including rest, modification of behavior, non-steroidal medications, and sometimes steroid injection is indicated initially for treatment of this syndrome, many patients eventually require an operation<sup>1</sup>. Surgical therapy, in refractory cases that do not improve after 4 to 8 weeks of conservative therapy, consists of exploring the PIN and dividing the arcade of Frohse and

any other constricting bands<sup>6,7</sup>). Daniel et al. reported an overall Grade III or better functional recovery in 35 cases (94.7%) among a total 37 cases, which had been encountered over 30 years period<sup>5</sup>). In our case, the patient have already spent 6 months after the occurrence of the wrist and finger drops. He showed an excellent functional outcome after 10 months follow-up period with division of the arcade of Frohse widely and decompression of the vascular leash completely.

## Conclusion

**W**e present a rare case of the PIN syndrome with complete wrist drop, which was caused by anomalous vascular leash and fibrous bands. The patient showed a good recovery after decompression of the offending vessels and wide spread division of the arcade of Frohse. The PIN syndrome should be considered in a case of spontaneous occurrence of the wrist drop.

## References

1. Arle JE, Zager EL : Surgical treatment of common entrapment neuropathies in the upper limbs. **Muscle Nerve** 23 : 1160-1174, 2000
2. Chien AJ, Jamadar DA, Jacobson JA, Hayes CW, Louis DS : Sonography and MR imaging of posterior interosseous nerve syndrome with surgical correlation. **AJR Am J Roentgenol** 181 : 219-221, 2003
3. Erdem S, Demirci M, Tan E : Focal myopathy mimicking posterior interosseous nerve syndrome. **Muscle Nerve** 24 : 969-972, 2001
4. Fernandez E, Di Rienzo A, Marchese E, Massimi L, Lauretti L, Pallini R : Radial nerve palsy caused by spontaneously occurring nerve torsion : case report. **J Neurosurg** 94 : 627-629, 2001
5. Kim DH, Kam AC, Chandika P, Tiel RL, Kline DG : Surgical management and outcome in patients with radial nerve lesions. **J Neurosurg** 95 : 573-583, 2001
6. Kim JM, Choi JY : Posterior interosseous nerve syndrome. **J Korean Neurosurg Soc** 21 : 311-314, 1992
7. Lee CC, Tindall SC, Kliot M : Entrapment syndromes of peripheral nerve injuries in Winn HR(ed) : Youmans Neurological Surgery, ed 5. **Philadelphia** : Saunders, 2004, Vol 4, pp3921-3939
8. Missankov AA, Sehgal AK, Mennen U : Variation of the posterior interosseous nerve. **J Hand Surg** 25 : 281-282, 2000
9. Rengachary SS : Entrapment neuropathies in Wilkins RH, Rengachary SS(eds) : **Neurosurgery**, ed 2. New York : McGraw-Hill, 1996, Vol 3, pp3073-3098
10. Rosenbaum R : Disputed radial tunnel syndrome. **Muscle Nerve** 22 : 960-967, 1999