

The Effect of Recombinant Tissue Plasminogen Activator on the Intracerebral Hematomas in Experimental Cat Models

Kwang-Wook Jo, M.D., Seong-Rim Kim, M.D., Seung-Hoon You, M.D., Sang-Don Kim, M.D., Ik-Seong Park, M.D., Min-Woo Baik, M.D.

Department of Neurosurgery, Holy Family Hospital, The Catholic University of Korea, Bucheon, Korea

Objective : Recent clinical studies have demonstrated that intracisternal administration of recombinant tissue plasminogen activator(rt-PA) can facilitate the normal clearing of blood from the subarachnoid space. Urokinase, a first generation fibrinolytic agent, has been used to liquify such clots with some success. Therefore, recombinant tissue plasminogen activator, a second generation fibrinolytic drug that may be safer and more effective, is studied to evaluate its dosage to lyse clots in vitro and reactivity in the brain parenchyme.

Methods : Intracerebral hematomas were created by stereotactically injecting 2ml of clotted autogenous blood into the brain parenchyme of total 28 anesthetized adult cats (weighting 3.8 to 4.1kg). The control animals (group A) received 1ml of normal saline injected into the clots and the experimental animals received each 0.1mg of rt-PA (group B), 0.5mg of rt-PA (group C) and 1mg of rt-PA (group D) at 6 hours after the clot injection.

Results : 1. The amount of remained clots after lysing the hematomas were as follows : 1.80 ± 0.17 ml in group A, 1.65 ± 0.23 ml in group B, 0.61 ± 0.37 ml in group C and 0.52 ± 0.34 in group D. The result indicated that hematomas in rt-PA treated groups (C & D) were lysed better than the control group. 2. At least 0.5mg of rt-PA should be required for the lysis of 2ml of hematomas. 3. Light microscopic examination revealed no histological evidence of hemorrhage in tissue sections from each brain.

Conclusion : Recombinant tissue plasminogen activator may be safely and effectively employed for the lysis of intracerebral hematomas in animal model.

KEY WORDS : Recombinant tissue plasminogen · Activator(rt-PA) · Intracerebral hematoma · Cat.

Introduction

Treatment of spontaneous intracranial hemorrhage is currently controversial despite the introduction of newer neurosurgical equipment and techniques. It still carries a high morbidity and mortality with or without surgical treatment. The aim of surgical treatment is to prevent secondary injury to the brain by evacuating the hematoma as soon as possible⁷⁾.

Stereotactic hematoma removal²⁾, with or without CT-guidance, was introduced in order to prevent normal brain tissue in the process^{1,4,12,14,19)}. Intraoperative urokinase injection has been used to liquefy the hematoma contents²⁶⁾.

Urokinase, a first generation thrombolytic agent, has an undesirable fibrinogenolytic action. In contrast, recombinant

tissue plasminogen activator(rt-PA), a second generation thrombolytic agent, is similarly effective but with selective fibrinolytic activity^{11,16)}. Substitution of rt-PA in place of Urokinase has resulted in improved outcomes in the treatment of acute myocardial infarction, acute cerebral infarction and SAH^{9,10,27)}.

In 1987, Kaufman et al. reported experimental use of rt-PA in intracerebral heamorrhage but with no clinical studies to corroborate.

The problems of using urokinase are increased incidence of ICH and, infections, and the need for recurrent injections. A review of Korean literature on the subject revealed one case report where heparin and urokinase were used in cerebral venous thrombosis⁵⁾. While rt-PA has previously been used intravenously, the current report evaluates that use of rt-PA for intracerebral thrombolysis. We attempted to find a minimum dose of rt-PA to liquefy a specific amount of hematoma in an experiment. We then looked for safety of rt-PA by comparing numerical data and histopathologic analysis.

• Received : September 7, 2004 • Accepted : October 27, 2004
 • Address for reprints : Ik-Seong Park, M.D., Department of Neurosurgery, Holy Family Hospital, The Catholic University of Korea, 2 Sosa-dong, Wonmi-gu, Bucheon 422-052, Korea
 Tel : 032) 340-2040, Fax : 032) 340-2672
 E-mail : NSpark@chollian.net

Table 1. Neurological grading chart

Function	Grading			
	I	II	III	IV
Consciousness	Alert	Lethargic	Stuporous	Coma
Gross motor strength	Normal strength	Evident weakness	Perceptible movement only	Plegic
Standing and gait	Normal gait	Stands with difficulty	Sit, can not stand	Unable to sit
Swallowing and feeding ability	Eats normally	Bends to eat directly from dish	Swallows liquids placed in mouth	No allowing

Materials and Methods

In this experiment, 28 cats weighing between 3.8 - 4.1 kg were used irrespective of sex and rt-PA (Actylase, Boeringer Ingelheim, Germany) were used.

Experimental Methods

In vitro experiment

Blood was extracted after incising the cat's jugular vein. Thrombolytic agent was not applied to this blood and it was left at room temperature. If this blood organized into a hematoma, it was broken down to little pieces and squeezed into a 10cc syringe. Extraction of bubbles in a syringe was done by smacking a syringe^{23,24}. A total of 30 syringes each with 2cc hematoma were extracted, out of which 5 served as controls. Six hours following blood extraction, 4cc of normal saline was mixed with the control group. RT-PA 0.1mg+ normal saline 4cc was mixed in the first group, rt-PA 0.5mg+ normal saline 4cc mixed in the second group, rt-PA 1mg+ normal saline 4cc mixed in the third group, rt-PA 2mg+ normal saline 4cc mixed in fourth group, and rt-PA 4mg+ normal saline 4cc was mixed in the fifth group.

These syringes were left at room temperature for 24hours and shaken every 2hours to mix rt-PA with the hematoma. After 24 hours, the syringes were soaked in a water tank to wash out the dissolved hematoma. The residual hematoma volume was measured to evaluate the extent of its liquefaction.

In vivo experiment

Cats were intubated after intramuscular injection of 1mg/kg ketamine. They were hyperventilated using a ventilator (R-60, Aika, Japan) to achieve a PaCO₂ of 25~35mmHg, with a PaO₂ 90~110mmHg and a pH of 7.4 on ABGA. Intravenous mannitol (1cc/kg) was used to minimize the ICP elevation resulting from hematoma injection. Right femoral artery and vein were exposed to measure BP, ABGA, and for venous sampling. Hematomas were created as mentioned before in

the in vitro experiments.

The head of the experimental animal was fixed in a prone and head up position using stereotactic instruments (Stoeling Co. U.S.A.). Both frontal and parietal lobes were exposed after a midline skin incision, and a microdrill was used to make 2mm burr hole at 10mm right and 5mm posterior to the coronal suture.

the in vitro experiments.

Intracerebral hematomas were created by injecting 2cc of autologous venous hematoma at right side of the exposed brain through a catheter. 0.2cc normal saline was injected through a catheter to push the hematoma remaining in catheter. This was followed by catheter closure and scalp suture. After 6 hours, the cats were divided into 4 groups (7 cats each). Using a catheter, 1cc normal saline was injected to brain parenchyme in the control group (A). In a similar fashion, different dosages of rt-PA were mixed with 1cc normal saline and injected through a catheter for 5min (rt-PA 0.1mg on experimental B group, rt-PA 0.5mg on C group, rt-PA 1mg on D group).

Observation data

Clinical status

Neurological status was recorded 2hours after the injection and 1hour prior to sacrificing the animal by using a Neurological Grading Chart²⁴. In addition to that, degree of bleeding of skin incision site and femoral puncture site was observed.

Sacrificing the experimental animal

Twenty four hours after injecting normal saline or rt-PA in experimental and control group, ketamine was injected intramuscularly. Both jugular artery and vein were exposed, followed by venesection and insertion of an A-line. About 1.5 ~2L of water was used to wash out all the blood in the animal's body. Paraformaldehyde solution (4%; 100ml) was injected through the catheter, and then both the jugular vein were closed for 2hours. After separating the skull from the brain, 2mm slices of brain were made to evaluate the size, shape, and location of hematoma.

Liquefaction status of hematoma

Liquefied hematoma was melt out during coronal section of brain. Undissolved remained hematoma was collected and put into test tube for the measure of amount. For the removal of

Table 2. Effect of rt-PA on in vitro clot lysis

	Number	Addition	Volume of remained clot
Control group			
	5	saline 4ml	1.86 ± 0.12ml
Experimental group			
Group 1	5	rt-PA 0.1mg	1.63 ± 0.32ml * +
Group 2	5	rt-PA 0.5mg	0.91 ± 0.47ml * +
Group 3	5	rt-PA 1mg	0.73 ± 0.36ml * +
Group 4	5	rt-PA 2mg	0.75 ± 0.21ml * +
Group 5	5	rt-PA 4mg	0.67 ± 0.38ml * +

* P<0.05 compared with saline treated group, +P<0.05 compared with rt-PA 0.1mg treated group

Table 3. Effect of rt-PA on in vivo clot lysis

	Number of animal	Treated solution	Remained clot
Group A	7	saline	1.08 ± 0.17ml
Group B	7	rt-PA 0.1mg	1.65 ± 0.23ml
Group C	7	rt-PA 0.5mg	0.61 ± 0.37ml +
Group D	7	rt-PA 1mg	0.52 ± 0.34ml +

+ P<0.05 compared with saline treated group

observation error, the solid clot was liquefied by adding rt-PA until it dissolved. Using a micropipette, the volume of residual hematoma was calculated excluding the volume of rt-PA.

Histopathologic status

Every slice of brain excluding hematoma was soaked in 10% formaldehyde solution for 24 hours. Hematoxylin & Eosin staining was done and intracerebral abnormalities were recorded to evaluate the effect of rt-PA on brain.

Statistical analysis

Each variable was noted as mean ± SD. Unpaired T-test was used and a probability value of <0.05 was considered statistically significant. Statistical significance data was generated by the repeated measures ANOVA test by SAS then confirmed with Scheff's test.

Results

In vitro experiment

In the control group, the residual hematoma was 1.86 ± 0.12 ml. In the first group, the residual hematoma was 1.63 ± 0.32 ml, in the second group 0.91 ± 0.47ml, in the third group 0.73 ± 0.36ml, in the fourth group 0.75 ± 0.21ml and in the fifth group 0.67 ± 0.38ml. The amount of residual hematoma in the control group was 1.87 ± 0.11ml and in five groups of rt-PA was 0.9 ± 0.34ml. There were significant differences between control and rt-PA groups except the first rt-PA group (P<0.05, Table 2).

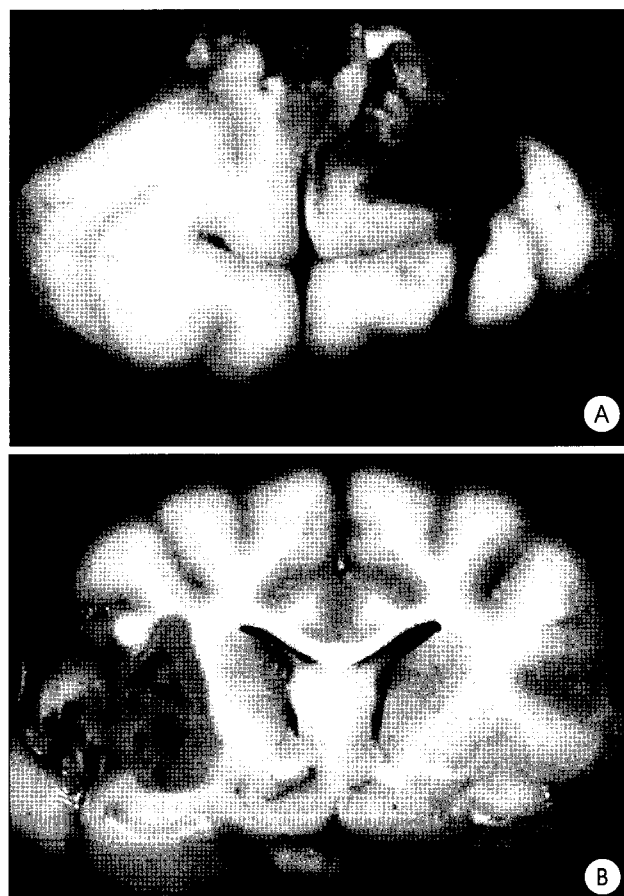

Fig. 1. A : Coronal slices show remained clots in the saline treated group. B : There are a few clots of recombinant tissue plasminogen activator treated group.

There were significant differences in the degrees of liquefaction between 2th, 3rd, 4th, 5th and 1st group (P<0.05, Table 2). The minimum amount of rt-PA to dissolve 2cc of hematoma was 0.5mg and there were no differences above that dosage of rt-PA.

In vivo experiment

Clinical status

After injecting the rt-PA or normal saline, there were 3 animals in grade I, 22 in grade II, 3 in grade III. No other difference between control and experimental groups were noted. Prior to sacrificing animals, 2 animals had already died, 3 were in grade III and 23 in grade II. There were no significant differences in the volumes of hematoma in control and experimental groups. There were no signs of abnormal bleeding in any of these animals.

Liquefaction status of hematoma

In the control group (group A), the residual hematoma was 1.80 ± 0.17ml, in the experimental groups, group B (0.1mg rt-

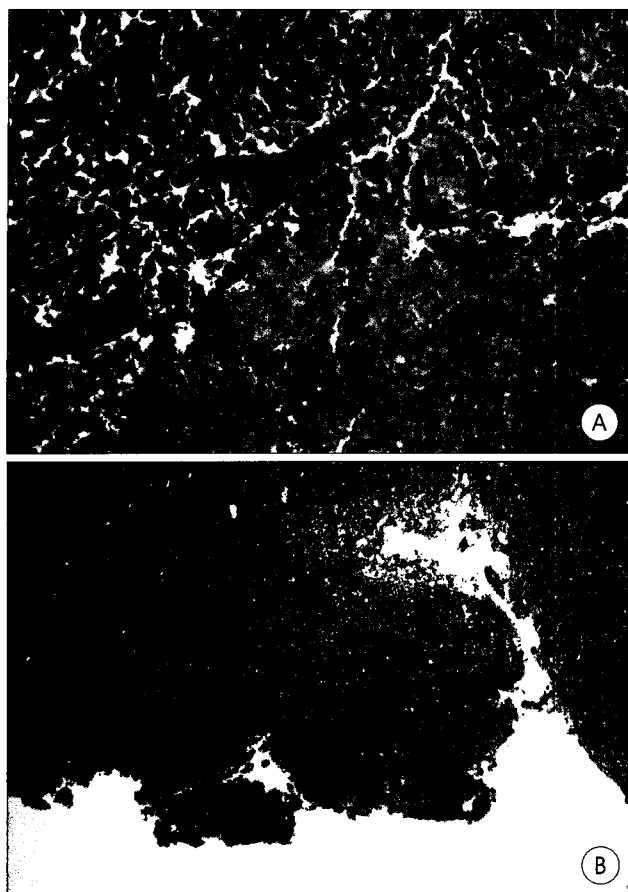


Fig. 2. Histological sections through the cerebro-hematoma interface A : control animal. Note the large persistent intraparenchymal hematoma. (H&E×100) B : recombinant tissue plasminogen activator treated animal. Note the absence of an intraparenchymal clot and normal appearance of parenchyma. (H&E×50).

PA) was 1.65 ± 0.23 ml, group C (0.5 mg rt-PA) was 0.61 ± 0.37 ml, group D (1 mg rt-PA) was 0.52 ± 0.34 ml. There were no significant differences between the control (group A) and the experimental group B but there were significant differences ($P < 0.05$) between the control group and groups C & D. There were no significant differences between groups C and D (Table 3). Gross and microscopic pathologies were evaluated in 26 out of 28 animals. There were no signs of intracerebral bleeding and no significant findings except inflammatory cell infiltration (Fig. 1, 2).

Discussion

Spontaneous intracerebral hemorrhage is a major contributor to intracranial vascular disease and results in the need for intensive care for a majority of such cases. The primary injury to the brain in such instances is via pressure and shifting effects. The secondary brain injury is caused by the destructive effects of the melted hematoma. Cerebral

edema, hydrocephalus and vasodilation increase the brain volume, thereby aggravating the pressure effect on normal brain tissue. If not managed in time, increasing intracranial pressure results in brain herniation. The focus of recent treatment regimens in intracerebral hemorrhage has been on attempts to reduce the volume of intracranial contents⁷. The effect of surgical removal of the intracerebral hematoma itself has been controversial. Various authors have noted the different aspects of indication, timing and techniques of surgery as well as the role of medical treatment in such instances¹⁴. Most reports have posted a post-surgical morbidity of 20~80% (upto 90% in comatose patients or patient with thalamic hemorrhage)^{18,20,22,28}. It is clinically risky to operate on a patient with intracerebral hemorrhage even with the available technical refinements. From this point of view, safer surgical method of evacuation of intracerebral hemorrhage has been advocated by minimizing the damage to the normal brain tissue.

The stereotactic catheter insertion to intracerebral hemorrhage was first tried by Benes³ et al but, it was not tested clinically. Since almost 80% of the immediate intracerebral hematomas are solid¹⁴, it has been difficult to suction them out. There have been reports using Archimedes screw to remove intracerebral hemorrhage by Backlund and von Holst². Broseta et al tried this technique in 16 patients in whom initial GCS was very low but morbidity was high. Soon after that, better outcomes were reported using CT-guided stereotactic techniques^{13,14,17}. Niizuma et al used Urokinase, a thrombolytic agent, to remove the residual hematomas²¹. The limitations of this study include the difficulty in evaluating the clinical effects following the evacuation of the hematoma. However, the amount of rt-PA required to dissolve the hematoma and the effects of rt-PA on intracerebral hematoma can be quantitated.

There is enough plasminogen to dissolve the hematoma in spontaneous intracerebral hematomas²³. But it resides as unactivated form. Unactivated plasminogen is attached to fibrin in hematoma. Activation of plasminogen by plasminogen activator results in dissolution of the hematoma. Plasminogen activators like Urokinase and streptokinase have been used as thrombolytic agents. It takes a long time to dissolve the hematoma in nature, but this process is speeded up by using a thrombolytic agent.

Conventionally, hematomas are evacuated using urokinase for 3 to 4 days via a silastic intracerebral catheter in intracerebral hemorrhage patients using stereotactic surgery⁶.

Recent studies have tried very high doses of thrombolytic agents because the infection rates increase as silastic catheter

remains in intracranial hematoma for long time. However, these high doses of thrombolytic agents have added risk of hemorrhage. Intracatheter use of rt-PA does not influence the formation of coagulation factors by contacting the hematoma directly resulting in a lower risk of bleeding. In this experiment, we tried to overcome the problems of other thrombolytic agents, since intravenous use of rt-PA has been safe and effective. In all the experimental animals, there was no case of intracerebral hemorrhage and no significant pathologic findings except infiltration of inflammatory cells. The purpose of this study was to find out the minimum dosage of rt-PA to dissolve the hematoma. Further studies about the risks of bleeding and pathologic changes from the high dose, short time rt-PA treatment in intracerebral hemorrhage may be helpful.

In one report by Matsumoto¹⁹⁾, evacuating a solid hematoma required approximately 70cmHg negative pressure but the dissolved hematoma required only 20~40cmHg negative pressure. They injected urokinase in 48 patients to dissolve intracerebral hematoma prior to evacuation. Using CT-guided stereotactic technique, an intracerebral silastic catheter was placed in hematoma and intracatheter urokinase 6000IU was injected every 6 to 12hours while clamping the catheter in between. Intracatheter urokinase was injected repeatedly until hematoma was resolved on follow up CT.

The advantages of this technique compared to the traditional craniotomy include the ease of procedure and the ability to perform it under local anesthesia. Also, a complete evacuation of hematoma is possible by intracatheter injection of urokinase. For these reasons, they assert this technique is appropriate treatment for old ages and high risk groups.

Since we could not find any published reports on the effects of rt-PA in comparison to the dosages of urokinase to dissolve the hematoma²⁵⁾, we perform in vitro experiment to find out minimum dosage of rt-PA to achieve hematoma liquefaction. We assumed equal amounts of plasminogen in each hematoma, since the venesection time was short. To evaluate the effects of rt-PA, minimum dosage of rt-PA to dissolve 1cc of hematoma was calculated. In vitro experiments by Kaufman¹⁵⁾, there were no differences in the rt-PA dosage dissolving a given volume of hematoma. In the present study, there were no differences among doses at or above 0.5mg rt-PA in dissolving certain amount of hematoma in vivo and in vitro experiments. This is because of the high dose of rt-PA used to completely resolve the hematoma.

However, the amount of rt-PA required to dissolve the hematoma would differ if larger volumes of hematomas are treated. In a report by Findlay⁸⁾, the minimum dosage of rt-PA

required to dissolve the hematoma was calculated by injecting different dosages of rt-PA after injecting 5ml of hematoma to induce subarachnoid hemorrhages in monkeys. After sacrificing the monkeys, residual hematoma in subarachnoid space was recorded. They reported the minimum dosage of rt-PA to dissolve the hematoma as 0.75mg. Compared to that, In vitro experiment, the hematoma was isolated in brain tissue from CSF and in vivo experiment showed 0.5mg rt-PA per every 2cc hematoma has effectiveness in resolution of hematoma.

rt-PA, a thrombolytic substitute for urokinase, has been in the spotlight in the recent treatment of cerebral infarction and coronary artery infarction. In the present study, we used rt-PA to evaluate its effect on the liquefaction of intracerebral hematoma. Previous studies by Kaufman¹⁵⁾ did not obtain numerical value of rt-PA dosage to dissolve the hematoma. In contrast, we were able to obtain the exact doses of rt-PA for possible clinical use. Since no experiment was done to compare urokinase and rt-PA, it may be necessary to confirm the safety of clinical use of rt-PA.

Conclusion

The object of this study is to find out safety and effectiveness of intracatheter use of rt-PA in stereotactic surgery. We calculated the minimum dosage of rt-PA to dissolve a certain amount of hematoma during in vitro experiments. Subsequently, we observed the gross and microscopic pathology in vivo after injecting varying amounts of rt-PA in 28 cats with 2cc volume of autologous intracerebral hematoma. We concluded that : 1. The minimum amount of rt-PA to dissolve 2cc of intracerebral hematoma was 0.5mg. 2. There were no signs of intracerebral bleeding and no significant findings caused by rt-PA, except inflammatory cell infiltration.

rt-PA was considered to be safe and effective in achieving the liquefaction of intracerebral hematomas in vivo.

References

1. Acampora S, Profeta G, Troisi F : Stereotaxic evacuation of hematomas - letter to the editor. *J Neurosurg* **62** : 460, 1985
2. Backlund EO, von Holst H : Controlled subtotal evacuation of intracerebral hematomas by stereotactic technique. *Surg Neurol* **9** : 99-101, 1978
3. Benes V, Vladyka V, Zverina E : Stereotaxic evacuation of typical brain hemorrhage. *Acta Neurochir* **13** : 419-426, 1965
4. Broseta J, Gonzalez-Darder J, Barcia-Salorio JL : Stereotactic evacuation of intracerebral hematomas. *Appl Neurophysiol* **45** : 443-448, 1982
5. Cho KS, Huh PW, Kwon SO, Park JH, Yang JH, Yoo DS, et al : Deep Cerebral Venous Thrombosis : Successful Treatment by Systemic Urokinase Followed by Heparin. *J Korean Neurosurg Soc* **30** : 99-104, 2001
6. Doi E, Morikawi H, Komai N : Stereotactic evacuation of intracerebral

- gematomas. **J Neurol Med Chir** 22 : 461-467, 1982
7. Dringer MN : Intracerebral hemorrhage : Pathophysiology and management. **Critical Care Medicine** 21 : 1591-1603, 1993
 8. Findlay JM, Weir BKA, Kanamaru K, Grace M, Gordon P, Baughman R, et al : Intrathecal fibrinolytic therapy after subarachnoid hemorrhage : Dosage study in a primate model. **Can J Neurol Sci** 16 : 28-40, 1989
 9. Findlay JM, Weir BKA, Kassell NF, Disney LB, Grace MG : Intracisternal recombinant tissue plasminogen activator after aneurysmal subarachnoid hemorrhage. **J Neurosurg** 75 : 181-188, 1991
 10. Findlay JM, Weir BKA, Stollery DE : Lysis of intraventricular hematoma with tissue plasminogen activator. **J Neurosurg** 74 : 803-807, 1991
 11. Goldsmith MF : Recombinant plasminogen agent continues to show promise in trials. **JAMA** 253 : 1693-1694, 1985
 12. Higgins AC, Nashild BJ : Modification of instrument for stereotactic evacuation of intracerebral hematoma. **Neurosurgery** 7 : 604-605, 1980
 13. Ito H, Muka H, Kitamura A : Stereotactic aqua stream and aspirator for removal of intracerebral hematoma. **Stereotact Funct Neurosurg** : 54-55, 457-460, 1990
 14. Kandel EI, Peresedov VV : Stereotactic evacuation of spontaneous intracerebral hematomas. **J Neurosurgery** 62 : 206-213, 1985
 15. Kaufman HH, Schochet S, Koss W, Herschberger T, Bernstein D : Efficacy and safety of tissue plasminogen activator. **Neurosurgery** 20 : 403-407, 1987
 16. Laffel GL, Braunwald E : Thrombolytic therapy : A new strategy for the treatment of acute myocardial infarction. **N Engl J Med** 311 : 770-776, 1984
 17. Liu ZH, Kang GQ, Chen XH : Evacuation of hypertensive intracerebral hematoma by a stereotactic technique. **Stereotact Funct Neurosurg** 54-55 : 451-452, 1990
 18. Luessenhop AJ, Shevlin WA, Ferrero AA : Surgical management of primary intracerebral hemorrhage. **J Neurosurg** 27 : 419-427, 1967
 19. Matsumoto K, Hondo H : CT-guided stereotactic evacuation of hypertensive intracerebral hematomas. **J Neurosurg** 61 : 440-448, 1984
 20. McKissock W, Richardson A, Taylor J : Primary intracerebral hemorrhage : A controlled trial of surgical and conservative treatment in 180 unselected cases. **Lancet** 2 : 221-226, 1961
 21. Niizuma H, Shimizu Y, Yonemitsu T : Results of stereotactic aspiration in 175 cases of putaminal hemorrhage. **Neurosurgery** 24 : 814-819, 1989
 22. Paillas JE, Alliez B : Surgical treatment of spontaneous intracerebral hemorrhage. Immediate and long-term results in 250 cases. **J Neurosurg** 39 : 145-151, 1973
 23. Pang D, Sclabassi RJ, Horton JA : Lysis of intraventricular blood clot with Urokinase in a canine model : Part 1. Canine intraventricular blood cast model. **Neurosurgery** 19 : 540-546, 1986
 24. Pang D, Sclabassi RJ, Horton JA : Lysis of intraventricular blood clot with Urokinase in a canine model : Part 2. In vivo safety study of intraventricular urokinase. **Neurosurgery** 19 : 547-552, 1986
 25. Pang D, Sclabassi RJ, Horton JA : Lysis of intraventricular blood clot with Urokinase in a canine model : Part 3. Effect of intraventricular urokinase in clot lysis and posthemorrhagic hydrocephalus. **Neurosurgery** 19 : 553-572, 1986
 26. Shen PH, Matsuoka Y, Kawajiri K, Kanai M, Hoda K, Yamamoto S : Treatment of Intraventricular Hemorrhage Using Urokinase. **Neurol Med Chir** 30 : 329-333, 1990
 27. Stolke M, Seifert V : Single intracisternal bolus of recombinant tissue plasminogen activator in patients with aneurysmal subarachnoid hemorrhage : Preliminary assessment of efficacy and safety in an open clinical study. **Neurosurgery** 30 : 877-881, 1992
 28. Weisberg LA : Computerized tomography in intracranial hemorrhage. **Arch Neurol** 36 : 422-426, 1979