

# The Influence of Fixation Rigidity on Intervertebral Joints - An Experimental Comparison between a Rigid and a Flexible System

Won Joong Kim, M.D., Ph.D.,<sup>1</sup> Sang-Ho Lee, M.D., Ph.D.,<sup>2</sup> Song-Woo, Shin, Ph.D.,<sup>2</sup>  
Charles H. Rivard, M.D.,<sup>3</sup> Christine Coillard, M.D.,<sup>3</sup> Souad Rhalmi, M.Sc.<sup>3</sup>

Departments of Orthopedic Surgery,<sup>1</sup> Neurosurgery,<sup>2</sup> Wooridul Spine Hospital, Seoul, Korea  
Department of Neurosurgery,<sup>3</sup> Research Center, St. Justine Hospital, Montreal, Canada

**Objective :** Spinal instrumentation without fusion often fails due to biological failure of intervertebral joints (spontaneous fusion, degeneration, etc). The purpose of this study is to investigate the influence of fixation rigidity on viability of intervertebral joints.

**Methods :** Twenty pigs in growing period were subjected to posterior segmental fixation. Twelve were fixed with a rigid fixation system (RF) while eight were fixed with a flexible unconstrained implant (FF). At the time of the surgery, a scoliosis was created to monitor fixation adequacy. The pigs were subjected to periodic radiological examinations and 12 pigs (six in RF, six in FF) were euthanized at 12-18 months postoperatively for analysis.

**Results :** The initial scoliotic curve was reduced from  $31 \pm 5^\circ$  to  $27 \pm 8^\circ$  in RF group ( $p=0.37$ ) and from  $19 \pm 4^\circ$  to  $17 \pm 5^\circ$  in FF group ( $p=0.21$ ). Although severe disc degeneration and spontaneous fusion of facet joints were observed in RF group, disc heights of FF group were well maintained without major signs of degeneration.

**Conclusion :** The viability of the intervertebral joints depends on motion spinal fixation. Systems allowing intervertebral micromotion may preserve the viability of intervertebral discs and the facet joint articular cartilages while maintaining a reasonably stable fixation.

**KEY WORDS :** Intervertebral joint viability · Spinal instrumentation · Fixation rigidity.

## Introduction

Though it is more common to fuse the entire instrumented section, spinal implants sometimes have to span over one or more unfused functional spinal units when they are used as internal splints in attempted preservation of motion segments<sup>3,4,13</sup>. However, this approach without or limited extent fusion, incorporating unfused segments within the instrumented section, often fails to achieve the desired goals of maintaining correction and saving the motion segments at the same time due to mechanical fixation failures and/or biological failures of the incorporated intervertebral joints<sup>5,8,14</sup>.

Mechanical and biological failures in instrumentation without fusion, though seemingly different, actually arise from the same problem of fixation rigidity. To fulfill the goal of the surgery, the internal splint must be rigid enough to hold the

correction at the same time be supple enough to allow motion to support the nutrition of the avascular tissues (articular cartilage, nucleus pulposus) in the incorporated joints and sometimes, growth of the incorporated vertebrae.

Biomechanically, the rigidity of the fixation offered by a spinal implant construct may be determined by several different factors; the anchoring member that forms the implant-bone interface, the longitudinal member that spans the anchoring members, the connecting mechanism (implant-implant interface) and the cross link that connects the longitudinal members on each side<sup>1</sup>. The authors postulated that by modification in each of these parameters governing the fixation rigidity, it might be possible to create a supple instrumentation system that would prevent the biological deterioration of the intervertebral joints while offering a holding power sufficient to achieve the goal of the internal splint.

This experimental study was performed to evaluate authors' hypothesis of preserving the viability of the intervertebral joints by allowing intervertebral micromotion by determining the effect of the rigidity of immobilization on the biological changes in the intervertebral joints incorporated within the instrumentation section.

• Received : September 2, 2004 • Accepted : October 29, 2004  
• Address for reprints : Won Joong Kim, M.D., Ph.D. Department of Orthopedic Surgery, Wooridul Spine Hospital, 47-4 Cheongdam-dong, Gangnam-gu, Seoul 135-100, Korea  
Tel : 02)513-8016, Fax : 02)513-8146  
E-mail : frangiewjk@hotmail.com

## Materials and Methods

**T**wenty Yucatan mini pigs in their actively growing period (age : 5.5~6.5months; weight : 23~42kg) were subjected to posterior segmental fixation using pedicle screw-rod systems. Twelve were fixed with a rigid fixation system (Rigid fixation group; RF) that does not allow any motion between the screws and the longitudinal member using Colorado in 11 and TSRH in 1 (Sofamordanek, USA.). Eight were fixed with a flexible unconstrained implant (Flexible fixation group; FF) that allowed intervertebral micromotion by combination of flexible rod that permits 15% deformation and a connecting mechanism that permits 6degree of freedom of motion between the screws and the longitudinal member (Orthobiom : Biorthex, Canada).

The surgery consisted of general endotracheal anesthesia, posterior midline incision, exposure of the vertebral column via submuscular approach without disturbing the periosteal tube and pedicle screw instrumentation spanning nine levels from T10 to L5 using eight pedicle screws and two bent rods to create a scoliosis. Creation of scoliosis had two purposes; as a means of monitoring the adequacy of the spinal fixation offered by the implant and to simulate a scoliosis patient. As the scoliosis was created by 90° anti-clockwise rotation of the contoured rods, five screws were placed on the left side and three on the right side. All the screws were placed under intraoperative radiological guidance.

Following the connection of the screws to the contoured rod, the rods were rotated to create a scoliosis and then locked in position by tightening the connecting members. In the FF, one screw on each side, placed at the same vertebral level, was tightly locked onto the rod using a fixed chariot to control the rod while rest of the screws was connected via a mobile chariot. Neither posterior intraarticular nor extraarticular arthrodesis was attempted.

The pigs were allowed to ambulate in the rooms after the recovery from the anesthesia. They were subjected to 14" x 17" anteroposterior and lateral spinal radiological examinations under general anesthesia immediately following the operation and under intravenous anesthesia at two weeks, two months, six months after the surgery and every six months thereafter. The scoliosis angle was measured on the anteroposterior radiographs by the Cobb method, using the same reference vertebrae that were used for the measurement of the deformity on the immediate postoperative radiographs. The length of the vertebral column in the instrumented section was measured by the string method, placing a string over the dots marked in the center of the vertebrae<sup>2</sup>. The upper and lower ends were

defined by the lines parallel to the endplates tangent to the uppermost and the lowermost screws or clamps. Since the length of the rod is not subject to the change, the rod length was used to correct the magnification for the measurement of the lengths. The first author did all the measurements.

They were euthanized between 12 and 18 months after the surgery and specimens were harvested for radiological, gross pathologic and histological examinations. The variation of the observation period in the FF sacrificing two animals at 12 months was to determine the adequacy of the micromotion and to see if there was any need to change the design of the instruments. Anteroposterior and lateral x-rays, and computed tomography(CT) scans were taken to evaluate the status of the posterior joints. The gross examinations were consisted of evaluation of the fixation quality of the implants in the retrieved specimen, manual bending test after removal of the implants, testing the disc space patency by needle probing into the disc spaces and direct examination of the intervertebral disc by dissection of the disc spaces with a scalpel for the incorporated segments and joints neighboring the instrumented levels.

Histological examinations were done by hematoxylin-phloxin-saffron staining of the intervertebral disc including the nucleus pulposus, the annulus fibrosus and the vertebral endplates and the facet joint cartilage.

## Results

**A**nalysis was performed using the experimental data, serial radiological data and the specimens retrieved from 12pigs that survived more than 12months after the surgery to be euthanized (six in RF, six in FF).

In the RF, six animals were sacrificed at 18 months after the surgery. Despite significant growth of the animals from 32 to 62.7kg, the length of the instrumented segment measured by the distance between the uppermost and the lowermost screws remained unchanged. Initial scoliosis of  $31 \pm 5^\circ$  created by rod rotation was maintained at  $27 \pm 8^\circ$  at the time of euthanasia with no significant change in the curve magnitude ( $p=0.37$ , paired t test) showing an acceptable maintenance of fixation (Table 1). The most striking radiological changes observed during the follow up period was progressive thinning of the intervertebral discs within the instrumented section and blurring of the posterior facet joints (Fig. 1A, B, C).

Necropsy examination revealed only a minor fixation failure in one animal (one screw pullout at the proximal end of the construct). Though there was no deliberate attempt of posterior fusion at all, all the facet joints incorporated within the

## Fixation Rigidity

**Table 1.** The results in RF (Rigid Fixation Group)

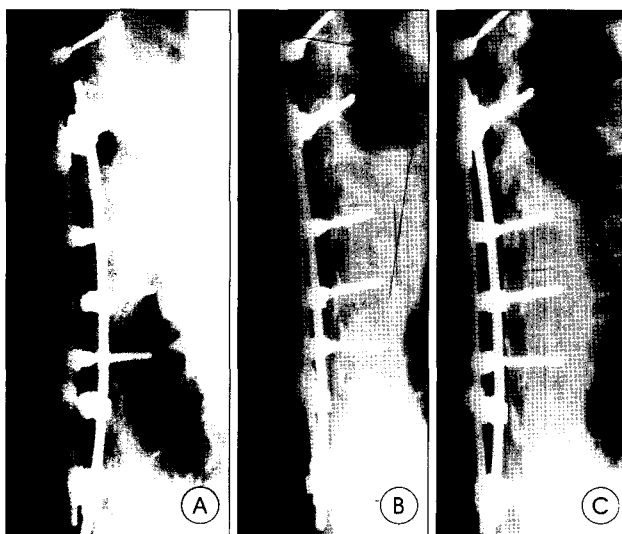
	Immediate Postop	Postop 18Months	p**
Scoliosis (°)	31 ± 5.0	27 ± 8.0	0.37
Sagittal Curve (°)	18 ± 13.0	18 ± 13.0	0.32
Instrumented Section (mm)*	27.6 ± 2.5	28.3 ± 2.9	0.10

\*Corrected for magnification, using the length of the longitudinal members  
\*\*Paired t-test

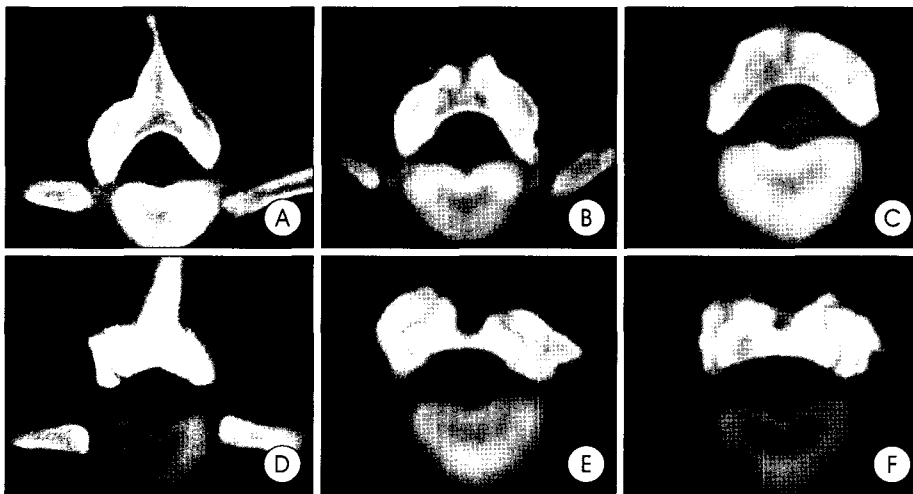
**Table 2.** The results in FF (Flexible Fixation Group)

	Immediate Postop	Postop 18 Months	p**
Scoliosis (°)	19.0 ± 4.0	17.0 ± 5.0	0.21
Instrumented Section (mm)*	25.3 ± 2.0	30.0 ± 1.5	0.0004

\*Corrected for magnification, using the length of the longitudinal members  
\*\*Paired t-test



**Fig. 1.** Serial radiographs in a developing pig instrumented with a rigid fixation system. (A) Immediate postoperative. (B) Postoperative six months. (C) Postoperative 18 months. Progressive thinning of the disc spaces is observed after segmental instrumentation using a rigid fixation system.



**Fig. 2.** Comparison of computerized axial tomography scans of the facet joints within the section. (A,B,C) In rigid fixation group, all the joints are obliterated with bony trabeculae crossing the former joint spaces. (D,E,F) In flexible fixation group, facet joints are well maintained.

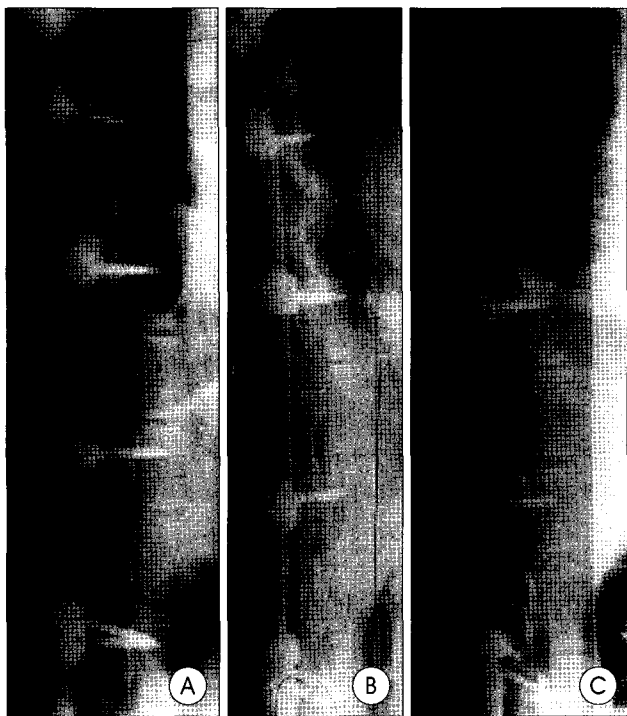
instrumented section showed spontaneous fusion. On the CT scan performed after the removal of the implants, all the facet joints fused with bony trabeculation crossing the former joint space (Fig. 2A).

On manual bending, the instrumented section was very stiff with no perceivable intersegmental motion. When tested with 18G needles for the patency of the disc spaces, abnormally high resistance to the needles was met in all the spaces within the instrumented section. Due to fusion in the posterior joints, direct visual examination of the intervertebral disc necessitated bilateral facet osteotomy to open up the disc spaces. Pathological changes in the incorporated intervertebral discs were loss of the nucleus pulposus, degenerative changes in the annulus and the endplate cartilage. Due to ankylosis and occasional spontaneous fusions, some spaces needed additional osteotomy in the disc space to open up the joint. Similar changes were observed in the intervertebral discs of the neighboring motion segments but were less severe than those in the instrumented section.

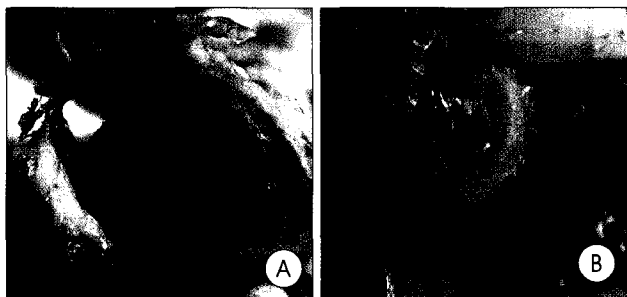
In the FF, two animals were sacrificed at 12 months, four at 18 months. In the observation period the animals demonstrated significant growth from 29.9 to 67.2 kg. The length of the instrumented segment changed from 25.3 ± 2.0 cm to 30.0 ± 1.5 cm showing a growth of 4.7 ± 1.4 cm (p=0.0004, paired t test). Despite 3 minor fixation failures detected on the final x-ray examinations before euthanasia (two pigs with one broken screw, one pig with two broken screws) the experimental scoliotic curve of 19 ± 4° was maintained at 17 ± 5° showing a reasonable maintenance of fixation with no statistically significant alteration of the curve magnitude (p=0.21, paired t test) (Table 2). Serial radiological examinations showed growth of

the spinal segments incorporated within the instrumentation section as evidenced by the increment of the distances between the pedicle screws. Disc height was well maintained within the instrument section (Fig. 3A, B, C).

Necropsy examination confirmed the mechanical failures observed on the x-rays. No additional mechanical failures were detected. On the CT examination performed after removal of the implants, the posterior joints were well maintained with preservation of the joint spaces (Fig. 2B). On manual bending, the spine was supple and



**Fig. 3.** Serial radiographs in a flexible fixation system. (A) Immediate postoperative. (B) Postoperative six months. (C) Postoperative 18 months. The fixation and the intervertebral disc space are well maintained after segmental instrumentation using a flexible fixation system.



**Fig. 4.** Comparison of physical morphologies of the intervertebral discs within the instrumented section. (A) In rigid fixation group, the significant degenerative change of intervertebral disc is observed in the rigid fixation system. (B) In flexible fixation group, nucleus pulposus and the endplate cartilage are well maintained in the flexible fixation system.



**Fig. 5.** Comparison of histological morphologies of the disc slices within the instrumented sections. (A) Normal disc. (B) In rigid fixation group, histological change is characterized by loss of nucleus and degeneration of the annulus fibrosus. (C) In flexible fixation group, the annulus and the nucleus pulposus are well maintained.

allowed movements in all directions. When challenged with 18G needles, the discs within the instrumented levels demonstrated little resistance similar to normal intervertebral discs. Direct visual examination revealed preservation of the nucleus pulposus in the intervertebral discs and the articular cartilage of facet joints in all joints within the instrumented section and the neighboring joints (Fig. 4A, B). Histological examinations revealed viable cartilage in the posterior joints and intervertebral discs endplates without major signs of degeneration (Fig. 5A, B)

## Discussion

Controlling the spine without an arthrodesis is not a new story. It has a much longer history than that of a spinal arthrodesis. External spinal immobilization by plaster of Paris cast and braces before the instrumentation era and the spinal instrumentation without fusion<sup>12)</sup>, rod-long-fuse-short method for the treatment of unstable fractures<sup>7)</sup>, subcutaneous rods and growing rods for pediatric deformities all fall into this category<sup>13)</sup>.

Despite the definite theoretical advantages they offer permitting spinal growth before definite fusion, reduction of the fusion level, or eliminating the need of arthrodesis altogether. These procedures are not very popular except for the external immobilization. This is due to their limited indications, uncertainty of the result and the high failure rate, both mechanically and biologically<sup>14,15)</sup>.

Mechanical failures of the instrumentation without arthrodesis are attributable to the difference between biomechanical characteristics of the spinal implant and the unfused vertebral column<sup>3)</sup>. As instrumentation without fusion procedures relies heavily on the spontaneous acquisition of spinal stability either by healing of the destabilizing lesion or anatomical alteration by growth, the spinal implant will have to withstand stress much longer than those used with fusion, making them more vulnerable to mechanical failures. Untoward biological responses that lead to unsatisfactory results

in instrumentation without fusion are spontaneous fusion, degenerative changes in the intervertebral discs and the facet joint articular cartilage, joint ankylosis and failure to grow or heal as anticipated<sup>4,5,8,12)</sup>.

Spontaneous fusion is the most common and important reason of biological failure that compromises the result of the instrumenta-

## Fixation Rigidity

tion without fusion, the goal of the surgery being preservation of the motion segments. It also greatly decreases the ability of the vertebral column to reacquire intrinsic stability by limiting the growth-determined alteration of the vertebral shape and also by alteration of the force acting on the unfused segments. Formerly thought mainly as a complication of surgery resulting from injury of the vertebral periosteal tube, this untoward reaction seems to be closely related to the rigidity of immobilization the unfused vertebral segments are subjected to<sup>10,11,18</sup>.

Degenerative changes in the intervertebral disc, facet joint articular cartilage and intervertebral joint ankylosis are biological failures that affect the longterm result mainly after the removal of the instrument causing pain stiffness and/or hypermobility and precocious degenerative changes. They occur mainly in the instrumented area but also may occur in the motion segments neighboring the instrumentation due to the stress concentration caused by abrupt change in mobility. Being avascular, the intervertebral disc and facet joint articular cartilage nutrition depends entirely on diffusion and the pressure gradient created by sponge-like squeezing and release of the disc/cartilage by periodic loading/unloading of the joints<sup>6,9</sup>. Disturbance in this nutrient transport mechanism by rigid fixation seriously compromises the biological function of the cartilage/disc cells and results in degenerative changes, which in extreme may lead to total disappearance of the articular cartilage with bony fusion of the joint. Our experimental results show that the viability of the joint cartilage and the intervertebral disc may be maintained, not only by allowing a normal full range of motion but also by micromotion of the intervertebral joint just sufficient for loading/unloading of the avascular connective tissues.

Failure to grow and heal as desired forms the third category of the biological failure and would eventually necessitate a definite restoration of spinal stability by fusion. This may be due to spontaneous fusion, degeneration of the intervertebral and the articular cartilage and also due to inappropriate mechanical forces hindering the growth in the desired direction<sup>14</sup>. Though it is difficult to conclude at this moment, this may be controlled by appropriate combination of rigid and mobile fixations in the same construct.

This experiment of comparing the biological response of the unfused intervertebral joint to the rigidity of spinal fixation was a part of our attempt to develop an instrument system to be used in non-fusion instrumentation, the treatment of pediatric spinal deformities. Unlike in adults and patients near the end of growth, in younger patients with large deformities the bone growth has to be considered in the treatment of the spinal deformities. The remaining growth in the spinal column and

the extremities in young children act both as a negative and a positive factor in the treatment of spinal deformities. Negative in the sense that a lengthy fusion of the spine would result in trunk shortening compared to the extremities, and that fear of such shortening often leads to an inappropriately short fusion, resulting in failure of the deformity control. Positive side is that the growth, with an appropriate force application system, may be exploited to restore the intrinsic mechanical stability of the vertebral column, reversing the destabilizing anatomical alteration in the vertebral body.

Avoiding the negative effects of lengthy fusion while taking advantages of the positive effects of the remaining growth to restore stability was our goal. For an adequate function, the instrument system needed to offer a reliable fixation of the vertebral column to exert desired mechanical force and at the same time allowed some motion in the incorporated intervertebral joints to maintain the viability and translation on the rods for longitudinal growth.

This experiment was performed to determine the balance point in the rigidity/flexibility of the implant that permits both the control of the vertebral column and the maintenance of the joint viability and to test the hypothesis that micromotion of the joint is sufficient to maintain the viability of the intervertebral disc and the articular cartilage. The concept of the micromotion of the joint was particularly important as mechanical fixation failures, the most common mode of failure of the instrumentation without fusion, could only be overcome by narrowing the difference in the flexibility between the vertebral column and the implant. The difference may be reduced either by making the spinal column stiffer by increasing the fixation rigidity or reducing the stiffness of the spinal implant construct by modification of the components. But, since the prime goal of the instrumentation surgery is maintenance of the corrective force on the spine, the balance had to be on the side of making the spine significantly stiffer than the uninstrumented, leaving little alternative than controlled micromotion.

The implant-bone interface forms the grip on the vertebral body and determines the strength of the vertebra held by the instrument. Failure here, though heavily influenced by the overall stiffness of the implant construct, may be also influenced by the biomechanical characteristics of the anchoring member. Spinal pedicle screw, being a penetrating type anchor with resistance, yields the strongest grip on the vertebra and seemed most suitable to serve as anchors in our situation<sup>16,17</sup>.

The characteristic of longitudinal member determines the overall gross stiffness of the implant construct, but not necessarily intersegmental motion, as lever arm of the intersegmental motion is very small compared to the length of implant.

As failure here is mainly due to the stiffness difference of the implant and the vertebral column a smaller diameter (5mm) rod were created using a titanium alloy to permit 15% elastic deformation of the rods under physiologic loads to reduce the stiffness of the implant.

The connecting mechanism that forms the implant-implant determines the stability between the implant members and is the main site determining the intersegmental and the translational motion. Two types of connecting mechanism were designed, one called the fixed chariot to lock the interface to offer control of the rods (e.g. prevent slipping and rotation) and the mobile chariots allowing 6 degree of freedom to allow unconstrained linking between the anchoring and the longitudinal member. By combining two types of connection mechanisms on the same rod, desired mechanical forces could be exerted on the motion segments incorporated within the instrumented section.

## Conclusion

In conclusion, allowing intersegmental micromotion using the flexible unconstrained internal fixation system, the authors could preserve the viability of the intervertebral joints incorporated within the instrumented section while maintaining a reasonably stable fixation in young pigs during the growing period. Though the actual effect in human patients needs to be proven, this new approach of preserving the mobile joints may be a valuable option for long signal fusions often performed with regret due to lack of reliable alternatives.

### • Acknowledgement

The abstract of this study was presented at the 2001 Scoliosis Research Society Annual Meeting. This study was financially supported by the Wooridul Spine Foundation in 2004.

## References

1. Benzel EC : **Spinal Instrumentation. Neurosurgical Topics.** New York : American Association of Neurological Surgeons : 1-288, 1994
2. Bridwell KH, Kuklo TR, Lewis SJ : String test measurement to assess the effect of spinal deformity correction on spinal canal length. Presented at the **35th Annual meeting of the Scoliosis Research Society**, Cairns, Australia, October 17-21, 2000
3. Broom MJ, Jacobs RR : Update-1988. Current status of internal fixation of thoracolumbar fractures. **J Orthop Trauma** 3 : 148-155, 1898
4. Dodd CAF, Fergusson CM, Percy MJ, Houghton GR : Vertebral motion measured using biplanar radiography before and after Harrington rod removal for unstable thoracolumbar fractures of the spine. **Spine** 11 : 452-455, 1986
5. Fisk JR, Peterson HA, Laughlin R, Lutz R : Spontaneous fusion in scoliosis after instrumentation without arthrodesis. **J Pediatr Orthop** 15 : 182-186, 1995
6. Holm S, Nachemson A : Variations in the nutrition of the canine intervertebral disc induced by motion. **Spine** 8 : 866-874, 1983
7. Jacobs RR, Casey MP : Surgical management of thoracolumbar spinal injuries. General principles and controversial considerations. **Clin Orthop** 189 : 22-35, 1984
8. Kahanovitz N, Arnoczky SP, Levine DB, Otis JP : The effects of internal fixation on the articular cartilage of unfused canine facet joint cartilage. **Spine** 9 : 268-272, 1984
9. Katz MM, Hargens AR, Garfin SR : Intervertebral disc nutrition. Diffusion versus convection. **Clin Orthop** 210 : 243-245, 1986
10. Kim KW, Ha KY, Moon MS, Kim YS, Kwon SY, Woo YK : Fate of the facet joints after instrumented intertransverse process fusion. **Clin Orthop** 36 : 110-119, 1999
11. Kim WJ, Lee SH, Shin SW, Rivard CH, Coillard C, Rhalmi S : The effect of segmental pedicle screw instrumentation on actively growing spine : A long-term experimental study. **J Korean Neurosurg Soc** 35 : 502-506, 2004
12. Klemme WR, Denis F, Winter RB, Lonstein JW, Koop SE : Spinal instrumentation without fusion for progressive scoliosis in young children. **J Pediatr Orthop** 17 : 734-742, 1997
13. Luque ER : Paralytic scoliosis in growing children. **Clin Orthop** 163 : 202-209, 1982
14. Mardjetko SM, Hammerberg KW, Lubicky JP, Fister JS : The Luque trolley revisited. Review of nine cases requiring revision. **Spine** 17 : 582-589, 1992
15. Pratt RK, Webb JK, Burwell RG, Fister JS : Luque trolley and convex epiphysiodesis in the management of infantile and juvenile idiopathic scoliosis. **Spine** 24 : 1538-1547, 1999
16. Suk SI, Kim WJ, Kim JH, Lee SM : Restoration of thoracic kyphosis in the hypokyphotic spine : a comparison between multiple-hook and segmental pedicle screw fixation in adolescent idiopathic scoliosis. **J Spinal Disord** 12 : 489-495, 1999
17. Suk SI, Lee CK, Kim WJ, Chung YJ, Park YB : Segmental pedicle screw fixation in the treatment of thoracic idiopathic scoliosis. **Spine** 20 : 1399-1405, 1995
18. Vomanen M, Bostman O, Keto P, Myllynen P : The integrity of intervertebral disks after operative treatment of thoracolumbar fractures. **Clin Orthop** 297 : 150-154, 1993