

Effect of the Third and Fourth Chain Sympathicotomy in Axillary Hyperhidrosis Accompanying Osmidrosis

Seok Won Kim, M.D., Seung Myung Lee, M.D.

Department of Neurosurgery, College of Medicine, Chosun University, Gwangju, Korea

Objective : Thoracoscopic sympatricotomy is effective in treating not only palmar hyperhidrosis, but also axillary hyperhidrosis. But studies for axillary hyperhidrosis accompanying osmidrosis are few. We report the outcome of six axillary hyperhidrosis with osmidrosis with literatures review.

Methods : Using a minimally invasive technique, thoracoscopic T3-4 sympatricotomy was performed. The results of sympatricotomy of third and fourth sympathetic chains of six patients from January 1999 to August 2003 for axillary hyperhidrosis with osmidrosis were reviewed.

Results : All patients had a successful outcomes, their profuse sweating ceased. Two patients suffered from compensatory hyperhidrosis. Three patients disappeared or diminished foul odor but three patients complained remained osmidrosis.

Conclusion : In the treatment of axillary hyperhidrosis, the sympatricotomy of T3 and T4 chain is an effective method but osmidrosis must be treated according to its cause.

KEY WORDS : Axillary hyperhidrosis · Osmidrosis · Thoracoscopic sympatricotomy.

Introduction

Surgical intervention of hyperhidrosis was performed by Kotzareff⁽¹⁰⁾ in 1920. He performed the transthoracic sympathectomy of the T2, T3, T4 and stellate ganglion. Since 1990, endoscopic sympatricotomy became popular as a simple and effective treatment for hyperhidrosis. The success rate for palmar and craniofacial hyperhidrosis is reported to be 94~99% and 75~95%, respectively^(3,4,6). On the other hand, in axillary hyperhidrosis accompanying osmidrosis, the satisfactory rate is relatively low as the wide resection causes compensatory hyperhidrosis frequently^(1-3,5,6). Here, we report the outcome of 6 axillary hyperhidrosis patients with osmidrosis who underwent the transthoracic endoscopic sympatricotomy of the T3 and T4 ganglion, together with a brief review of the literatures.

Materials and Methods

The study population and methods

The study population was 6 patients who underwent the surgery primarily for axillary hyperhidrosis with osmidrosis

at our hospital from January 1999 to August 2003. The ratio of male and female was 2 : 4. Their mean age was 25 years, ranged from 17 years to 35 years. The mean follow-up duration after surgery was 10 months (5~18 months). Three patients had palmar hyperhidrosis. The other three patients had only axillary hyperhidrosis. All patients had osmidrosis.

Operative technique

Under general anesthesia, the patient was placed on the supine position and both arms were abducted in 90°. When the apex of the lung did not collapse easily, the upper body was inclined about 10° to 15° to induce the collapse. As doing so, the apex of the lung was moved to the lower side, which made the site of surgery (the fourth rib) were accessible and improved the surgical view. The anesthesiologist disconnects the ventilator and places suction on the endotracheal tube, resulting in collapse of the lung. A trocar (2mm) is inserted into the pleural cavity through the third intercostal space. The thoracoscope is introduced into the pleural cavity. After a general inspection and identifying the second rib, the coagulation electrocautery probe is introduced through the side-hole of the thoracoscope. After electrocautery scissors were inserted through the trocar in the third intercostal space, interganglionic fibers on the third and fourth rib head were blocked by electrocautery using bovie (Fig. 1). The endoscope was moved to the trocar in the third intercostal space to confirm the expansion of the apex of the lung to avoid co-mplications such as

• Received : June 22, 2004 • Accepted : November 10, 2004
 • Address for reprints : Seok Won Kim, M.D., Department of Neurosurgery, College of Medicine, Chosun University, 588 SeoSeok-dong, Dong-gu, Gwangju 501-717, Korea
 Tel : 062) 220-3120, 3126 Fax : 062) 227-4575
 E-mail : chosunns@hanmail.net

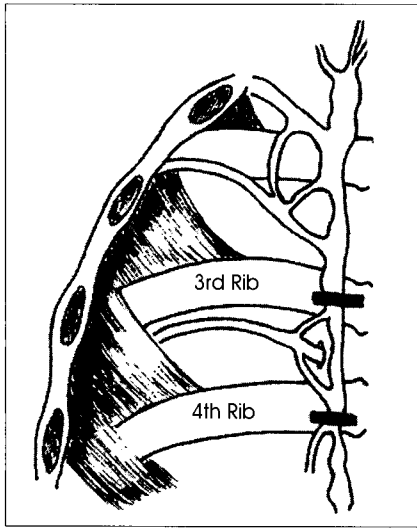


Fig. 1. This figure shows the extent of T3, T4 sympathectomy on the third and fourth rib. to the ward after taking chest X-ray.

pneumothorax, atelectasis. The opposite side is repeated by same manner. In all cases chest tubing wasn't needed even though one case of pneumothorax was occurred. The same sympathectomy procedure was performed in the left side. The patient was moved from

the recovery room antiperspirants containing aluminum chloride (20~25%) in 70~90% alcohol prior to go to bed. Such treatment may be effective, although temporary¹²⁾. Botox (the botulinum toxin type A produced by clostridium botulinum), induces the muscle paralysis by blocking the release of acetylcholine at the nerve junction. Thus, the subcutaneous injection of a small amount of Botox inhibits sweating for 1~12 months depending on the dosage. The shortcomings of Botox are that the effect is temporary and its cost is expensive^{2,8)}. Iontophoresis is to soak the symptomatic area in the electrolyte solution and stimulate with 15~18mA for 20 minutes. Although the application of iontophoresis for several times a week is known to obstruct sweat pores physically, such treatment is relatively ineffective on axillary hyperhidrosis^{3,8,12)}. Recently, surgical removing of sweat glands or apocrine glands by incising the axillary area has been applied.

In 1990, in the treatment of hyperhidrosis, thoracic endoscopic sympathectomy was performed as an effective and permanent treatment¹²⁾. In axillary hyperhidrosis, the T2, T3, and T4 sympathectomy has been performed⁹⁾. However, due to the wide resection area, the incidence of complications such as compensatory hyperhidrosis, hemothorax, and pneumothorax is high and the effectiveness on accompanying osmidrosis is low. Thus, the long-term satisfactory rate was very low (lower than 60%)⁵⁾. The sweating in the axillary area is reported to be under the control of the sympathetic T2~T4 ganglions. The T4 sympathetic ganglion is known to be a target point. Hong et al.⁶⁾ reported that the complication rate such as compensatory hyperhidrosis in T2, T3, T4 sympathectomy is high. The degree of compensatory hyperhidrosis can be reduced by the sympathectomy of the T3 and T4 chain which resects the sympathetic chain less extensively. Although the sympathectomy of the T3 and T4 chain is inferior to sympathectomy with respect to improvement hyperhidrosis, it gives nearly equal satisfaction to patients.

Similarly, in all our patients, satisfactory results were obtained immediately after surgery. Their profuse sweating was ceased immediately after sympathectomy of T3 and T4 chain. However, in 3 patients with osmidrosis in addition to hyperhidrosis, the result was unsatisfactory because osmidrosis was still remained. In the axillary area, apocrine glands are present together with eccrine glands. Thus, the secondary infection of the corneum with bacteria or fungus due to excess sweating from the eccrine glands may cause the foul odor. Alternately, the foul odor may be due to the degradation of the apocrine gland secretion by bacteria on the skin^{3,6,7)}. In patients with osmidrosis, therefore, the cause of foul odor should be clarified. In apocrinal osmidrosis caused by the

Results

Five patients were discharged on the day of surgery. One patient remained in the hospital and observed for three days because of pneumothorax. In all patients, axillary hyperhidrosis was improved. Among them, Two patients complained compensatory hyperhidrosis on the back and thighs. In regard to osmidrosis, three patients were satisfied as it was improved. Three patients responded unsatisfactory even though their hyperhidrosis symptoms was eliminated. Their osmidrosis was not improved and requires additional dermal surgery removing apocrine and eccrine gland.

Discussion

Primary hyperhidrosis without a specific cause sweats profusely under the psychologically tense situation rather than the raised temperature or the increased physical activity. This hinders patients to perform the work properly requiring concentration as well as renders difficulty in the interpersonal relation resulting in the secondary psychological depression¹²⁾. Approximately 0.6~1.0% of the entire population complains hyperhidrosis. In particularly, it is known that the symptom persists for a long time without change, remains throughout life, and is aggravated during the sensitive puberty period. In most cases, hyperhidrosis occurs locally on the area where sweat glands are abundant such as the hands, the feet, the craniofacial area, and the axillary areas^{1,11)}. The primary therapy for axillary hyperhidrosis may be the application of

Sympathicotomy in Hyperhidrosis

degradation of the apocrinal secretion by bacteria, antibacterial soap, deodorant, application of aluminum chloride, dermal surgery, or the removal of apocrine glands by liposuction may be effective. The foul odor, however, may be caused by the secondary infection of the corneum by bacteria or fungi due to excessive sweating, particularly in obese or diabetic patients. In such cases, the treatment of hyperhidrosis alone may reduce the foul odor due to blocking the local bacterial decomposition in some degree⁷⁾ and the combination of the treatment of hyperhidrosis with KMnO₄ or iontophoresis may be more effective.

Conclusion

In the treatment of axillary hyperhidrosis, the sympathicotomy of T3 and T4 chain is an effective method in ceasing sweating. However in hyperhidrosis accompanying osmidrosis, the cause of foul odor should be clarified, whether it is apocrinal or due to the secondary eccrine glandular osmidrosis and additional treatment should be considered in apocrinal osmidrosis patients.

• Acknowledgement

This study was supported by research funds from Chosun University Hospital 2004.

References

1. Adar R : Compensatory hyperhidrosis after thoracic sympathectomy. **Lancet** **24** : 231-232, 1998

2. Bac KM : Two modified T2 sympathicotomies in palmar hyperhidrosis. **Korean J Thorac Cardiovasc Surg** **32** : 818-822, 1999
3. Chon SH, Lee JH : Effect of fourth and fifth chain sympathicotomy in axillary hyperhidrosis. **Korean J Thorac Cardiovasc Surg** **36** : 297-299, 2003
4. Choi SH, Park KJ, Lee SY, Choi JB : Clinical results according to the level and extent of sympathetic block in essential hyperhidrosis. **Korean J Thorac Cardiovasc Surg** **35** : 127-132, 2002
5. Chuang TY, Yen YS, Chiu JW, Chan RC, Chiang SC, Hsiao MP, et al : Intraoperative monitoring of skin temperature changes of hands before, during and after endoscopic thoracic sympathectomy : Using infrared thermograph and thermometer for measurement. **Arch Phys Med Rehabil** **78** : 85-88, 1997
6. Hong YJ, Lee DY, Paik HC, Shin HK, Hwang JJ, Joung EK : Thoracoscopic sympathetic surgery for axillary hyperhidrosis. **Korean J Thorac Cardiovasc Surg** **32** : 1106-1110, 1999
7. Hsia JY, Chen CY, Hsu CP, Shai SE, Yang SS : Outpatient thoracoscopic sympathicotomy for axillary osmidrosis. **Eur J Cardiothorac Surg** **24** : 425-427, 2003
8. Kao MC : Complications in patients with palmar hyperhidrosis treated with transthoracic endoscopic sympathectomy. **J Neurosurg** **42** : 951-951, 1998
9. Kim YH, Jang YH, Moon SW, Jo KH, Wang YP, Kim SW, et al : The changes of sweating area, temperature and blood flow in the upper and lower extremity after hyperhidrosis operations. **Korean J Thorac Cardiovasc Surg** **32** : 456-460, 1999
10. Kotzareff A : Resection partielle de tronc sympathetique survival droit pour hyperhidrose unilaterale. **Rev Med Suisse Romande** **30** : 111-113, 1920
11. Kux E : The endoscopic approach to the vegetative nervous system and its therapeutic possibilities. **Dis Chest** **20** : 139-147, 1951
12. Lai YT, Yang LH, Chio CC, Chen HH : Complications in patients with palmar hyperhidrosis treated with transthoracic endoscopic sympathectomy. **Neurosurgery** **41** : 110-115, 1997