

# Traumatic Carotid-cavernous Fistula Bringing about Intracerebral Hemorrhage

Chang-Ju Lee, M.D., Seung-Won Choi, M.D., Seon-Hwan Kim, M.D., Jin-Young Youm, M.D.

*Department of Neurosurgery, College of Medicine, Chungnam National University, Daejeon, Korea*

Spontaneous intracerebral hemorrhage associated with traumatic carotid-cavernous fistula is rare. The cardinal symptoms of traumatic carotid-cavernous fistula are confined to ocular manifestations. This article describes a case of traumatic carotid-cavernous fistula which was initially diagnosed as an intracerebral hemorrhage, after ocular symptoms were overlooked. Because some cases of carotid-cavernous fistula have an atypical drainage which can result in intracerebral hemorrhage, early diagnosis and intervention are vital to prevent this unwanted intracerebral hemorrhage.

**KEY WORDS :** Carotid-cavernous fistula · Intracerebral hemorrhage · Atypical drainage.

## Introduction

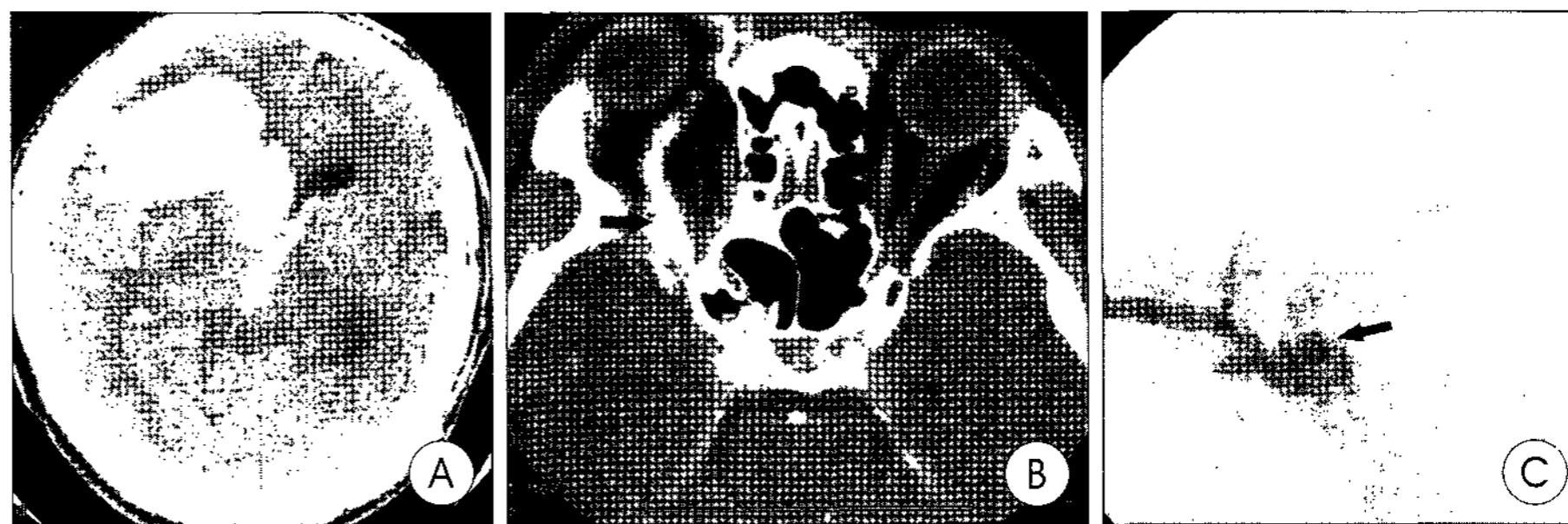
Carotid-cavernous fistula (CCF) is an occasional consequence of head trauma. It is associated with ocular-orbital symptoms that are principally due to orbital venous hypertension. Although CCF has been recognized as a threat to vision for a long time, only a few authors have documented the danger of spontaneous rupture of the fistula<sup>7)</sup>. In this paper, we report spontaneous intracerebral hemorrhage in a patient who had CCF and were overlooked his ocular symptoms. The underlying mechanism is postulated, and the literature concerning intracerebral hemorrhage in CCF is reviewed.

opened right ocular symptoms including diplopia, exophthalmos and conjunctival injection and treated by the department of ophthalmology conservatively in out patients. The patient did not show any symptoms or signs except for visual discomforts and so we did not have any doubt about other intracranial lesion. Two months later, there was a sudden loss of consciousness and the development of weakness in left extremities. On physical examination, a loud cranial bruit was audible, especially over the right eye.

There was also proptosis of the right eye with conjunctival congestion and chemosis. A computed tomography (CT) scan of the brain demonstrated a large right frontal intracerebral

## Case Report

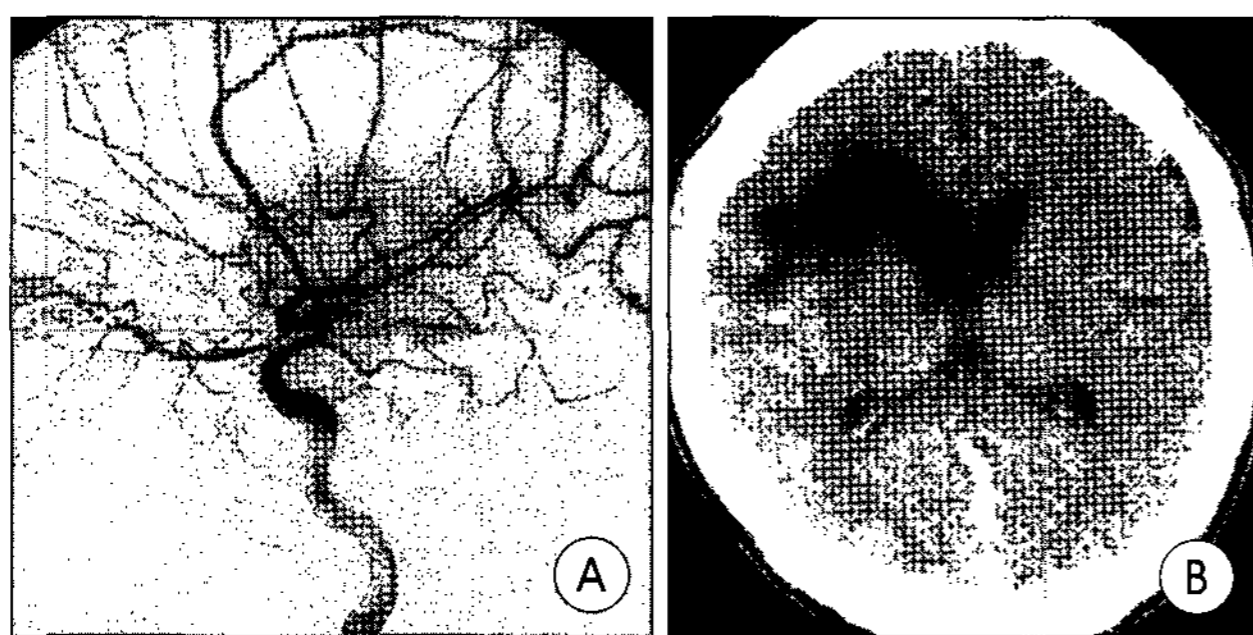
A 26-year-old man sustained multiple injuries in a motor vehicle accident. He suffered from inferior orbital rim fracture, mandible fracture and peritonitis. He was admitted to the department of plastic surgery and was operated on for the mandible fracture. After the operation, he was stable and had no sequela from operation. One month later, he devel-



**Fig 1.** A : Computed tomography scan shows a 4×5×7cm sized intracerebral hemorrhage in the right frontal lobe with intraventricular hemorrhage and right to left midline shift. B : Axial contrast enhanced computed tomography scan shows proptosis of the right eye and dilation of the ophthalmic vein (black arrow). C : Lateral view of right carotid angiogram demonstrates high-flow right-sided carotid-cavernous fistula (black arrow) with early filling and distension of the right superior ophthalmic vein (white arrow).

• Received : February 15, 2005 • Accepted : February 25, 2005

• Address for reprints : Seung-Won Choi, M.D., Department of Neurosurgery, College of Medicine, Chungnam National University, 640 Daesa-dong, Jung-gu, Daejeon 301-721, Korea Tel : +82-42-220-7361, Fax : +82-42-220-7364, E-mail : swonchoi@cnuh.co.kr



**Fig 2.** A : Lateral view of right carotid angiogram after balloon occlusion. The carotid-cavernous fistula is completely occluded. B : Computed tomography scan after the operation shows the intracerebral hemorrhage has been resolved totally.

hemorrhage with shifting of midline to the left (Fig. 1A). A CT scan of the orbit demonstrated a right ophthalmic vein engorgement (Fig. 1B). Right carotid angiography revealed a right carotid-cavernous fistula, right frontal mass and early filling of the superior sagittal sinus. Venous drainage was seen in the sphenoparietal sinus, dilated cortical vein and deep cerebral vein (Fig. 1C). No vascular abnormalities such as a cerebral aneurysm or arteriovenous malformation that can be associated with intracerebral hemorrhage were detected.

Left carotid and vertebral angiography did not show any further abnormalities. The fistula was occluded by using a detachable balloon via femoral arterial catheterization and the intracerebral hemorrhage was removed by burr-hole trephination. After operation, his consciousness and weakness of left extremities gradually improved. Repeated angiography confirmed complete fistula closure with preservation of the parent vessel (Fig. 2A). Postoperative CT scan showed a satisfactory result (Fig. 2B).

## Discussion

Traumatic CCF is a well-known vascular injury and it may present a broad spectrum of clinical symptoms. The cardinal symptoms of the CCF are ocular manifestations such as exophthalmos, ocular pulsation, conjunctival injection and orbital bruit<sup>5)</sup>. Other symptoms that have been described in the literature include visual disturbance, ophthalmoplegia, and occasional epistaxis. As a rule, CCF does not cause hemiplegia or endanger life and reported incidence of life-threatening intracerebral hemorrhage from CCF is 0.9%<sup>2)</sup>. Catastrophic complications may occur as a fatal epistaxis or intracranial hemorrhages but it is quite rare<sup>7,8)</sup>.

According to the direction of venous outflow, the clinical syndrome is very diverse from only subjective complications of bruit and tinnitus to severe complications of seizure, focal deficit, or intracranial hemorrhage<sup>6)</sup>. So, it is important to know the venous drainage pattern<sup>4)</sup> which can represent the possibility

of intracerebral hemorrhage in CCF. In typical pattern, CCF may drain from the cavernous sinus anteriorly into the ophthalmic vein, inferiorly into the pterygoid plexus, superiorly into the sphenoparietal sinus, or posteriorly into the petrosal sinus<sup>3)</sup>. In the case of a typical CCF drainage pattern, the patient will exhibit the characteristic orbital symptoms due to intraorbital venous hypertension. In the intracerebral hemorrhage case, on the other hand, an atypical drainage pattern is developed in cerebral venous system via the sphenoparietal sinus or other collateral channels, such as the cortical vein or deep cerebral vein<sup>4)</sup>.

In our case, we could find atypical drainage pattern from cerebral angiography either. So, we can presume that the venous hypertension from atypical drainage in this case gave rise to intracerebral hemorrhage. As a conclusion, distension and rupture of multiple venous channels which are derived from atypical drainage in high flow CCF is the main cause of intracerebral hemorrhage.

So, CCF requires an early diagnosis and intervention. Treatment of the intracerebral hemorrhage in traumatic CCF requires two phases of surgery : one for hematoma removal and the other for CCF itself, because uncontrollable venous bleeding could be caused by the removal of hematoma before occlusion of the fistula<sup>6)</sup>. Thus, the obliteration of the CCF by detachable balloon is essential in all patients and it is best to close the fistula before removal of the hematoma<sup>1)</sup>.

## Conclusion

As has been pointed out by previous authors, CCF with an atypical venous drainage pattern has a risk of the life-threatening complication of intracerebral hemorrhage. Without urgent and aggressive intervention in CCF, atypical drainage can be developed. If it is doubted that patients has a CCF, physician should have an early cerebral angiography. In cerebral angiography, physician should have concentration to the venous drainage pattern and if there is a atypical drainage pattern, early treatment is strongly recommended.

## References

1. Ahn JY, Choi HK, Lee BH, Choi EW : Transarterial Guglielmi detachable coils embolization with stenting for the treatment of a traumatic carotid-cavernous fistula. *J Korean Neurosurg Soc* 32 : 156-158, 2002
2. d'Angelo VA, Monte V, Scialfa G, Fiumara E, Scotti G : Intracerebral venous hemorrhage in "high risk" carotid-cavernous fistula. *Surg Neurol* 30 : 387-390, 1988
3. Debrun G, Laour P, Vinuela F, Fox A, Drake CG, Caron JP : Treatment of 54 traumatic carotid-cavernous fistulas. *J Neurosurg* 55 : 678-692, 1981
4. Hiramatsu K, Utsumi S, Kyoji K, Sakaki T, Tada T, Iwasaki S, et al : Intracerebral hemorrhage in carotid-cavernous fistula. *Neuroradiology* 33 : 67-69, 1991
5. Sim HB, Choi BO, Lee SI, Jung YT, Kim SC, Sim JH : Clinical analysis of Traumatic Carotid Cavernous Fistula. *J Korean Neurosurg Soc* 25 :

- 720-734, 1996
6. Tanaka A, Fukushima T, Tomonaga M : Intracerebral hematomas in cases of dural arteriovenous malformation and carotid-cavernous fistula. *Surg Neurol* 25 : 557-562, 1986
  7. Tuner DM, Vangilder JC, Mojtahedi S, Pierson EW : Spontaneous intracerebral hematoma in carotid-cavernous fistula. *J Neurosurg* 59 : 680-686, 1983
  8. Vaghi MA, Savoiardo M, Stranda L : Unusual computerized tomography appearance of a carotid-cavernous fistula. *J Neurosurg* 58 : 435-437, 1983