

Endovascular Treatment by using Double Stent Method for Ruptured Vertebral Artery Dissecting Aneurysms

Sung Hoon Kim, M.D.,¹ Chang Hwa Choi, M.D.,¹ Tae Hong Lee, M.D.,² Sang Weon Lee, M.D.¹

Department of Neurosurgery,¹ Diagnostic Radiology,² School of Medicine, Pusan National University, Busan, Korea

We report two cases of patients with ruptured vertebral artery dissecting aneurysms that were treated using double overlapping stent placement. Angiography performed immediately after the procedure revealed a significant reduction of aneurysmal filling due to the intraaneurysmal thrombosis. In one case, complete disappearance of the lesion was observed after seven days and in the another one, the size of previous aneurysm sac was decreased on 7th post-procedure day. The reduced stent porosity caused by the overlapping stents, which result in significant hemodynamic changes inside aneurysmal sac, may accelerate intraaneurysmal thrombosis and may be helpful in achieving a more rapid complete occlusion of aneurysm. This double stent method may represent a therapeutic alternatives for dissecting vertebral artery aneurysm in which conventional endovascular techniques or stent supported coil embolization is not considered feasible and surgical treatment is contraindicated.

KEY WORDS : Dissecting vertebral artery aneurysm · Double stents.

Introduction

Endovascular treatment of intracranial aneurysms has advanced in recent years. But, it still pose a therapeutic challenge. The release of 3D coils, balloon-assisted embolization, or combination of stents and coils have all proved helpful in the treatment of aneurysms. The combination of stent placement with coils is currently preferred instead of parent artery

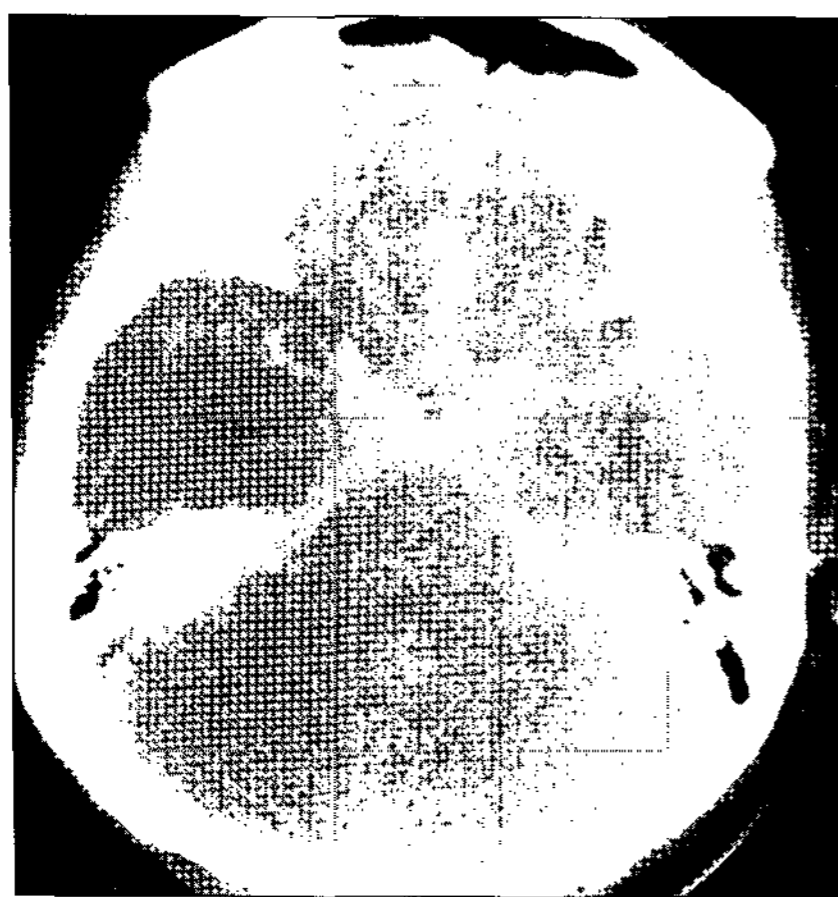

Fig. 1. Diffuse subarachnoid hemorrhage is observed on computed tomography.

occlusion. However, the use of this method may be limited by the difficulty in navigating the catheter through the stent into the aneurysms. Also, it may be associated with a high risk of aneurysm rupture either during catheterization or subsequent coil

placement. So, double stent placement might be sufficient to alter the hemodynamic situation, leading to reduced inflow and accelerated aneurysm thrombosis. We describe two successful cases of vertebral dissecting aneurysm which were treated by double stent placement.

Case Report

Case 1

A 34-year-old man presented with subarachnoid hemorrhage (SAH). His computerized tomography(CT) scans revealed SAH which was more marked in the basal cistern and interhemispheric fissure but no hydrocephalus(Fig. 1). Hunt and Hess grade was II. Digital subtraction angiography(DSA) revealed a 5mm sized aneurysm with a wide neck distal to the origin of left posterior inferior cerebellar artery(Fig. 2). Because of the favorable anatomic conditions in the dissected vessel segment, endovascular stent placement was considered as the method of treatment. The therapeutic procedures were performed during a second angiography session. Under general anesthesia, a 6 Fr guiding catheter (Envoy, Cordis Endovascular Corporation, U.S.A.) was positioned high in the left vertebral artery (VA). The baseline activated clotting time(ACT)

• Received : December 22, 2004 • Accepted : April 25, 2005

• Address for reprints : Chang-Hwa Choi, M.D., Department of Neurosurgery, School of Medicine, Pusan National University, 1-10 Ami-dong, Seo-gu, Busan 602-739, Korea Tel : +82-51-240-7257, Fax : +82-51-244-0282, E-mail : chwachoi@pusan.ac.kr

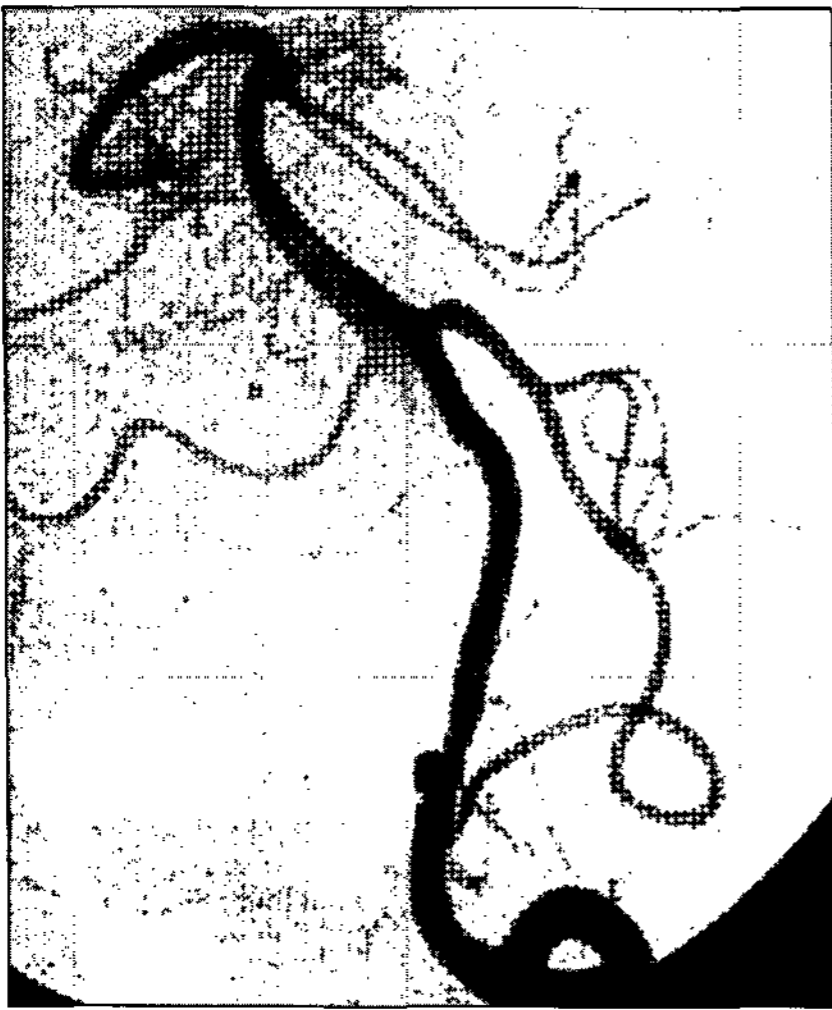

Fig. 2. An aneurysm with a wide neck and 5mm in size distal to the origin of the left posterior inferior cerebellar artery is formed on angiogram.

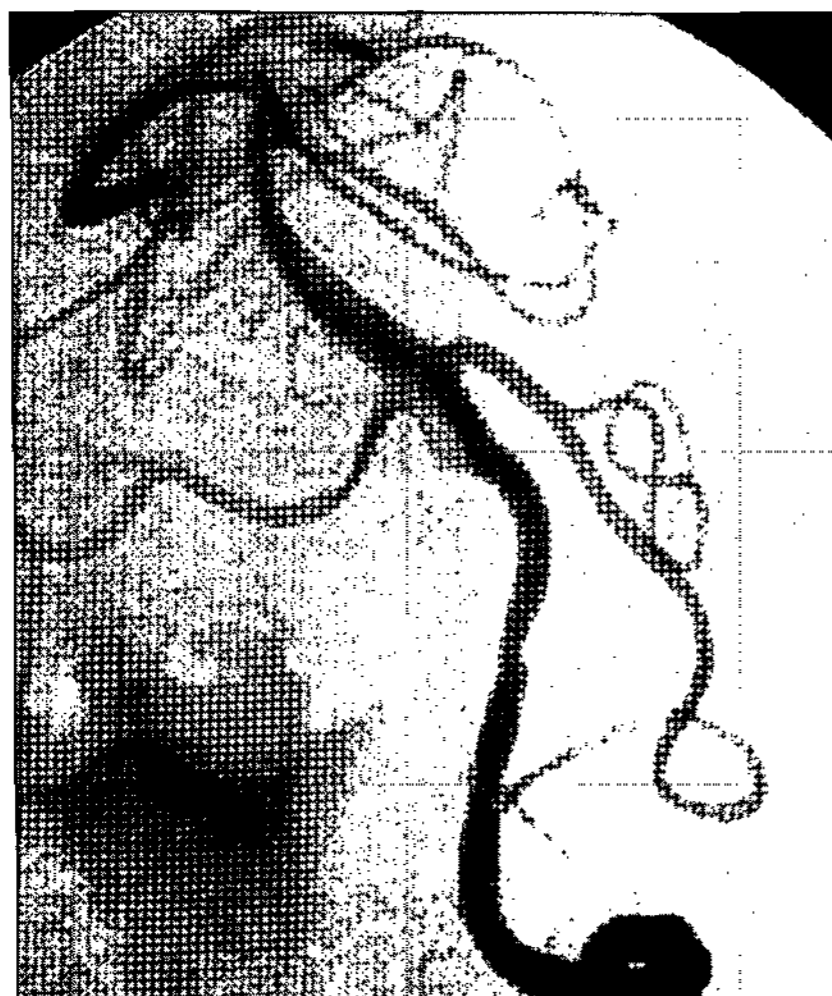

Fig. 3. On immediate post-procedural angiogram, total occlusion of inflow into the aneurysm sac is confirmed.

support, thus allowing tracking of the balloon-mounted stent catheter. A 2.5×15 -mm balloon-expandable coronary stent (S660, AVE, Medtronic, Minneapolis, MN) was advanced over the microwire and was positioned across the aneurysm using the road mapping imaging and external stent markings. We confirmed angiographically the stent covered the parent artery distal to the aneurysm and the aneurysmal neck itself. Then, we deployed the stent by balloon inflating. The balloon was slowly inflated to prevent vascular dissection or rupture by the dog-bone phenomenon of the balloon. At first, the pressure was elevated to nominal pressure, and angiography was performed after balloon deflation to identify the results and possible complications. If the gap between the stent and the parent artery remained on angiography, balloon inflation was repeated until the gap between the stent and the parent

artery disappeared. Balloon pressures did not exceed the burst pressure of the stent and balloon. When there was complete apposition between the stent and the parent artery, the stent delivery system was withdrawn, leaving the microwire. The second 2.5×18 mm balloon-expandable coronary stent (S660, AVE, Medtronic, Minneapolis, MN) was advanced to overlap with the first one, and we placed the stent at the lesion covering the parent artery proximal to the aneurysm and the aneurysmal neck itself. Immediate post-procedural angiogram revealed that the lumen of left vertebral artery was well preserved, overlapped stents well covered the dissecting aneurysm, and inflow into the aneurysm was significantly reduced (Fig. 3).

After the procedure, hemostasis of the femoral artery was achieved using an occlusion device (Angioseal, St. Jude Medical, Belgium). The patient was transferred to the neurosurgical intensive care unit and stayed for 2 days. He was medicated daily with 100mg aspirin and 75mg clopidogrel (Plavix; SanofiSynthelabo, Korea); 2850 IU of low-molecular-weight nadroparin calcium (Fraxiparine; Sanofi-Synthelabo, Korea) were also administered subcutaneously twice or three times a day for three days.

Follow-up angiogram was performed to identify early changes of the aneurysmal filling on the 7th post-procedural day. It revealed complete disappearance of the aneurysm (Fig. 4). Clinically, the patient recovered with no neurological deficit.

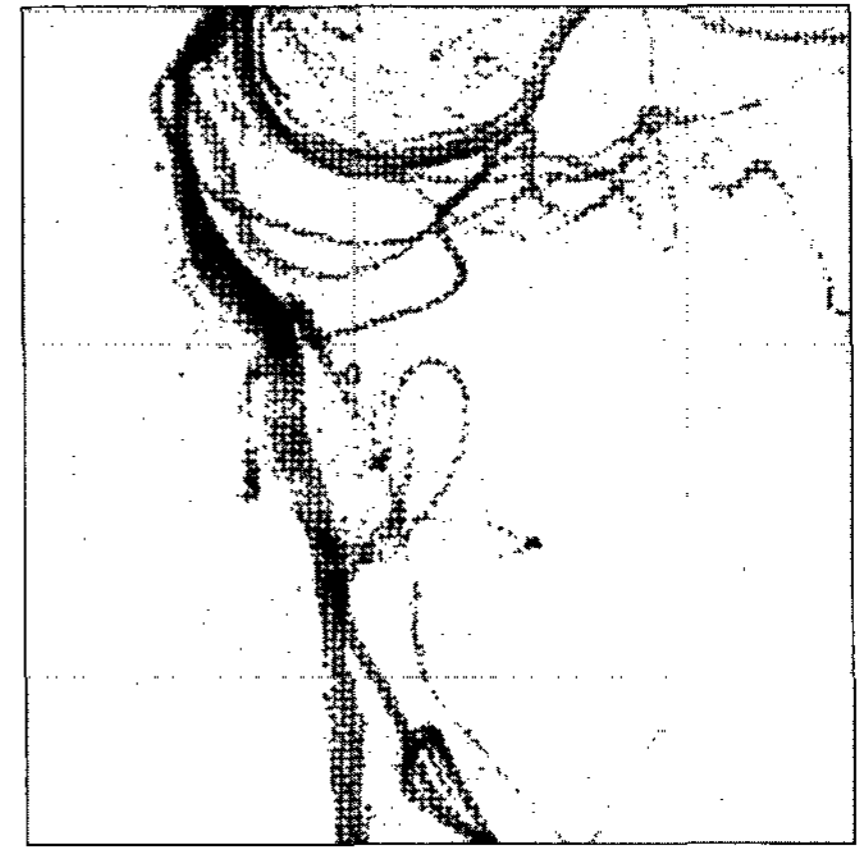

Fig. 4. Total occlusion of left vertebral dissecting aneurysm sac is seen narrowing is not found in left vertebral artery on follow up angiogram in the 7th post-procedural day.

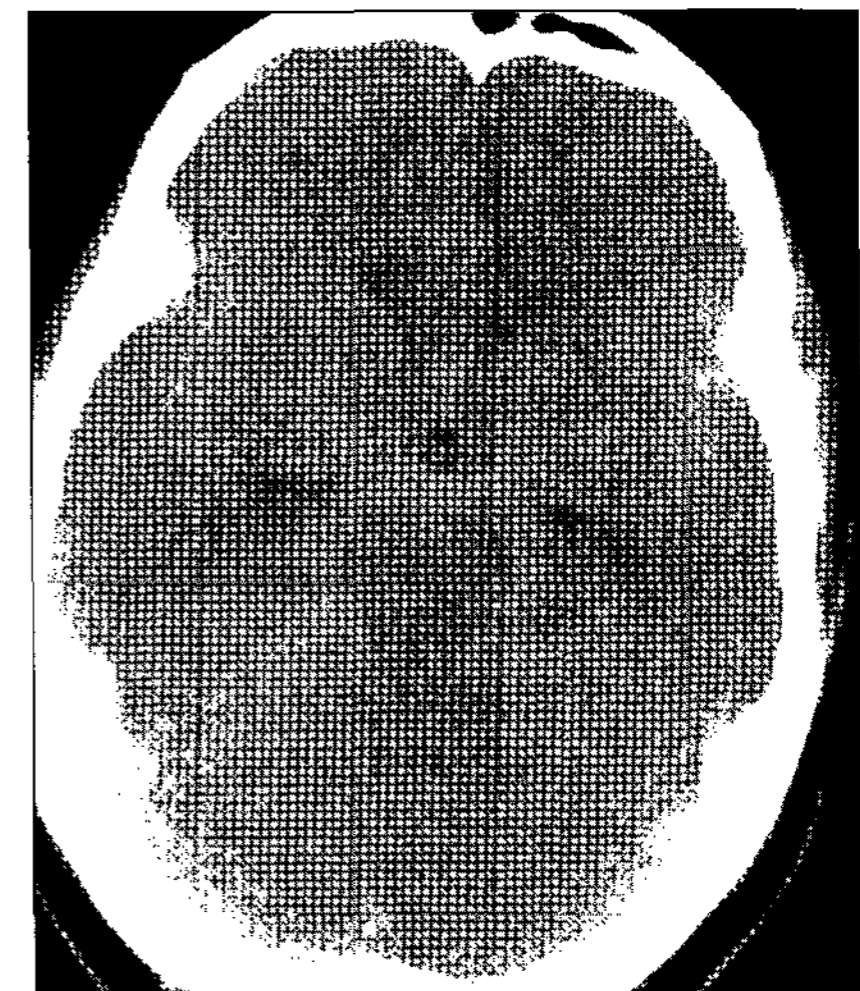


Fig. 5. Subarachnoid hemorrhage is detected in basal cistern, inter-hemispheric fissure, and transylvian fissure on computed tomography.




Fig. 6. Fusiform aneurysm involving the proximal segment to the origin of right posterior inferior cerebellar artery is seen on angiogram.

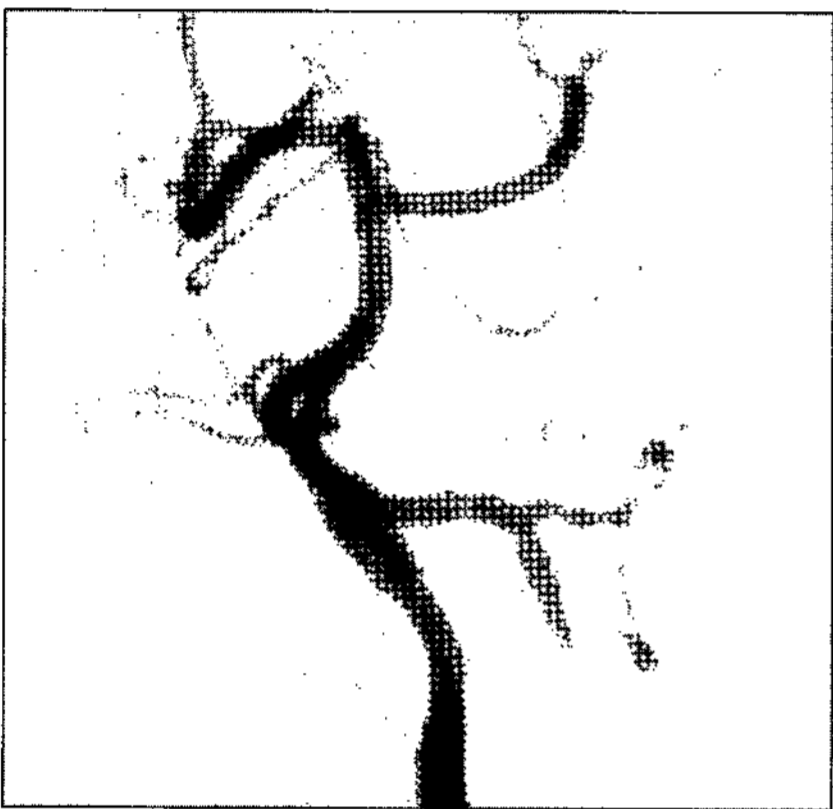


Fig. 7. On immediate post-procedural angiogram, the lumen of right vertebral lumen is preserved and inflow into aneurysm sac is slightly reduced.

general anesthesia, a 6 Fr guiding catheter was placed high in the right vertebral artery. Then patients received systemic heparinization and a bolus injection of 3000IU of heparin just before starting the therapeutic procedure. The dissected segment of the vertebral artery was then crossed with a 205-cm-long 0.014-in microwire that was navigated into the cortical branch of the PCA to ensure maximal support, thus allowing tracking of the balloon-mounted stent catheter. A 2.5 × 16-mm balloon-expandable coronary stent (Flexmaster, JoMed GmbH, Rangendingen, Germany) was advanced over the microwire. We angiographically confirmed the stent covered the parent artery distal to the aneurysm and the aneurysmal neck itself. We then deployed the stent by balloon inflating. An additional 2.5 × 19-mm balloon-expandable coronary stent (Flexmaster, JoMed GmbH, Rangendingen, Germany) was advanced to overlap with the first one, and we placed the stent at the lesion covering the parent artery proximal to the aneurysm and the aneurysmal neck itself. Immediate post-procedural angiogram revealed that the lumen of right vertebral artery was well preserved and overlapped stents were well covered the dissecting

Case 2

A 53-year-old woman presented with a sudden onset of severe headache and dizziness. The non-enhanced brain CT showed SAH. Hunt and Hess grade was III. Angiography revealed a fusiform aneurysm involving the proximal segment to the origin of right posterior inferior cerebellar artery (Fig. 6). Because coil embolization was considered unfeasible without protrusion of the coil in the parent artery, endovascular stent placement was chosen as the treatment of choice. Under

aneurysm. Inflow into aneurysm was slightly reduced (Fig. 7).

After the procedure, hemostasis of the femoral artery was achieved using an occlusion device (Angioseal, St. Jude Medical, Belgium). The patient was transferred to the neurosurgical intensive care unit and stayed for 1 day. He was medicated daily with 75mg clopidogrel and 2850 IU of nadroparin calcium were also administered subcutaneously twice a day for three days.

Follow-up right vertebral artery angiogram was performed to identify early changes of the aneurysmal filling on the 7th post-procedural day. It revealed the decreased contrast filling into the aneurysm by intraaneurysmal thrombosis (Fig. 8). At 6 weeks after procedure, nearly total occlusion of the previous aneurysm was seen in angiography (Fig. 9). Clinically, the patient recovered with no neurological deficit.

Discussion

Under experimental conditions, stents are able to reduce the flow within the aneurysm and thus induce intraaneurysmal thrombosis^{8,13}. Computer simulation of local hemodynamics has revealed that intraaneurysmal stasis results from an increased resistance to flow into the aneurysm through the stent mesh combined with a low-pressure gradient between the parent artery and the aneurysm¹. Lanzino⁶ reported on four patients who were originally treated with stent placement alone. In these patients some stasis was observed angiographically, but it was insufficient for aneurysm occlusion, as observed immediately or during follow-up examinations performed at 48 hours, 4 days, and 3 months after stent




Fig. 8. On the 7th post-procedural day, the decreased contrast filling into the aneurysm by intraaneurysmal thrombosis is observed on follow up angiogram.



Fig. 9. At 6 weeks after procedure, nearly total occlusion of previous aneurysm is formed and narrowing is not found in right vertebral artery on angiogram.

deployment. By using double placement of stents (one stent inside another), the permeability of the stent might be significantly reduced⁸⁾. Inflow might be sufficient to accelerate aneurysm thrombosis.

There are only a few case reports on the use of two stents for the treatment of aneurysm. Benndorf and associates³⁾ reported the double stent method to treat a ruptured dissecting VA aneurysm. Recently, Islak and colleagues⁵⁾ presented 2 cases in treating aneurysms by using double stent method. They delivered first one stent, which they anchored at both ends of the aneurysm neck, to serve as a guiding strut for the subsequent safe placement of a stent graft to cover the inflow zone of the aneurysms.

Because the result is the immediate exclusion of the aneurysm, the use of a stent graft is theoretically most effective way to occlude fusiform aneurysm²⁾. The main disadvantage of this method, however, is the inevitable closure of important perforating arteries arising from the segment where the stent graft is placed and an increased thrombogenicity and inflammatory reaction with increased intimal hyperplasia¹¹⁾.

Because the majority of procedure-related complications are thromboembolic in nature, anticoagulation management is of great importance^{7,12)}. We use intravenous heparin during procedure in all patients who undergo endovascular aneurysm treatment. To reduce the risk of stent thrombosis, effective heparinization was started before stent placement and continued for up to 24 hours after stent placement. The patients also received a daily dose of 75mg of clopidogrel and 100mg of aspirin.

In our opinion, early and careful follow-up angiographic studies are mandatory to identify possible changes in aneurysm filling that may possibly be due to recanalization of a formerly partially thrombosed aneurysm. On 7 days after the procedure, control angiography to demonstrate complete aneurysm occlusion was done.

One might think that double-stent placement is associated with a higher risk of intimal hyperplasia, possibly leading to luminal stenosis. Additionally, one might think that with double-stent placement, the caliber of the artery might be reduced, possibly leading to more turbulence and increased risk of thrombosis or stenosis. We did not observe these problems in our two patients, nor did we observe significant intimal hyperplasia during the follow-up period. Benndorf and associates²⁾ also reported mild, nonstenotic intimal hyperplasia on follow-up arteriograms obtained 20 months after double-stent placement in an extracranial pseudoaneurysm.

Conclusion

The double-stent method may be a therapeutic alternative for vertebral dissecting aneurysms, in which conventional endovascular techniques or stent-supported coil embolization is considered unfeasible or is believed to be too dangerous.

Additional experience and long-term follow-up is necessary to define the overall role of this method in the endovascular management of aneurysms.

References

1. Aenis M, Stancampiano AP, Wakhloo AK, Lieber BB : Modeling of flow in a straight stented and non-stented side wall aneurysm model. *J Biomech Eng* 119 : 206-212, 1997
2. Benndorf G, Campi A, Schneider GH, Wellnhofer E, Unterberg A : Overlapping stents for treatment of a dissecting carotid artery aneurysm. *J Endovasc Ther* 8 : 566-570, 2001
3. Benndorf G, Herbon U, Sollmann WP, Campi A : Treatment of a ruptured dissecting vertebral artery aneurysms with double stent placement : case report. *AJNR* 22 : 1844-1848, 2001
4. Cloft HJ, Joseph GJ, Tong FC, Goldstein JH, Dion JE : Use of three-dimensional Guglielmi detachable coils in the treatment of wide-necked cerebral aneurysms. *AJNR* 21 : 1312-1314, 2000
5. Islak C, Kocer N, Albayram S, Kizilkilic O, Uzna O, Cokyuksele O : Bare stent-graft technique : a method of endoluminal vascular reconstruction for the treatment of giant and fusiform aneurysms. *AJNR* 23 : 1589-1595, 2002
6. Lanzino G, Wakhloo AK, Fessler RD, Hartney ML, Guterman LR, Hopkins LL : Efficacy and current limitations of intrasaccular stents for intracranial internal carotid, vertebral, and basilar artery aneurysm. *J Neurosurg* 91 : 538-546, 1999
7. Levy EI, Boulos AS, Bendok BR, Kim SH, Qureshi AL, Guterman LR, et al : Brainstem infarction after delayed thrombosis of a stented vertebral artery fusiform aneurysm : case report. *Neurosurgery* 51 : 1280-1284, 2002
8. Lieber BB, Stancampiano AP, Wakhloo AK : Alteration of hemodynamics in aneurysm models by stenting : influence of stent porosity. *Ann Biomed Eng* 25 : 460-469, 1997
9. Moret J, Cognard C, Weill A : La technique de reconstruction dans le traitement des aneurysms intracranien a collet large. Resultats angiographiques et cliniques a long terme. A propos de 56 cas. *J Neuroradiol* 24 : 30-44, 1997
10. Murayama Y, Vinuela F, Tateshima S, Vinuela F Jr, Akiba Y : Endovascular treatment of experimental aneurysms by use of a combination of liquid embolic agents and protective devices. *AJNR* 21 : 1726-1735, 2000
11. Phatouros CC, Sasaki TY, Higashida RT, Malek AM, Meyers PM, Dowd CF, et al : Stent-supported coil embolization : the treatment of fusiform and wide-neck aneurysms and pseudoaneurysms. *Neurosurgery* 47 : 107-115, 2000
12. Qureshi AI, Luft AR, Sharma M, Guterman LR, Hopkins LN : Prevention and treatment of thromboembolic and ischemic complications associated with endovascular procedures : Part II - Clinical aspects and recommendations. *Neuro-surgery* 46 : 1360-1376, 2000
13. Wakhloo AK, Schellhammer F, de Vries J, Haberstroh J, Shumacher M, et al : Self-expanding and balloon-expandable stents in the treatment of carotid aneurysms : an experimental study in a canine model. *AJNR* 15 : 493-502, 1994