

A Morphometric Analysis of the Foramen Ovale and the Zygomatic Points Determined by a Computed Tomography in Patients with Idiopathic Trigeminal Neuralgia

Sung Hyuk Hwang, M.D., Myung Ki Lee, M.D., June Woo Park, M.D.,
Jae Eon Lee, M.D., Chang Won Cho, M.D., Dae Jo Kim, M.D.

Department of Neurosurgery, Maryknoll General Hospital, Busan, Korea

Objective : The purpose of this study is to measure the dimensions of foramen ovale and to localize the zygomatic point using computed tomography(CT) in Korean adults with idiopathic trigeminal neuralgia.

Methods : Facial axial CT scans using the orbitomeatal plane were performed in 67patients (39males and 28females; mean age 58.8years) with idiopathic classic trigeminal neuralgia. We measured the size of the foramen ovale and localized the zygomatic point which was a skin marker over the ipsilateral zygoma that approximates the lateral projection of a straight line joining the centers of the two foramen ovale.

Results : The axial dimensions of the foramen ovale on the orbitomeatal plane were of average length : 8.18 ± 0.82 mm (range 6.9~11.5mm), width : 4.06 ± 0.86 mm (2.5~5.7mm). The average distance between the external acoustic meatus and the zygomatic point was 21.64 ± 1.99 mm (16.3~25.0mm) and the average distance of anterior margin of condylar process of mandible to zygomatic point was 4.29 ± 1.19 mm (1.0~7.0mm).

Conclusion : The anatomical understandings including the size of the foramen ovale and localization of the zygomatic point could be helpful in determining a plan of percutaneous approaches to foramen ovale.

KEY WORDS : Foramen ovale · Zygomatic point · Trigeminal neuralgia.

Introduction

The anterior approach to the foramen ovale has been used since its description by Hartel in 1914^{6,7,11}. The free-hand technique of Hartel in introducing an electrode through the foramen ovale may cause serious complications^{5,8,11}. Therefore, the method has been improved by a combination of new technology and modifications by several authors using radiographic and free hand techniques³. Even with an ideal positioning of the patient's head, it can be difficult to clearly visualize the foramen ovale. Technical difficulties in finding the foramen ovale without delay and with the risk of damage to surrounding tissue have encouraged surgeons to design special instruments for that purpose³.

The skin landmarks of the Hartel's method are generally used

for the penetration of the foramen ovale. Three anatomic landmarks are chosen on the face. They are the cheek point, the zygomatic point, and the pupil point^{6,8,11}.

Large series of percutaneous procedures making use of skin landmarks including the zygomatic point to penetrate the foramen ovale have been performed in western countries^{7,9,10}, however since the localization of zygomatic point has not been reported in Korea, we tried to localize the zygomatic point in relation to the external acoustic meatus and the condylar process of the mandible. We also measured the axial dimension of the foramen ovale. But there have been few reports about methods of measuring the size of the foramen ovale except for the measurement with cadaver skulls reported by Nugent and others^{7,9}. Facial axial computed tomography (CT) using the orbitomeatal plane was performed on 67

• Received : January 7, 2005 • Accepted : April 19, 2005

• Address for reprints : Myung Ki Lee, M.D., Department of Neurosurgery, Maryknoll General Hospital, 12 Daecheong-dong 4ga, Jung-gu, Busan 600-730, Korea Tel : +82-51-461-2774, Fax : +82-51-466-6164, E-mail : stereomk@shinbiro.com

patients for about the last 3 years with idiopathic classic trigeminal neuralgia.

Materials and Methods

Between January 2002 and October 2004, 67 patients with idiopathic classic trigeminal neuralgia underwent facial axial CT (49 patients with the Shimadzu 5000TX and 18 patients with the Toshiba Aquilion 16 TSX-101A) for the measurements of the foramen ovale and the localization of the zygomatic point—that is a skin marker over the ipsilateral zygoma that approximates the lateral projection of a straight line joining the centers of the two foramen ovale. There were 39 men and 28 women, ranging in age from 31 to 81 years, with a mean age of 58.8 ± 10.9 years. CT, magnetic resonance image and skull basal X-ray study were also obtained from all patients. No patient had an underlying pathologic condition such as trauma, tumor, arteriovenous malformation, multiple sclerosis, or the structural deformity of the skull base. Facial CT scans were obtained at intervals of 2 mm based on the orbitomeatal line (Fig. 1). We measured the distance between the center of the external acoustic meatus and the zygomatic point and the distance between the anterior margin of the condylar process of the mandible and the zygomatic point (Fig. 2). We also measured the axial dimension of the foramen ovale sectioned at the level of the orbitomeatal plane using facial CT. The length was calculated as the longest axis of the sectioned axial foramen ovale on that plane and the width as the shortest axis of one.

Statistical analysis was performed using SPSS for Windows (version 11.0, SPSS Inc.). The paired t-tests were used for the comparison of the differences between right and left and two sample t-test was used for the comparison between sex groups. P value of <0.05 was considered significant.

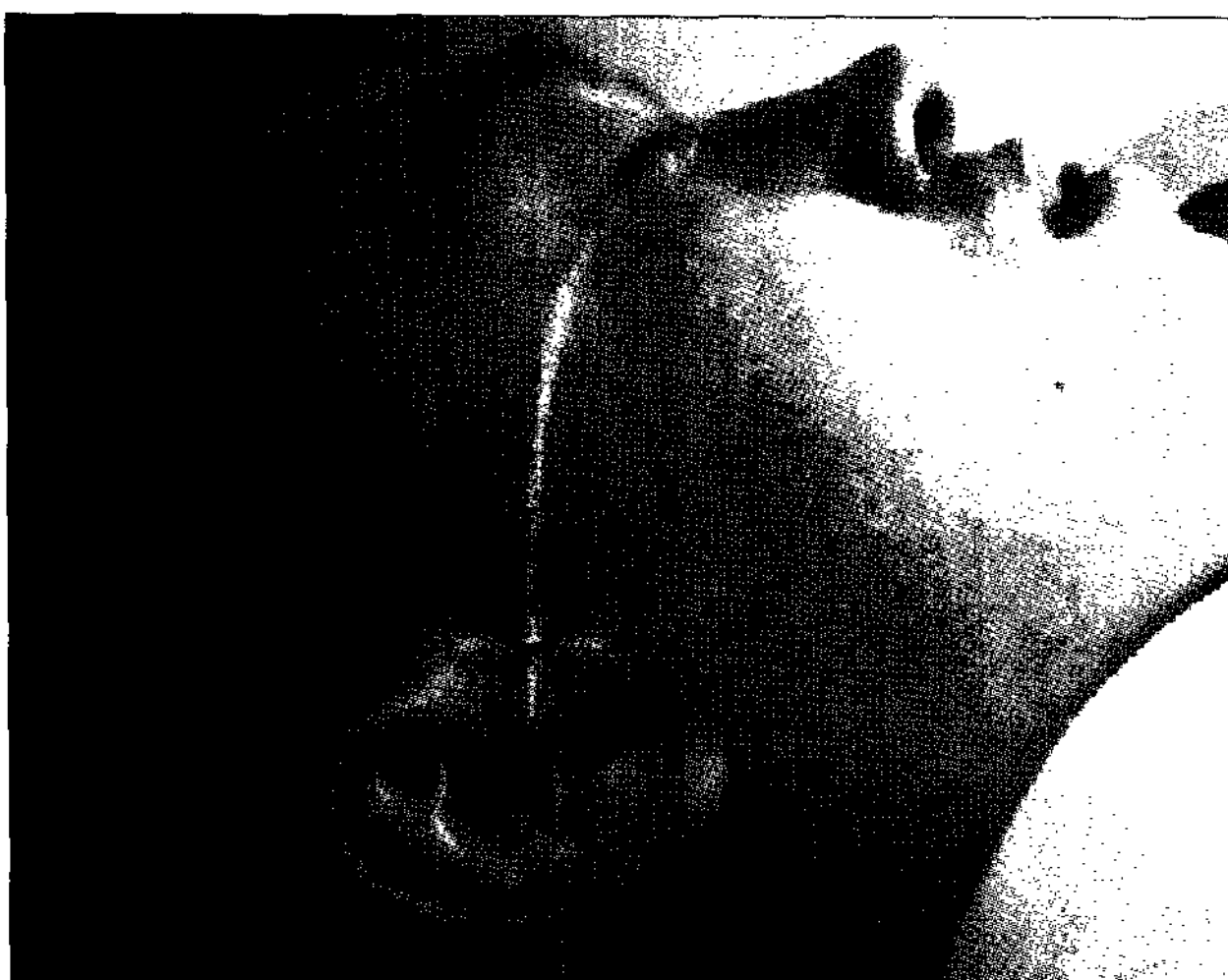

Fig. 1. Orbitomeatal line : A Line from the lateral canthus to the external acoustic meatus.

Results

Morphometric analysis of the foramen ovale and the localization of the zygomatic point in relation to the external acoustic meatus and the condylar process of the mandible in 67 patients is listed in Table 1. In both sex groups, the average distance between the external acoustic meatus and the zygomatic point was Left : 21.65 ± 2.05 mm (range 17.2~25.0) Right : $21.62 \pm$

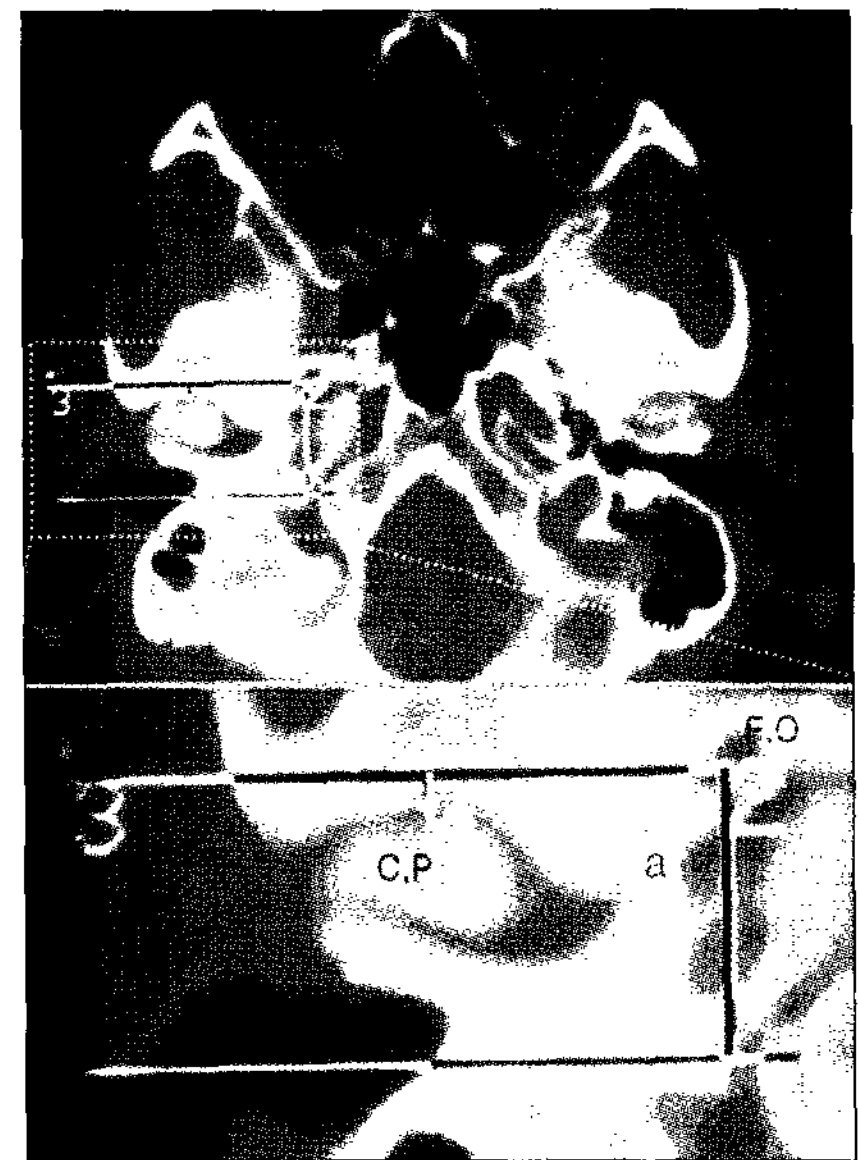


Fig. 2. Localization of zygomatic point (3: red point indicated by red arrow) by facial axial computed tomography using the orbitomeatal plane, a (1-2) : distance between external acoustic meatus and zygomatic point (3), b : distance between anterior margin of condylar process (4) and zygomatic point (3).

1.95 mm (16.3~24.1) and the average distance between the anterior margin of the condylar process of the mandible and the zygomatic point was Left : 4.27 ± 1.19 mm (2.0~7.0) Right : 4.31 ± 1.21 mm (1.0~7.0). The dimensions of the foramen ovale in both sex groups were Left : average length : 8.24 ± 0.63 mm (6.9~9.5), width : 4.01 ± 0.72 mm (2.5~5.6) Right : average length 8.11 ± 0.97 mm (6.9~11.5), width : 4.12 ± 0.99 mm (2.5~5.7). The differences in these measurements between right and left were not statistically meaningful (p value >0.05).

Table 1. Morphometric analysis of measurements of foramen ovale and localization of zygomatic point in relation with external acoustic meatus and condylar process of mandible in 67 patients (All results are expressed with mean \pm standard deviation)

	EAM-ZP	Condy-ZP	FO Length	FO width
Male				
Right	21.76 ± 2.06	4.33 ± 1.28	8.24 ± 0.56	4.09 ± 1.01
Left	21.71 ± 2.02	4.33 ± 1.26	8.32 ± 0.55	4.02 ± 0.61
Female				
Right	21.42 ± 1.80	4.29 ± 1.12	7.93 ± 0.72	4.16 ± 0.97
Left	21.56 ± 2.12	4.18 ± 1.09	8.13 ± 0.73	4.00 ± 0.86
Average				
Right	21.62 ± 1.95	4.31 ± 1.20	8.11 ± 0.97	4.12 ± 0.99
Left	21.65 ± 2.05	4.27 ± 1.19	8.24 ± 0.64	4.01 ± 0.72
Average in total	21.64 ± 1.99	4.29 ± 1.19	8.18 ± 0.82	4.06 ± 0.86

Length(mm) : Mean \pm Standard deviation, EAM-ZP : Distance between external acoustic meatus and zygomatic point, Condy-ZP : Distance between anterior margin of condylar process and zygomatic point, FO : Foramen Ovale

Sex differences

The average distance between the external acoustic meatus and the zygomatic point in males was Left : 21.71 ± 2.02 mm (17.2~15.0) Right : 21.76 ± 2.06 mm (15.7~25.0) and the average distance between the anterior margin of the condylar process of the mandible and the zygomatic point was Left : 4.33 ± 1.26 mm(1.2~6.9) Right : 4.33 ± 1.28 mm(3.1~6.0). And the average distance between the external acoustic meatus and the zygomatic point in females was Left : 21.56 ± 2.12 mm (17.7~24.0) Right : 21.42 ± 1.80 mm(16.3~25.0) and the average distance between the anterior margin of the condylar process of the mandible and the zygomatic point was Left : 4.17 ± 1.09 mm (3.1~6.0) Right : 4.28 ± 1.11 mm(2.9~6.9). The dimensions of the foramen ovale in males were Left : average length : 8.33 ± 0.55 mm(7.0~9.1), width : 4.02 ± 0.61 mm(2.5~5.3) Right : average length 8.24 ± 1.11 mm(6.7~11.5), width : 4.09 ± 1.01 mm (2.5~7.0). The dimensions of the foramen ovale in females were Left : average length : 8.13 ± 0.73 mm(6.9~9.5), width : 3.99 ± 0.86 mm(2.7~5.6) Right : average length 7.93 ± 0.72 mm(6.7~8.9), width : 4.16 ± 0.97 mm(2.7~5.3). But the differences of these measurements between men and women were not statistically meaningful (p value >0.05).

Discussion

From the exocranial aspect the foramen ovale is found at the base of the lateral pterygoid plate, anteromedial to the sphenoid spine and foramen spinosum^{1,3,8}. The transverse line of the foramen ovale passes through the zygomatic articular tubercle anterior to the joint space of the condylar process of the mandible. From the lateral aspect of the skull, this is located on the zygomatic arch adjacent to the condylar process on the orbitomeatal line. If this line were continued, the exit point on the cheek would be between the maxillary tuberosity immediately behind the last molar and the ascending ramus of the mandible. The zygomatic point that is a skin marker over the ipsilateral zygoma approximates the lateral projection of a straight line joining the centers of the two foramen ovale^{1,4,12}. According to the Penman¹², the zygomatic point is located 2.5cm from the center of the external auditory meatus. It is defined as the point at which a straight line joining the centers of the two foramen ovale, when reproduced, will pass through the skin on the side of the face. Concerning the location of the zygomatic point in correlation with the external auditory meatus, Nugent⁷ & Rovit et al.⁸ placed this point at 2.5cm anterior to the external auditory meatus on the orbitomeatal line, and Tew et al.¹⁰ placed it at 3cm anterior to it. In our study, the average distance between the center of the external acoustic meatus and the zygomatic point was Left : 21.65×2.05 mm Right : 21.62×1.95 mm which is shorter than the

average for Western people, which is 25~30mm. Linderoth et al.⁵ stated that the distance from the anterior margin of the condylar process of the mandible to the center of the foramen ovale was about 5mm, but in our study it was 4.3mm. In addition, the size and shape of the foramen ovale vary considerably, but measurements of the foramen in skulls averaged $3\sim4 \times 4\sim8$ mm (range, $1\sim6 \times 5\sim10$ mm) in other studies⁹. In our study, the size averaged 4.3×8.2 mm(range, $2\sim6 \times 5\sim10$ mm). But, we think that the size of the foramen ovale sectioned at the level of the orbitomeatal line on the 2-dimensional CT could be different from the real size of the foramen ovale. The measurement of the actual size of the foramen ovale would be correct if it was measured at the biggest area seen on the 3-dimensional volumetric CT.

The skin landmarks of the Hartel's method are generally used for the penetration of the foramen ovale. Three anatomic landmarks are chosen on the face. They are 1) the cheek point, located 2.5~3cm lateral to the oral commissure which is the point of needle penetration. The directions of the needle are laterally toward 2) the zygomatic point which is anterior to the external auditory meatus and medially toward 3) the pupil point^{6,8,11}.

In the penetrating procedure of the foramen ovale, it is important to seek the location of the foramen ovale precisely using skin markers and image intensifier^{3,6,8,11}. Sometimes, the procedure doesn't succeed due to the failure to penetrate the foramen ovale, and the structures around the foramen ovale can be injured. Around the foramen ovale there are foramen rotundum, foramen lacerum, foramen spinosum, foramen of Vesalius, and the innominate canal of Arnold. Penetration of these structures can cause hemorrhage in the temporal lobe of the brain⁸. Also it can be difficult to penetrate the foramen ovale due to its reduced size in case of Paget's disease or osteopetrosis which cause the structural deformity of the skull base². Thus, it would be quite helpful if we understand the exact location of the foramen ovale, its surrounding structures, and their anatomical configuration in advance of the intervention. In addition to that, we should also note that location of the zygomatic point in Korean adults differs from those in adults in Western countries.

Conclusion

The authors measured the size of the foramen ovale and the distance between the external acoustic meatus and the zygomatic point and the distance between the anterior margin of condylar process of mandible and zygomatic point in 67 patients with idiopathic classic trigeminal neuralgia who underwent facial axial CT for about 3 years. The average distance between the external acoustic meatus and the zygomatic

point was Left : 21.65 ± 2.05 mm Right : 21.62 ± 1.95 mm which is shorter than the average for Western people, which is 25~30mm and the average distance of the anterior margin of the condylar process of the mandible to the zygomatic point was Left : 4.27 ± 1.19 Right : 4.31 ± 1.21 . The dimensions of the foramen ovale in both sex groups were Left : $8.24 \pm 0.63 \times 4.01 \pm 0.72$ mm Right : length $8.11 \pm 0.97 \times 4.12 \pm 0.99$ mm. These anatomical understandings, including the size of the foramen ovale and localization of the zygomatic point could be helpful in determining the plan of percutaneous approaches to the foramen ovale. Additionally, we should also take it into account that the location of the zygomatic point in Korean adults differs from that in adults in Western countries.

• Acknowledgement

This work was presented as a oral presentation at the spring meeting of Korean Neurological Society in 2002.

References

1. Anderson JE : *Grant's Atlas of Anatomy*, ed 7. : Williams & Wilkins, 1978, pp9-51
2. Kim JS, Lee MK, Bae GH, Lee YH, Kim DJ : Trigeminal neuralgia in a patient with osteoporosis. *J Korean Neurosurg Soc* 27 : 1147-1151, 1998
3. Laitinen LL : Trigeminal stereoguide : an instrument for stereotactic approach through the foramen ovale and foramen jugulare. *Surg Neurol* 22 : 519-523, 1984
4. Leblanc A : *The Cranial Nerves*, ed 2. : Springer, 1995, pp135-153
5. Linderoth B, Hakanson S : Retrogasserian glycerol rhizolysis in trigeminal neuralgia in Schmidek HH, Sweet HH(eds). *Operative Neurosurgical Techniques, Indications, Methods, and Results*, ed 4. Philadelphia : Saunders, 2000, Vol 2, pp1552-1559
6. Nugent GR : Trigeminal Neuralgia : Treatment by percutaneous electrocoagulation in Wilkins RH, Rengachary SS(eds). *Neurosurgery*, ed 2. McGraw-Hill, 1996, Vol 3, pp3945-3951
7. Nugent GR, Berry B : Trigeminal neuralgia treated by differential percutaneous radiofrequency coagulation of the gasserian ganglion. *J Neurosurg* 40 : 517-523, 1974
8. Rovit RL : Percutaneous radiofrequency thermal coagulation of the gasserian ganglion, in Rovit RL, Murali R, Jannetta PJ(eds). *Trigeminal Neuralgia*. Baltimore : Williams & Wilkins, 1990, pp109-136
9. Sondheimer FK : Basal foramina and canals in Newton TH and Potts DG(eds). *Radiology of the Skull and Brain* : Mosby, 1971, Vol 1, pp287-347
10. Tew JM, Keller JT : The treatment of trigeminal neuralgia by percutaneous radiofrequency technique. *Clin Neurosurg* 24 : 557-578, 1977
11. Tew JM, Taha JM : Treatment of trigeminal and other facial neuralgias by percutaneous techniques in Youmans JR(ed). *Neurological Surgery*, ed 4. Philadelphia : Saunders, 1996, Vol 5, pp3386-3403
12. Penman J : Some developments in the technique of trigeminal injection. *Lancet* 1 : 760-764, 1953

Commentary

The authors studied on the site of the preauricular landmark when they punctured the foramen ovale in Korean patients with trigeminal neuralgia. According to Hartel's technique, the preauricular landmark is 3.0cm anterior to the external auditory meatus.

The authors localized the preauricular landmark measuring the distance from center of the external auditory meatus to the extended line of the inter-foramen ovale line on the axial scan of facial CT. According to their study, the average distance was 21.64 ± 1.99 mm and the localization of the preauricular landmark was 21.64 ± 1.99 mm anterior to the external auditory meatus.

The authors also measured the distance from anterior margin of condylar process of mandible to the extended inter-foramen ovale line. This is useful data when we puncture the foramen ovale under lateral fluoroscopic control. This paper is important in the sense that we can have a surgico-anatomical data in Korean patients, too. In this paper all the distances or lengths were counted very accurately in millimeters and we need more details of methods such as how to decide the center of the external acoustic meatus and so on.

Sang Sup Chung, M.D.

Pochon CHA University College of Medicine,
Bundang CHA Hospital