

Treatment Strategy of Multiple Hemangioblastomas

Eui Hyun Kim, M.D., Yong Sook Park, M.D., Jong Hee Chang, M.D., Ph.D.,
Jin Woo Chang, M.D., Ph.D., Yong Gou Park, M.D., Ph.D.

Department of Neurosurgery, Yonsei University College of Medicine, Seoul, Korea

Objective : Hemangioblastomas are highly vascular and benign neoplasm of the central nervous system(CNS). They can often be found as multiple lesions, as is commonly observed in von Hippel-Lindau(VHL) disease. The aim of this study is to determine the proper management for multiple hemangioblastomas.

Methods : Since 1990, 78cases of hemangioblastoma have been encountered. Among these, 9cases were multiple hemangioblastomas that were treated with surgical resection with or without radiosurgery. The medical, radiological, surgical and histological records were reviewed retrospectively and analyzed statistically.

Results : Nine patients presented with multiple hemangioblastomas and were diagnosed as VHL disease. The mean follow-up duration was 75.7months (6.6~159.2months) after the first surgical treatment. Three patients were treated with surgical resection alone and six patients were treated by both surgical resection and radiosurgery. Twenty-one surgical procedures (13 surgical resections and 8 radiosurgery) were performed. One patient required ventriculoperitoneal shunt and a posterior fossa decompressive craniectomy because of post-radiation brain swelling. Another patient refused additional treatment for the newly developed lesions after the successful treatment of initial lesions. The other patient who presented with numerous lesions in the whole brain and spine underwent cranio-spinal irradiation. Remaining patients showed good results.

Conclusion : The surgical outcomes for the patients with a single lesion of the CNS hemangioblastoma are favorable. However, the treatment of multiple hemangioblastoma is more difficult, and should be treated by surgical resection and radiosurgery with careful consideration.

KEY WORDS : Multiple hemangioblastomas · Posterior cranial fossa · Surgical resection · Radiosurgery.

Introduction

Hemangioblastomas of the central nervous system(CNS) are highly vascular, benign, and well-circumscribed solid or cystic neoplasms, which constitute 1% to 2.5% of all intracranial neoplasms^{10,11,17}. They are predominantly located in the cerebellum, but can also be found in other regions of the CNS. Hemangioblastomas can present as sporadic lesions or as manifestations of von Hippel-Lindau(VHL) disease, which is an autosomal dominant hereditary disease characterized by the neoplasm arising in multiple organs including the eye, kidneys, pancreas, adrenal glands, epididymis and the CNS^{7,11}. They are histologically benign and grow slowly. However, they can cause significant morbidity and mortality as a result of a mass effect on the nearby structures^{3,10}. They are often multiple, as is commonly encountered in VHL disease. In addition, multiple lesions are serious because they occur in the narrow space of the posterior fossa. The treatment of

choice for hemangioblastomas is a total surgical resection, and radiosurgery can be an alternative or adjuvant treatment modality^{1,6,12}. In this study, we reviewed the experiences about the management of multiple hemangioblastomas in posterior fossa which were treated by surgery and radiosurgery.

Materials and Methods

Patient selection

Seventy-eight CNS hemangioblastoma patients were treated in our hospital from January 1990 to June 2004. A single CNS lesion or multiple spinal cord lesions were excluded. Then nine patients who had multiple tumors in the posterior cranial fossa were reviewed retrospectively. A total of 87 lesions were treated. All the patients were diagnosed as VHL disease due to multiple CNS hemangioblastomas^{7,8}. There were five men and four women with a mean age of 40.0years (19~53years). A surgical resection was performed for all patients and the

• Received : January 31, 2005 • Accepted : April 27, 2005

• Address for reprints : Yong Gou Park, M.D., Department of Neurosurgery, Yonsei University College of Medicine, 134 Sinchon-dong, Seodaemun-gu, Seoul 120-749, Korea Tel : +82-2-361-5625, Fax : +82-2-393-9979, E-mail : ygpark@yumc.yonsei.ac.kr

pathology was demonstrated to be a hemangioblastoma. Magnetic resonance(MR) imaging was available for all the patients, and the mean follow up duration was 75.7months (6.6~159.2months).

Surgical resection

A total of 16 lesions were treated with surgical resection. The lateral suboccipital approach or midline suboccipital approach was used. Four patients underwent two times of surgical resections.

radiosurgery

A total of 81 lesions were treated with Gamma Knife radiosurgery (GKS, 201-source cobalt-60 gamma unit, Elekta Instruments), and each patient had a mean number of 13.5 lesions (2~19). All the patients had been treated with a surgical resection for the largest cystic or solid masses prior to radiosurgery. Each lesion volume varied from 4.1 to 5500mm³ (mean 338.9mm³). The mean dose delivered to the tumor margin was 16.7Gy(12.8~29.75Gy) and the isodose margin varied from 40% to 95% (mean 60.2%).

Results

Seven patients were manifested as multiple lesions from the initial diagnosis. In one patient, all three lesions were resected by first surgery (Case 3). However, the other six patients required additional treatment due to the residual tumors. One patient refused additional treatment (Case 4). One patient who already had lower cranial nerve deficits died from aspiration pneumonia 8years after the first surgery (Case 5). One patient showed leptomeningeal dissemination into the intracranial

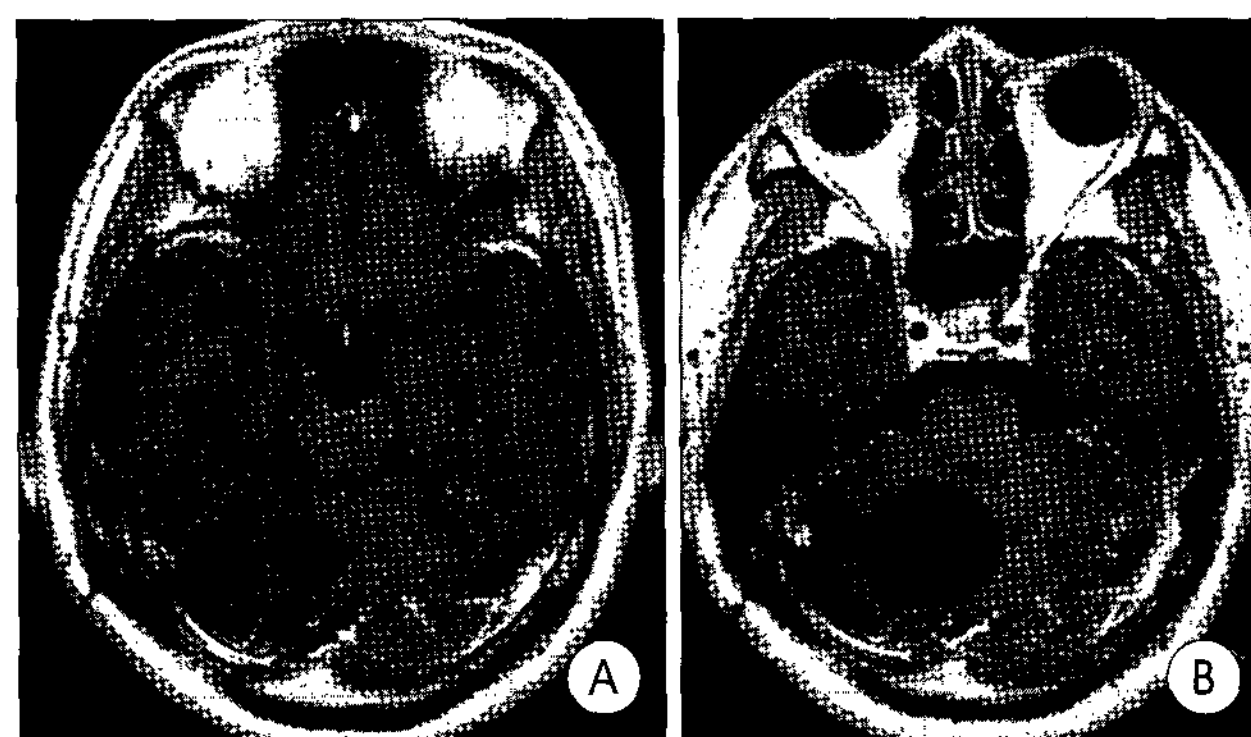


Fig. 1. Case 7 : Axial gadolinium enhanced T1 weighted magnetic resonance(MR) images. Pre-radiosurgical MR images(A) showing a small cystic tumor in the right cerebellar hemisphere. Post-radiosurgical MR images(B) 29months after the radiosurgery showing the enlargement of tumor.

and spinal subarachnoid space 8years after the complete resection of a solitary cerebellar hemangioblastoma (Case 8). This patient was treated with craniospinal irradiation. Two patients were treated twice with radiosurgery and one of these two patients suffered from delayed radiation induced complications and required posterior fossa decompression and ventriculoperitoneal shunt (Case 6). The treatment methods and its results are summarized in Table 1.

Surgical resection

A total of 13 procedures were performed on nine patients with multiple hemangioblastomas in the posterior cranial fossa. A total of 16 lesions were treated with a surgical resection. Ten lesions were resected subtotally and required additional radiosurgery. Six lesions were controlled by the first surgery. Only one patient with 3 lesions at the initial diagnosis could be cured by the first surgery, and this patient has been reviewed in an outpatient clinic for 56.3months without a recurrence (Case 3).

Radiosurgical response

Among the total 81 lesions treated by radiosurgery, 10 lesions were post-operative remnants, 2 lesions were mainly cystic and the others were all small solid tumors. Seventy-nine lesions out of 81 lesions were controlled, which means that the lesions were disappeared (complete response, 3.8%) or shrunk (partial response, 6.3%) or unchanged (stable, 89.9%). Only two lesions failed to be controlled. One lesion was a post-operative remnant that was part of an initially symptomatic

Table 1. Summary of treatments and results for multiple hemangioblastomas

Case No.	Age/sex	Surgical resection	GKS*			Follow-up (month)	Results
			Lesion No.	Volume (mm ³) [†]	Dose (Gy) [‡]		
1	40/M	1+1**	6	1570	14.0	154.3	Controlled
2	45/M	1	6	1067	19.8	33.0	Controlled
3	45/M	3	-	-	-	56.3	Controlled
4	34/F	1	-	-	-	6.6	Residual tumors Refusal of treatment
5	31/F	1+1**	2	2539	14.5	91.5	Controlled died (aspiration pneumonia)
6	22/F	1+1**	14+17***	54	17.5	77.8	1 surgical remnant - GKS failure Radiation induced complication
7	19/M	1+2**	7+10***	221	17.7	159.2	1 cyst - GKS failure Controlled
8	45/F	1	-	-	-	96.1	Leptomeningeal seeding Cranio-spinal irradiation
9	18/M	1	19	59	16.6	6.7	Controlled

*GKS : gamma knife radiosurgery, **Surgical resection in twice and the number of resected lesions, ***GKS in twice and the number of treated lesions, † The volume of multiple tumors are mean value, ‡ Marginal dose

large cyst with a volume of 340mm³ and was treated with a margin dose of 17.5Gy. This lesion eventually grew to a large cyst requiring an additional surgical resection. The other lesion was 1.8cm in diameter when radiosurgery was performed with a 50% margin dose of 17.4Gy. Twenty-nine months after the radiosurgery, the cyst had enlarged to 3.7cm in diameter and needed to be resected surgically (Fig. 1).

Illustrative Cases

Case 2

This 45-year-old male presented with headache in 2000,

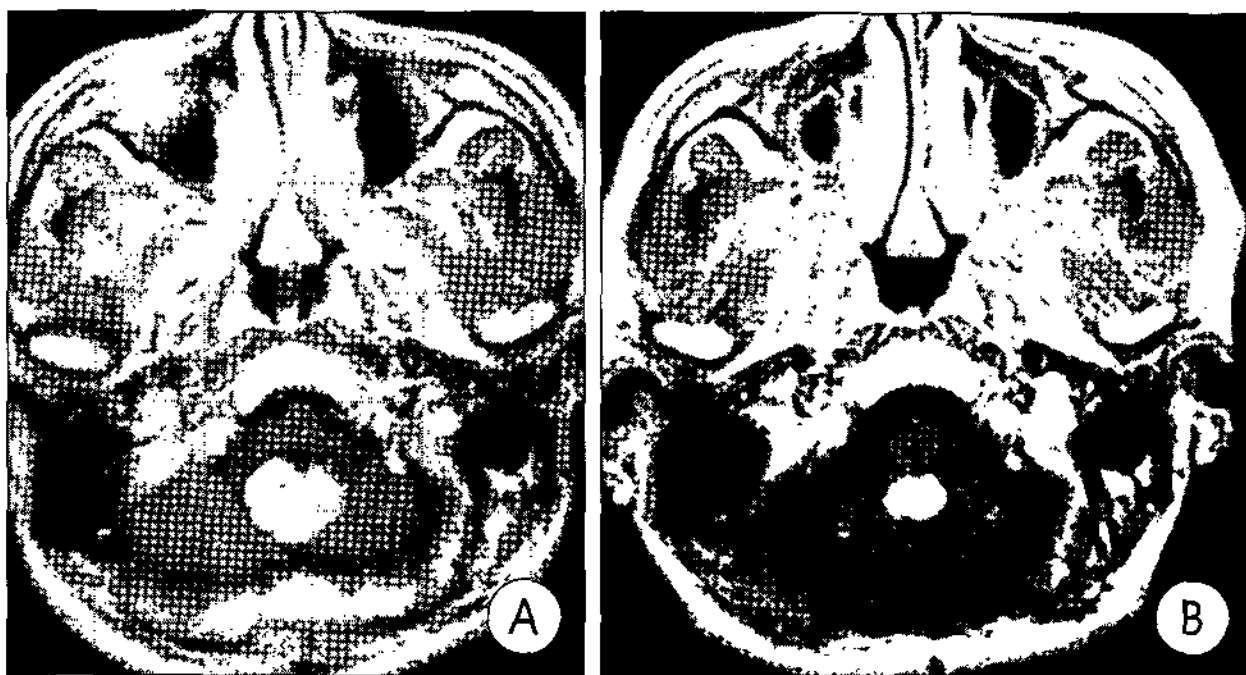


Fig. 2. Case 2 : Axial gadolinium enhanced T1 weighted magnetic resonance (MR) images. Preoperative MR images(A) showing multiple tumors in the cerebellar hemisphere and inferior vermis. Postoperative MR image(B) two years after radiosurgery showing that one is shrunken and another two unchanged.

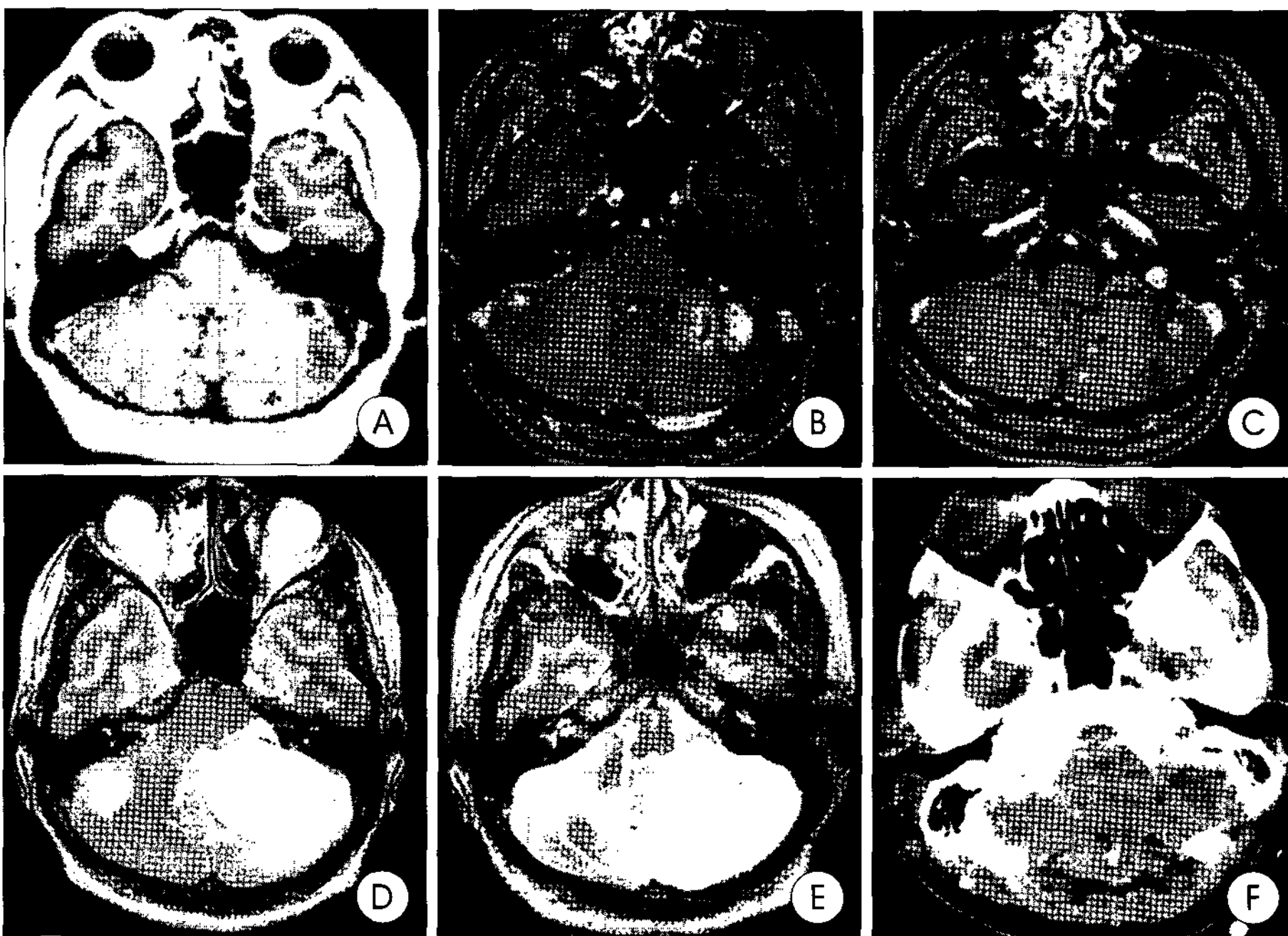


Fig. 3. Case 6 : Axial gadolinium enhanced T1 and T2 weighted magnetic resonance(MR) images and computed tomography(CT). A : MR images on the first radiosurgery showing multiple tumors in the cerebellum. B : MR images six years after the first radiosurgery showing a large cystic lesions in left cerebellum, which needed surgical resection later. C and D : MR images on the second radiosurgery showing the resolution of previously treated tumors but also newly developed tumors. E and F : MR images revealing severe cerebellar swelling, so decompressive craniectomy is performed eight months after the second radiosurgery.

and the MR imaging revealed 6 lesions in the posterior fossa. All the lesions were solid and one lesion was removed partially because the tumor was contacted to the brain stem. Including this surgical remnant, all six lesions were treated with radiosurgery 8months later. MR imaging was followed 2years after radiosurgery, which revealed that all lesions had shrunk or unchanged (Fig. 2). This patient has been reviewed in an outpatient clinic for 33months.

Case 6

A 22-year-old female patient showed 14 lesions in bilateral ce-rebellar hemisphere. Because of the scattered numerous lesions, she underwent a partial excision of the largest cystic hemangiobla-stoma, which was followed with GKS for 14 small tumors including one surgical remnant. The dose delivered to the tumor margin was 17.5Gy at a 70% isodose line. Six years after GKS, progressive headache and vomiting prompted her to visit the emergency room. MR imaging revealed a recurrent cystic lesion that measured 5.2cm in diameter, and there were new small and scattered lesions. The cyst was drained and the 16 countable lesions were treated by GKS at 70% isodose of 17.5Gy. At 6months after the second GKS, she revisited the emergency room due to vomiting and a change in her mental status. MR imaging demonstrated severe posterior fossa swelling and obstructive hydrocephalus. Decompression and

a ventriculoperitoneal shunt were performed. Six months after the decompression she was discharged from hospital. She could walk independently and take care of herself with assist. However, cerebellar ataxia and intermittent dizziness were still remained (Fig. 3).

Case 8

In 1995, a 45-year-old female presented with a solitary cerebellar mass. The tumor was resected completely and the pathology revealed a hemangioblastoma. Eight years later, in 2003, she developed headache and vomiting. An imaging study demonstrated multiple leptomeningeal seeding in the posterior cranial fossa and in the cervical, thoracic regions of the spinal cord (Fig. 4). She received cranio-spinal irradiation with a dose of 3600cGy to the whole spinal cord and 5940 cGy to the

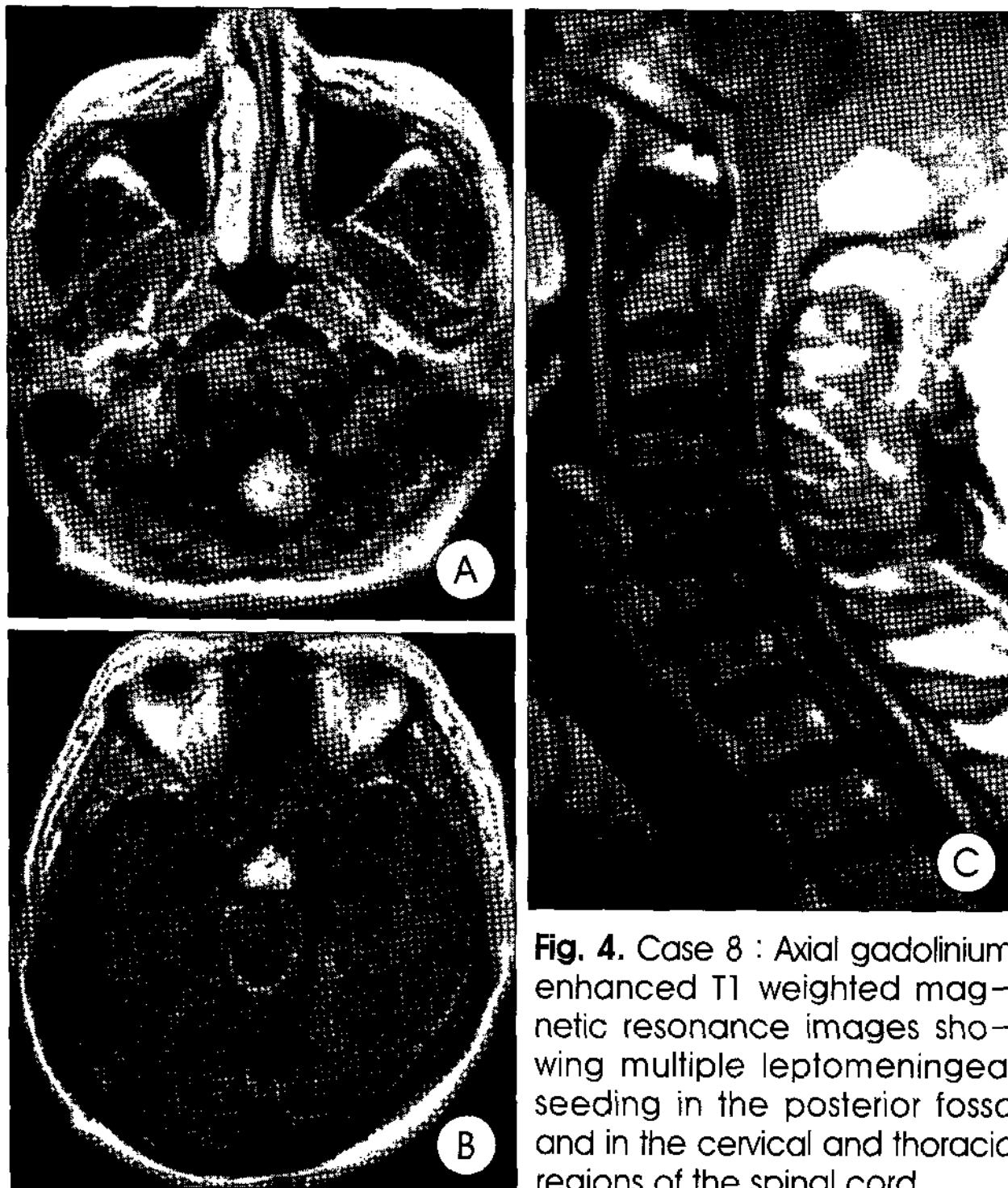


Fig. 4. Case 8 : Axial gadolinium enhanced T1 weighted magnetic resonance images showing multiple leptomeningeal seeding in the posterior fossa and in the cervical and thoracic regions of the spinal cord.

posterior fossa. She has been followed up in an outpatient clinic for 7 months.

Discussion

Hemangioblastomas show a tendency to develop at multiple sites in the CNS. In particular, these characteristics of multiplicity are very prominent in VHL disease. Moreover, these tumors usually grow progressively. Wanebo et al.¹⁸⁾ reviewed the serial MR imaging studies of 160 VHL disease patients with CNS tumors, and over a median of 32 months, 44% of tumors and 67% of the tumor-associated cysts were enlarged. There was no spontaneous regression or shrinkage of the tumor. Because most hemangioblastomas occur in the very narrow space of posterior cranial fossa, significant increase in the intracranial pressure and neurological deficit can developed. Therefore, these multiple lesions need to be treated actively in the early stage.

Surgical resection of hemangioblastoma

For solitary tumors, a gross total surgical resection results in excellent rates of control and has been the treatment of choice historically⁵⁾. However, a complete resection is difficult when there are more than one lesion. Among the 16 lesions treated with surgical resection, only six lesions were resected completely without recurrence. Surgical resection is preferable when the lesion was cystic. Niemela et al.¹²⁾ described the radiosurgical results of solid or cystic hemangioblastomas. Whereas all

the 10 solid lesions either shrank or were unchanged, 3 lesions of 5 adjoining cyst lesions needed to be evacuated after radiosurgery. Among the three cystic lesions treated with GKS in our series, two lesions could not be controlled and required a surgical resection, and one lesion showed no interval change. In the cases with large tumors, and so if they cause neurological symptoms or deficits, immediate surgical decompression is preferable.

Radiosurgery of hemangioblastoma

Although a surgical resection is the ideal treatment for hemangioblastomas, there are some limitations in treating multiple, progressive and recurrent hemangioblastomas, because extensive and repeated surgical exposures can cause cumulative neurological damage. Smalley et al.¹⁶⁾ reported the radiosurgical experience of 22 multiple hemangioblastomas in 7 patients. With a median volume of 965 mm³ (50~12000 mm³) and a median margin dose of 15.5 Gy (12~20 Gy), all lesions were controlled after a median follow-up of 24 months. Patrice et al.¹⁴⁾ reported an 86% local control rate at two years. In their reports, there was no local failure of lesions below 3 cc in volume, and they used a margin dose of 17 Gy or more on 35 tumors at a median follow-up of 24.5 months. Jawahar et al.⁴⁾ reported that 22 out of 29 lesions were controlled at a mean follow-up of 4 years. They emphasized that a smaller tumor volume and a higher dose (>18 Gy) were the significant affecting factors for a good outcome. In our current series, only two out of eighty one lesions failed to be controlled. The follow up duration of the patients who were treated with radiosurgery was 87.1 months (6.7~159.2 months). Compared with previous reports, the margin dose of 16.7 Gy is similar. However, the mean tumor volume of 11.3 mm³ was much smaller, which would lead to a good local control rate. Our current series had a relative large number of lesions in each patient, but they could also be controlled successfully due to the small tumor volume. Although there are multiple lesions in the narrow posterior cranial fossa, small lesions can be controlled if found in the early stage.

Multiple hemangioblastomas and post-radiation brain swelling

In 1993, Page et al.¹³⁾ reported a patient who was suffered from cerebellar edema due to radiation necrosis after radiosurgery. In this case, four lesions in the cerebellum were treated by radiosurgery with 35 Gy of a margin dose, and the patient required glucocorticoids medication and a ventriculoperitoneal shunt. In 1996, Niemela et al.¹²⁾ reported 11 cases that had been treated with radiosurgery. The median margin dose in the first 6 cases was 25 Gy and the median margin dose in the later 5 cases was only 10 Gy. One patient with two lesi-

ons received a margin dose of 25Gy and developed radiation edema 6months later. This patient required a ventriculoperitoneal shunt and prolonged corticosteroid medication. The authors suggested that a margin dose of 10 to 15Gy might be sufficient to shrink or control the solitary small or medium sized lesions. In case 6 from the present study, the margin dose was 17.5Gy but she had several risk factors for developing brain swelling; a large number of lesions (14+17), using a large diameter collimator (8mm) and two times of the radiosurgery procedures. Therefore, the proper margin dose alone is insufficient for preventing post-radiation brain swelling because the radiation field might have been overlapped due to the multiple radiation shots. The use of a small collimator may be helpful because it makes the dose gradient steeper. Through a regular follow-up imaging study and proper screening, an early diagnosis in the high-risk group must be made for early radiosurgical intervention before the tumors can grow.

Leptomeningeal hemangioblastomatosis

Mohan et al.⁹⁾ reported two cases of disseminated hemangioblastomatosis in 1976, who had multiple sites of subarachnoid dissemination and progressive growth with a poor outcome. These two patients had a history of a prior surgical resection of a solitary cerebellar hemangioblastoma, each 8 and 14years ago, and lacked the clinical or familial evidence of VHL disease. Reyns et al.¹⁵⁾ also reported a 51-year-old man with diffuse CNS hemangioblastomatosis that occurred after three times of surgical resection for recurrent solitary cerebellar hemangioblastoma. After 7years from the last surgery, he showed dissemination into the whole intracranial and spinal subarachnoid spaces and died 6months later. Weil et al.¹⁹⁾ presented four patients with no family history or clinical evidence of VHL disease in whom extensive, progressive, en plaque coating of the brain stem and spinal cord with hemangioblastomas developed 1 to 8years after the complete resection of a solitary cerebellar hemangioblastoma. Despite surgery, radiation therapy, and systemic drug therapy, these patients showed progressive clinical deterioration over the course of approximately 1 to 2years after presentation with recurrent tumors, even though the histological appearance was typical benign hemangioblastomas. The authors suggested that this syndrome appeared to result from the delayed growth of subarachnoid tumor cells disseminated by surgery and one or more other genes appeared to contribute to the unusual malignant behavior. In our case (Case 8), the patient also had a history of prior surgery, and the MR imaging study demonstrated multiple leptomeningeal seeding in the posterior fossa and in the cervical, thoracic regions of the spinal cord. There may be no difference between sporadic and VHL-associated tumors

with respect to dissemination^{2,8,19)}. Disseminated hemangioblastomatosis have a biological, clinical, and molecular genetic profile that is distinct from the hemangioblastomas associated with VHL disease^{9,15,19)}. Therefore, it should be treated as for different disease entity.

Conclusion

Hemangioblastomas are benign tumor histologically, which means that long life expectancy is expected. If treated by proper modalities with careful consideration, they can be controlled even if there are multiple lesions. Further research on a more targeted therapeutic modality is expected to advance the treatment of multiple hemangioblastomas.

References

1. Chang SD, Meisel JA, Hancock SL, Martin DP, McManus M, Adler JR Jr. : Treatment of hemangioblastomas in von Hippel-Lindau disease with linear accelerator-based radiosurgery. *Neurosurgery* 43 : 28-34, 1998
2. de la Monte SM, Horowitz SA : Hemangioblastomas : clinical and histopathological factors correlated with recurrence. *Neurosurgery* 25 : 695-698, 1989
3. Horton WA, Wong V, Eldridge R : Von Hippel-Lindau disease : Clinical and pathological manifestation in nine families with 50 affected members. *Arch Intern Med* 136 : 769-777, 1976
4. Jawahar A, Kondziolka D, Garces YI, Flickinger JC, Pollock BE, Lunsford LD : Stereotactic radiosurgery for hemangioblastomas of the brain. *Acta Neurochir (Wien)* 142 : 641-644, 2000
5. Jeffreys R : Clinical and surgical aspects of posterior fossa haemangioblastomata. *J Neurol Neurosurg Psychiatry* 38 : 105-111, 1975
6. Ko JH, Park BJ, Kim YJ, Cho MK : LINAC radiosurgery for hemangioblastoma. *J Korean Neurosurg Soc* 35 : 529-532, 2004
7. Lonser RR, Glenn GM, Walther M, Chew EY, Libutti SK, Linehan WM, et al : von Hippel-Lindau disease. *Lancet* 361 : 2059-2067, 2003
8. Melmon KL, Rosen SW : Lindau's disease. *Am J med* 36 : 595-617, 1964
9. Mohan J, Brownell B, Oppenheimer DR : Malignant spread of haemangioblastoma : report on two cases. *J Neurol Neurosurg Psychiatry* 39 : 515-525, 1976
10. Neumann HP, Eggert HR, Weigel K, Friedburg H, Wiestler OD, Schollmeyer P : Hemangioblastomas of the central nervous system : A 10-year study with special reference to von Hippel-Lindau syndrome. *J Neurosurg* 70 : 24-30, 1989
11. Neumann HP, Lips CJ, Hsia YE, Zbar B : Von Hippel-Lindau syndrome. *Brain Pathol* 5 : 181-193, 1995
12. Niemela M, Lim YJ, Soderman M, Jaaskelainen J, Lindquist C : Gamma knife radiosurgery in 11 hemangioblastomas. *J Neurosurg* 85 : 591-596, 1996
13. Page KA, Wayson K, Steinberg GK, Adler JR : Stereotaxic radiosurgical ablation : an alternative treatment for recurrent and multifocal hemangioblastomas. A report of four cases. *Surg Neurol* 40 : 424-428, 1993
14. Patrice SJ, Sneed PK, Flickinger JC, Shrieve DC, Pollock BE, Alexander E 3rd, et al : Radiosurgery for hemangioblastoma : results of a multiinstitutional experience. *Int J Radiat Oncol Biol Phys* 35 : 493-499, 1996
15. Reyns N, Assaker R, Louis E, Lejeune JP : Leptomeningeal hemangioblastomatosis in a case of von Hippel-Lindau disease : case report. *Neurosurgery* 52 : 1212-1216, 2003
16. Smalley SR, Schomberg PJ, Earle JD, Laws ER, Scheithauer BW, O'Fallon JR : Radiotherapeutic considerations in the treatment of hemangioblastomas of the central nervous system. *Int J Radiat Oncol Biol Phys* 18 : 1165-1171, 1990
17. Sora S, Ueki K, Saito N, Kawahara N, Shitara N, Kirino T : Incidence of von Hippel-Lindau disease in hemangioblastoma patients : the University of Tokyo Hospital experience from 1954-1998. *Acta Neurochir (Wien)*

143 : 893-896, 2001

18. Wanebo JE, Lonsler RR, Glenn GM, Oldfield EH : The natural history of hemangioblastomas of the central nervous system in patients with von Hippel-Lindau disease. *J Neurosurg* 98 : 82-94, 2003
19. Weil RJ, Vortmeyer AO, Zhuang Z, Pack SD, Theodore N, Erickson RK, et al : Clinical and molecular analysis of disseminated hemangioblastomatosis of the central nervous system in patients without von Hippel-Lindau disease. Report of four cases. *J Neurosurg* 96 : 775-787, 2002

Commentary

Multiple hemangioblastoma with von Hippel-Lindau (VHL) disease can be difficult to manage surgically alone as it differs from the solitary hemangioblastoma, which has led to an interest in applying of stereotactic radiosurgery.

The article provides information on retrospectively collective cases of multiple hemangioblastoma, guiding the treatment strategy what we have to handle them. This report present that they have treated nine patients with VHL disease, confined in posterior cranial fossa, and operated 16 lesions, and taken 81 lesions into the Gamma knife. After radiosurgery with mean follow time of 75.7 months, there was an excellent controlled rate in 79 of 81 lesions. However, authors have experienced two complicated patients, one is recurrent large cystic lesion with increased scattered lesions, and the other is multiple leptomeningeal seeding around posterior fossa and in spinal column as rarely reported.

Generally multiple hemangioblastoma is closely linked to VHL disease which has been investigated as germline mutation of the VHL tumor suppressor gene on chromosome three, region p

25~26 with an estimated incidence of one in 36,000 newborns. Patients with VHL disease are at risk of developing cerebellar, spinal and retinal hemangioblastoma, renal cell carcinoma, pheochromocytoma, pancreatic neuroendocrine tumors, pancreatic and renal cyst.

Hemangioblastoma in posterior cranial fossa, if presented in progress, induces rapid neurological deterioration in which encountered into rapid surgical resection of lesions as possible. In cases of multiple hemangioblastoma, although it revealed the growth phase and arrested quiescent phase in natural history, the lesions to be unable to remove surgically whether located near brain stem or scattered widely, would be manage in any measure because the lesion is going to grow progressively. It is necessary that an optimal clinical and radiological follow-up give a clue to appropriate treating strategy.

This paper in here present the local tumor control was achieved in majority of cases with radiosurgery following surgical removal with disclosing 79 of 81 lesions control in long term follow up duration of mean Six years. Radiosurgery is a useful palliative measure controlling multiple lesions on diagnosis or later in course, although further disease to develop or progressive intracranially is limited in its efficacy in these patients.

Young Soo Ha, M.D.
Kwandong University College of Medicine
Myongji Hospital