

The Effectiveness of Osteoplasty System (Vertebroplasty using Large Cannula-low Pressure Delivery System) in Compression Fracture and other Spinal Pathology

Jeong-Han Kang, M.D., Sung Uk Kuh, M.D., Zun-Zae Shin, M.D.,
Yong-Eun Cho, M.D., Young Sul Yoon, M.D., Dong-Kyu Chin, M.D.

Department of Neurosurgery, Yonsei University College of Medicine, Yongdong Severance Hospital, Seoul, Korea

Objective : The vertebroplasty is an excellent procedure in spine compression fracture, but there are some problems such as cement leakage and difficulties in bone biopsy. Recently, the osteoplasty system is developed to solve these problems, so we will report the usefulness of the osteoplasty system.

Methods : From January 2003 to November 2003, there are 9 patients with simple osteoporotic spine compression fracture, 2 compression fracture patients combined with suspicious spinal metastasis, 1 patient with suspicious primary bone tumor, and 2 patient with infection on spine. All patients were treated using the osteoplasty system.

Results : All 11 compression fracture patients were relieved the back pain after the osteoplasty and there is no complication. The bone biopsies in 3 suspicious cancer patients were also effectively performed using the osteoplasty system; negative result in 2 patients and positive result in 1 patient. The culture result of spontaneous discitis was no growth for 48 hours. The spine tuberculosis was confirmed using the osteoplasty system.

Conclusion : The osteoplasty system has distinguished advantages in comparison with the vertebroplasty. That is, the risk of cement leakage is lower than vertebroplasty because of low pressure delivery system. And we can obtain the specimen effectively in bone biopsy because of large cannula. In conclusion, we emphasize that the osteoplasty system is a more useful procedure in spine compression fracture especially in the patient needed bone biopsy for diagnosis.

KEY WORDS : Osteoplasty · Spinal metastasis · Compression fracture · Bone biopsy · Vertebroplasty.

Introduction

The vertebroplasty is a minimally invasive procedure that provide pain relief and spinal stability to vertebrae that have been structurally weakened by osteoporosis or tumor suspicious lesion¹⁾. It is an excellent therapeutic procedure involving percutaneous injection of polymethylmethacrylate (PMMA) cement to collapsed or tumor suspicious vertebral body under fluoroscopic guidance^{6,10,12)}.

The procedure can provide immediate palliative effectiveness to the patient who is suffering from underlying disease. Some papers reported that 80~90% of patients experienced partial or complete pain relief within 24 hours after the procedure^{1,4,6,9)}.

But there are some problems, which are local infection, cement leakage, embolic accident, and difficulty of pathologic bone biopsy^{3,5,6,8,11,13,15,17)}. The osteoplasty system that is vertebroplasty using large cannula-low pressure delivery system recently developed to solve some problems, especially in cement leakage and difficulty of bone biopsy. We evaluated the results of bone biopsy and vertebroplasty using the osteoplasty system in 14 cases.

Materials and Methods

Patients population

14 patients underwent the procedure of osteoplasty system

• Received : January 5, 2005 • Accepted : June 28, 2005

• Address for reprints : Sung Uk Kuh, M.D., Department of Neurosurgery, Yonsei University College of Medicine, Yongdong Severance Hospital, 146-92 Dogok-dong, Gangnam-gu, Seoul 135-270, Korea Tel : +82-2-3497-3397, Fax : +82-2-3461-9229, E-mail : kuhsu@yumc.yonsei.ac.kr

from January 2003 to November 2003 in our institute. There were 4men and 10women, and the mean age was 66.8year old(range, 44~89year old). There are 9patients of simple osteoporotic compression fracture, 6cases in L1 vertebra and each one case in T11, T12, and L3 vertebra. There are 3patients of suspicious malignant spinal tumor. 2 metastatic malignant tumor suspicious patients had a past medical history of stomach cancer and lung cancer, they are combined with spine compression fracture, the other one malignant tumor was thought to be primary tumor at the time of diagnosis. 2patient were suspicious of infection. The infection cases were thought to be spontaneous pyogenic discitis and spine tuberculosis(Table 1).

We performed vertebroplasty for compression fracture in 389 segments of 220patients before January 2003 in our institute. There were 33men and 187women. Mean age was 67.8year. We experienced spinal biopsy for 4 suspicious malignant lesion and 11 infection lesion by vertebroplasty needle from December 1999 to July 2002 in our institute. There were 8men and 7women, and mean age 54.1year old (range 20~85year old).

Surgical technique

The Osteoplasty is performed using fluoroscopically guided direct vertebral body access under a local anesthetic and conscious sedative in an operating room. The osteoplasty can be used in the extrapedicular or transpedicular approach. Because the extrapedicular approach give rise to severe pain when the guide-wire was advanced, we control the pain through local anesthesia and intravenous sedation.

The midline of the transverse process and the pedicle are identified and marked under fluoroscopy. In lumbar lesion, a parallel line laterally 8~10cm off the midline and a transverse line bisecting the transverse process are drawn. In thoracic lesion, a parallel line laterally 2~2.5cm off the midline are drawn. The inferior edge of the pedicle and soft tissue between the rib structure are identified using fluoroscopy or palpation. A punch incision is made with #15 blade at entry point. Under anterior-posterior fluoroscopy, the guide-wire is inserted until the tip of wire docks on the vertebral body. The guide-wire is advanced and verified to a depth of 50% of the vertebral body on lateral and anterior-posterior fluoroscopic view. Upon tra-

jectory confirmation, the guide-wire is advanced to a depth of 70% of the vertebral body on lateral fluoroscopic view and mid portion on anterior-posterior fluoroscopic view. After the placement of the guide-wire is confirmed, the guide-wire is replaced with the working cannula. The osteoplasty should be performed in this working cannula(Fig. 1). We used the CDO (controlled delivery for osteoplasty) system (Interpore Cross international Inc, Irvine, California), which has working cannula (diameter is 6.35mm) for the osteoplasty system.

Table 1. Summary of characteristics in patients received osteoplasty

Age/Sex	Diagnosis	Level	Procedure	Other disease
1 67/M	Compression Fx.	L1	Vertebroplasty	-
2 60/F	Compression Fx.	T12	Vertebroplasty	-
3 59/F	Compression Fx.	L1	Vertebroplasty	-
4 78/F	Compression Fx.	L1	Vertebroplasty	-
5 66/F	Compression Fx.	T11	Vertebroplasty	-
6 81/F	Compression Fx.	L3,(L4)	Vertebroplasty	-
7 64/M	Compression Fx.	L1	vertebroplasty	-
8 58/M	Compression Fx.	L1	vertebroplasty	-
9 69/M	Compression Fx.	(T12),L1	Vertebroplasty	-
10 79/M	Compression Fx.	L1	Vertebroplasty and Biopsy	Lung cancer
11 70/F	Compression Fx.	T8	Vertebroplasty and Biopsy	Stomach cancer
12 44/F	Tumor, Chordoma	S2, S3	Bone biopsy	-
13 89/F	Spondylodiscitis	L1/2, L4/5	Culture biopsy	-
14 52/F	Spine tuberculosis	L3,4	Culture biopsy	Pulmary tuberculosis

M : Male, F : Female, Fx.: Fracture, L: Lumbar, T: Thoracic, S: Sacrum, - : Absent, () : old fracture lesion

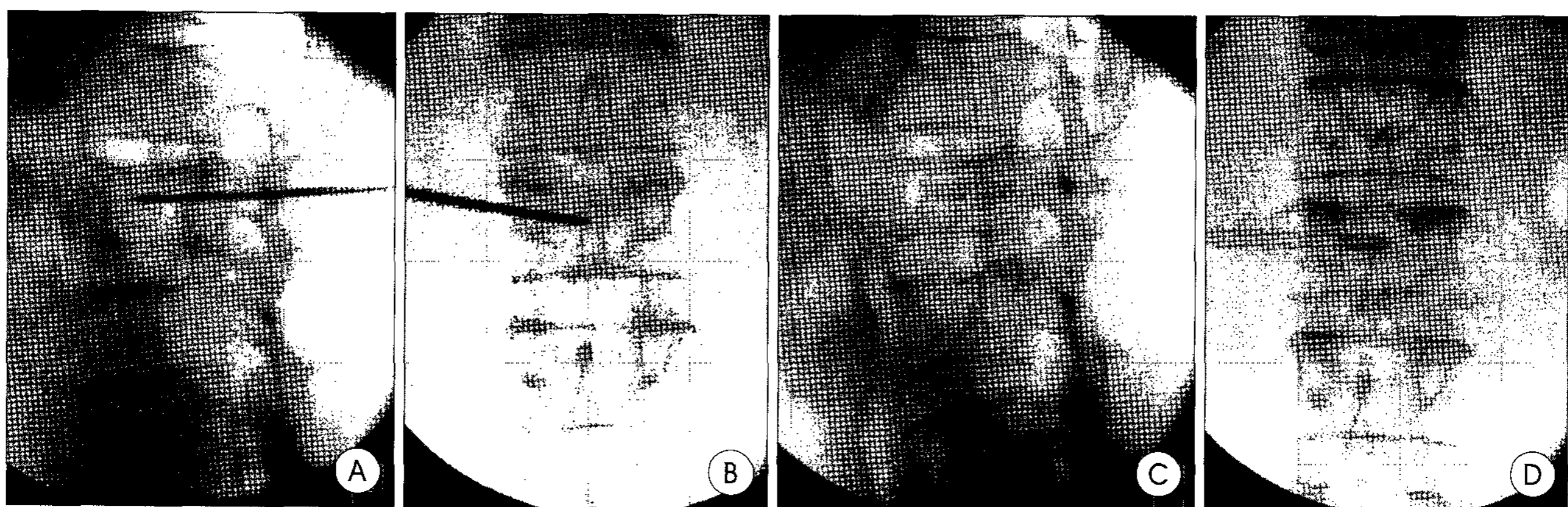


Fig. 1. Under fluoroscopic view, the guide-wire is inserted into the vertebral body. A : 70% of the body on lateral image, B : Mid-portion on antero-posterior image. C, D : Upon trajectory confirmation, the cannula of osteoplasty was advanced.

Results

The osteoplasty for 9 simple osteoporotic compression fracture cases and 2 suspicious metastasis compression fracture cases was performed. The pain was relieved in all 11 patients within 24 hours after this procedure. There was no complication such as cement leakage and embolic accident.

The osteoplasty system for bone biopsy of suspicious tumorous lesion was used in 3 patients, and it was performed in 2 patients for culture biopsy in spontaneous discitis lesion and spine tuberculosis.

A 79-year-old man had suffered from persistently severe low back pain for 1 month since he had a fit of coughing before medical consult. He had a past medical history of anti-cancer chemotherapy for lung cancer. He had no abnormal neurological findings. Magnetic resonance imaging (MRI) studies of thoracolumbar spine demonstrated anterior wedging compression deformity and decreased vertebral body height of

L1 vertebrae and low signal intensity at anterior vertebral body on T2 weighted image and low signal intensity on T1 weighted image, and slightly enhanced by gadolinium. Whole Body Bone Scan (WBBS) revealed hot uptake on L1 vertebrae (Fig. 2). The lesion was thought to be compression fracture, but we could not rule out the spine metastasis from lung cancer.

A 70-year-old woman was referred to our hospital due to continuous back pain for two months. She had a past medical history of stomach cancer and had been previously treated with gastrectomy and chemotherapy. On admission, she had no abnormal neurological findings. There was hot uptake on T8 and T9 vertebrae in WBBS study. T2 weighted sagittal MR imaging showed the lesion as heterogeneous signal. Enhanced sagittal MR image showed homogeneously increased signal intensity (Fig. 3). The lesion was highly suggestive of recent osteoporotic compression fracture, but we also could not rule out the spine metastasis from stomach cancer.

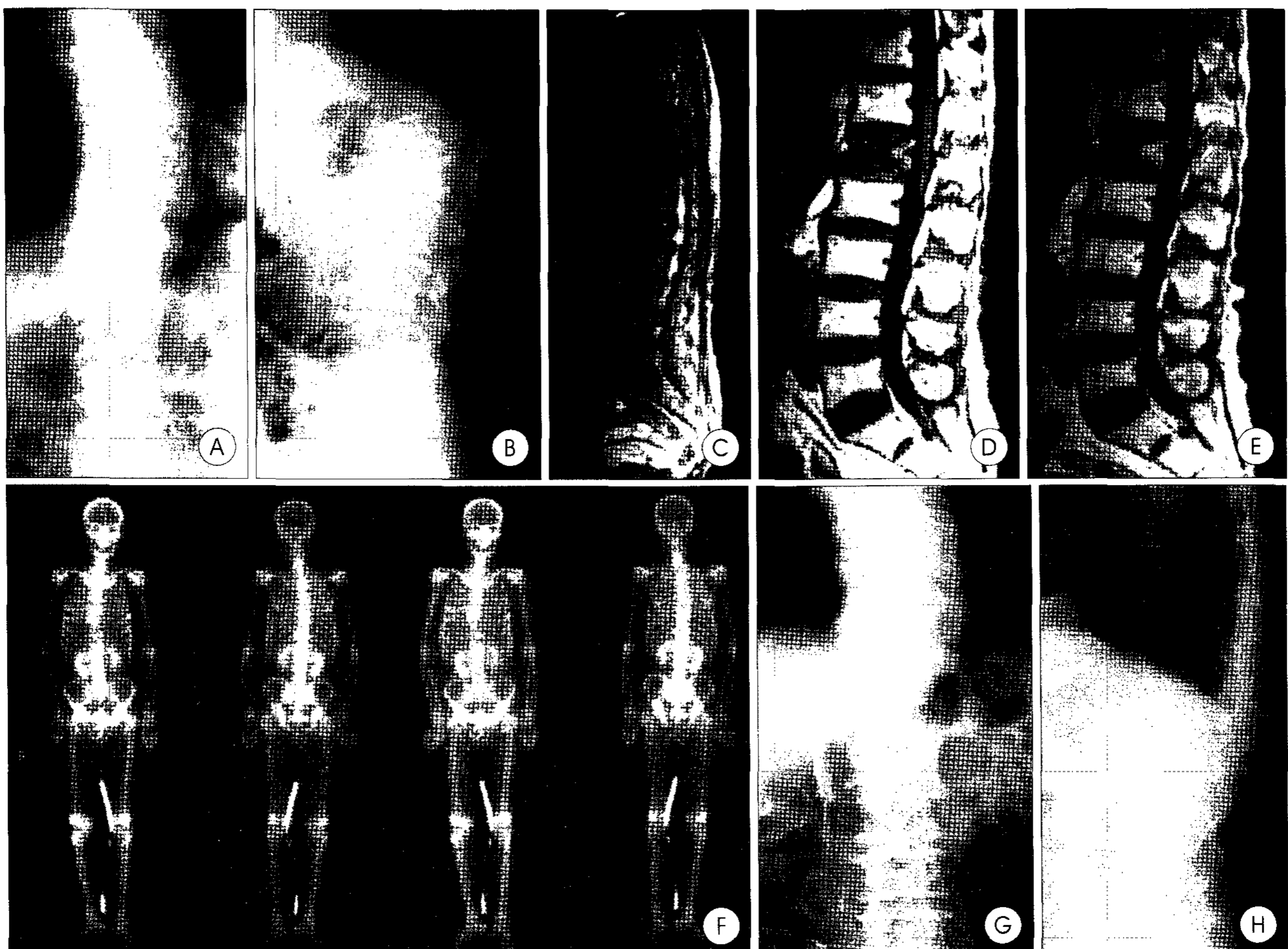


Fig. 2. A 79-year-old man has suffered from persistently severe low back pain for 1 month. He has a past history of lung cancer. A, B : On plain X-ray demonstrating anterior wedging compression deformity and decreased vertebral body height of L1. C, D, E : Magnetic resonance image demonstrating low signal intensity at anterior vertebral body on T2 weighted image, low signal intensity on T1 weighted image, and slightly enhanced by gadolinium enhanced magnetic resonance image. F : Whole Body Bone Scan (WBBS) showing hot uptake on L1. G, H : Post operative X-ray.

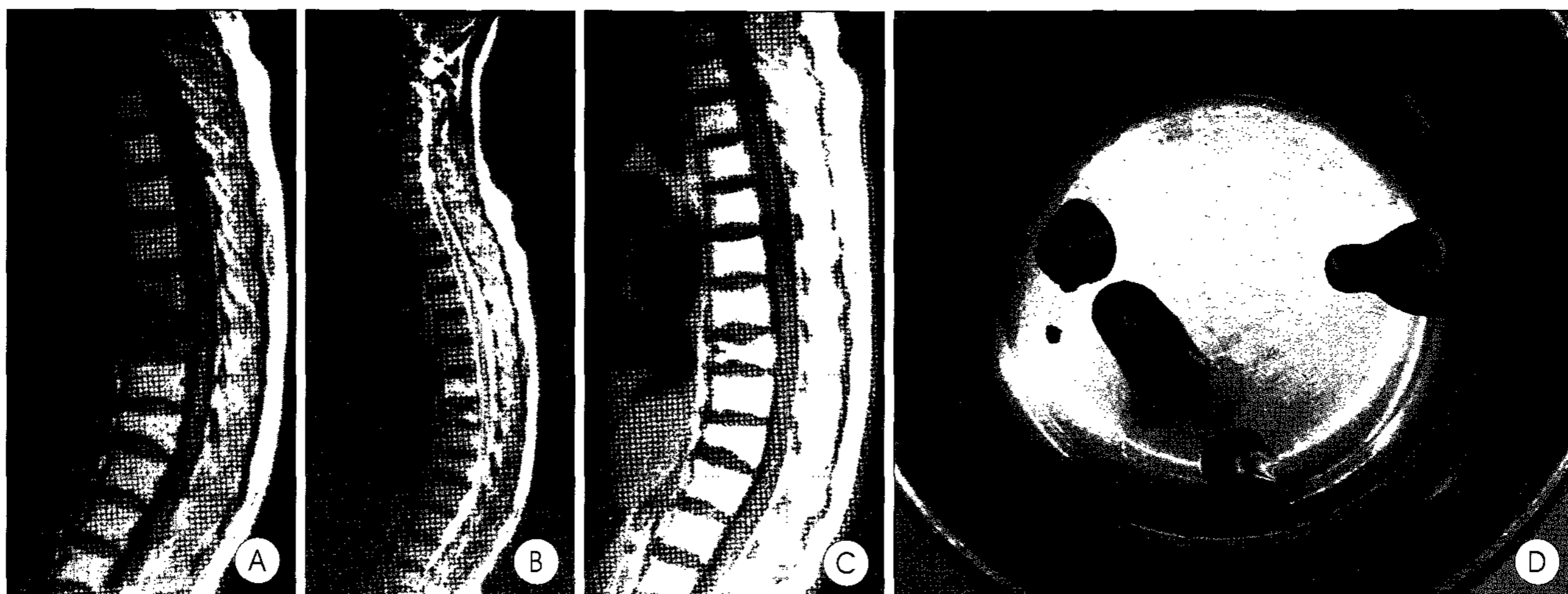


Fig. 3. A 70-year-old woman is referred to our hospital due to continuous back pain for two months. She has a past medical history of stomach cancer. A : T1 weighted sagittal magnetic resonance image showing the lesion as low signal. B : T2 weighted sagittal magnetic resonance image showing the lesion as hetero-geneous signal. C : Gadolinium enhanced sagittal image showing diffuse homogeneously increased signal intensity. D : Bone biopsy specimen.

A 49-year-old woman was admitted to our hospital with a history of mild low back pain for 1 month. It revealed severe direct tenderness at sacral area on physical examination, but she had no abnormal neurological findings. It revealed huge sacral mass measuring 5×7×7cm in the sacrum on contrast enhanced computed tomography. The mass contained soft tissue and focal area of calcification. Magnetic resonance imaging(MRI) study demonstrated multi-lobulated iso-signal on T2 weighted image and slightly low signal mass lesion on T1 weighted image in S2-S3. The T1 weighted MRI with gadolinium enhanced confirmed strong enhancing tumor lesion(Fig. 4). The findings on imaging studies were compatible with chordoma on sacrum. We tried bone biopsy for confirmative diagnosis and proper management.

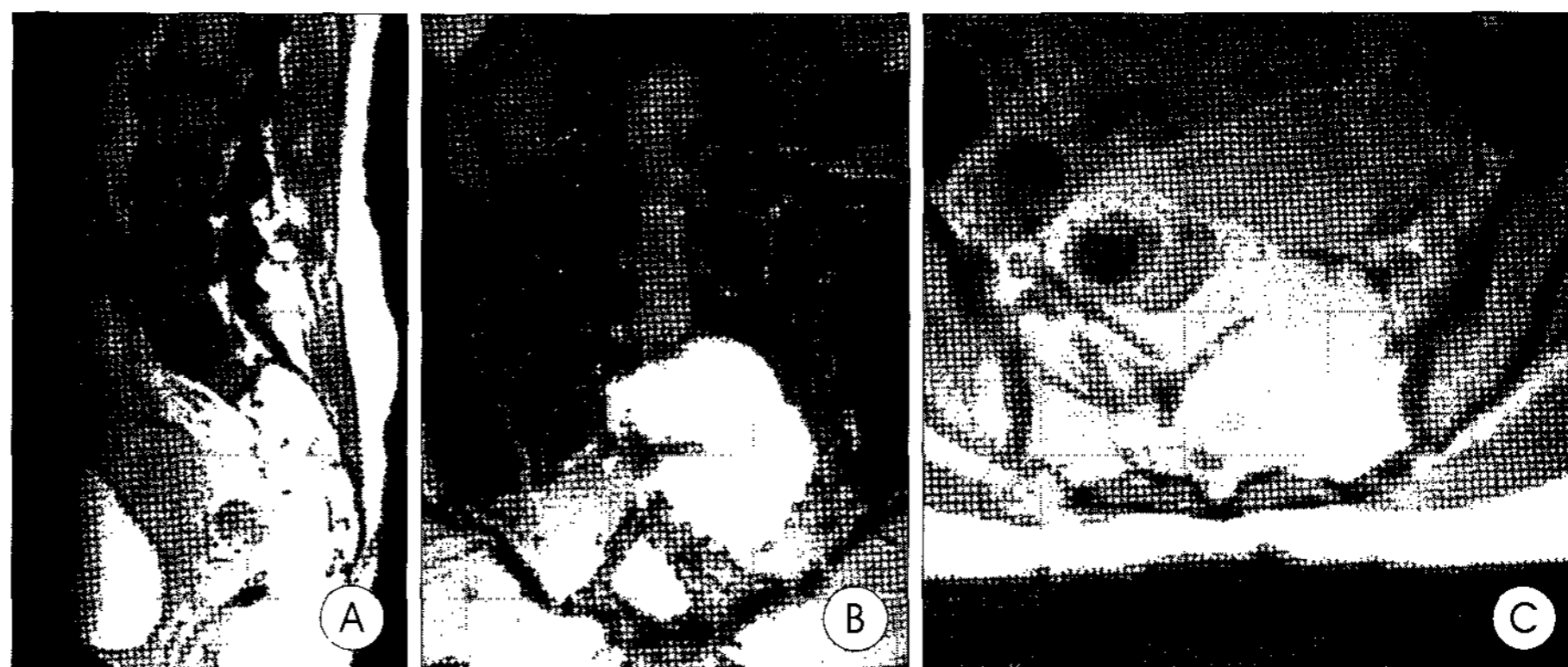


Fig. 4. A 49-year-old woman is admitted to our hospital with a history of mild lower back pain for 1 month. A, B, C : The gadolinium enhanced sagittal, coronal, and axial magnetic resonance images reveal strong enhancing tumor mass lesion on the 2nd and 3rd sacrum area.

A 89-year-old woman presented to our hospital with low back pain and right side sciatic pain for 1 month. She had been taken the acupuncture for intermittent back pain. On admission, Spinal MR study revealed unusual bright signal intensity on L1/2 and L4/5 disc space on T2 weighted MR imaging and also low signal intensity of L1 vertebral body on T1 weighted MR imaging, but this lesion was not enhanced with gadolinium. We assumed that the lesion was pyogenic spondylodiscitis and we did percutaneous culture biopsy using osteoplasty system to figure out the proper antibiotics(Fig. 5).

A 52-year-old woman was admitted to our hospital due to continuous back pain for one month. She had a past medical

history of pulmonary tuberculosis and had been previously treated with anti-tuberculosis medication. On admission, she had no abnormal neurological findings. It revealed high-signal intensity on L3 and L4 vertebral body on T2 weighted MR image and also it was enhanced with gadolinium. The lesion was highly suggestive of spinal tuberculosis. We tried to do the bone biopsy for confirmative diagnosis.

We obtained large amounts of specimen for the pathologic diagnosis in 3 tumor and 2 infection suspicious lesions and also we could vertebroplasty in 2 metastatic tumor suspicious patients using this osteoplasty system. But they had no evidence of spinal metastasis in bone biopsy result, so we did not need more treatment and planed to follow up them. We can confirm the malignant tumor cell using the osteoplasty in chordoma suspicious patient, so, she took the irradiation therapy for the chordoma. The culture result of discitis suspicious lesion was no growth for 48hours, because she took the long-term antibiotic treatment before in other hospital, even though we

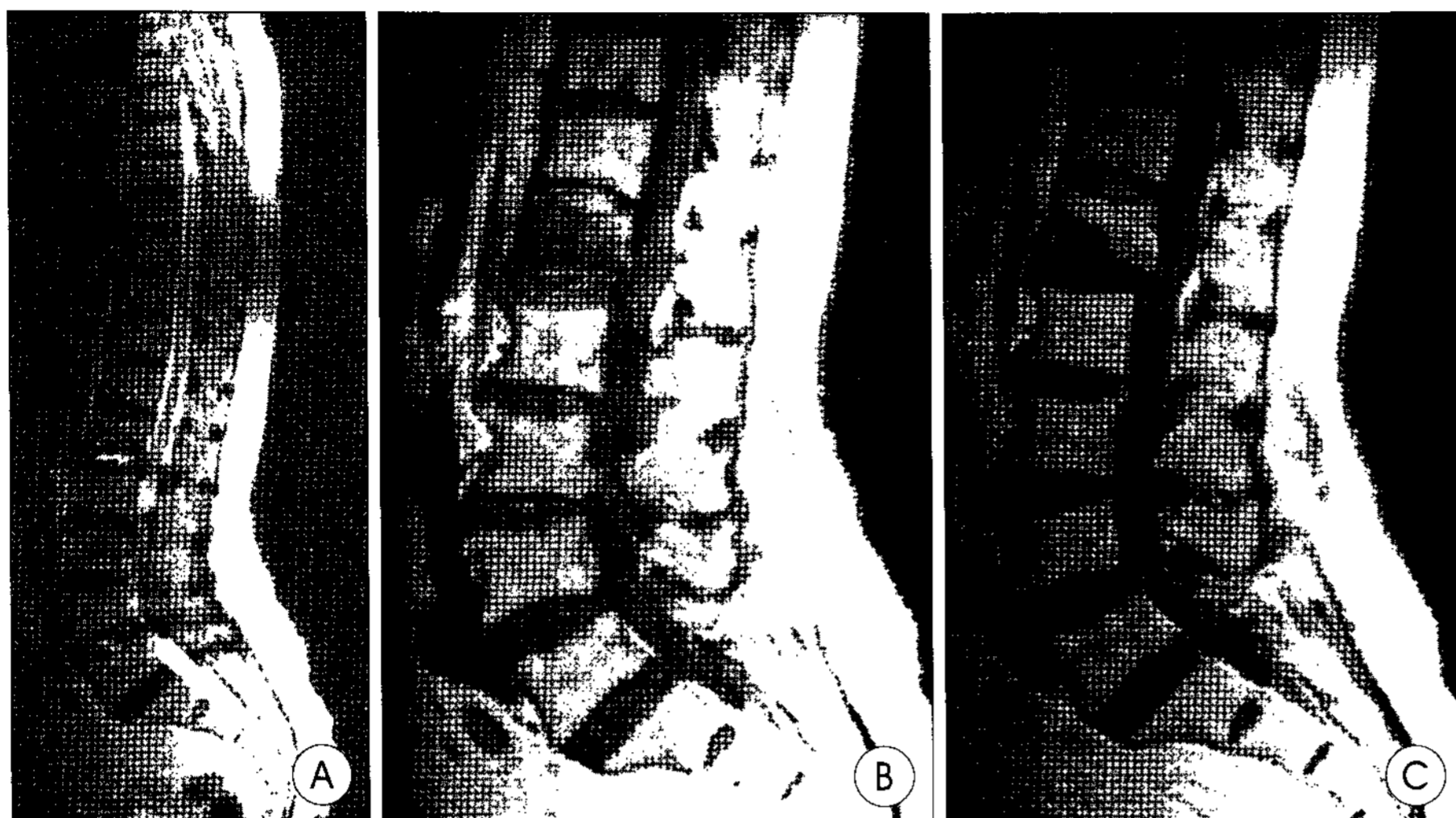


Fig. 5. A 89-year-old woman is admitted to our hospital with low back pain and right side sciatic pain for 1 month. A : T2 weighted magnetic resonance image of lumbar spine showing unusual bright signal intensity change of L1/2 and L4/5 disc space. B : T1 weighted magnetic resonance image revealing low signal intensity of L1 vertebral body. C : This lesion is not enhanced with gadolinium enhanced magnetic resonance image.

could obtain the enough volume of specimen for culture. So we had to use the broad-spectrum antibiotics. In case of the spine tuberculosis, it was confirmed by histologic examination using this osteoplasty system.

The vertebroplasty was performed for 220 compression fracture patients. After the procedure, the 201 patients experienced pain relief within 24 hours. But the 46 patients (20.9%) experienced the non symptomatic cement leakage, which are 24 Epidural leakages, 5 paravertebral leakages, 12 intradiscal leakages and 5 intravenous leakages.

Spinal biopsy using vertebroplasty needle was performed in 4 suspicious tumorous lesions and 11 suspicious infection lesions. One among 4 suspicious tumorous lesions was identified as tuberculosis, but we cannot diagnose completely for the others owing to insufficient biopsy. Two among 11 suspicious infection cases had positive biopsy result, but we cannot do diagnose for the others due to inadequate culture biopsy. In six of 12 negative biopsy result cases, we cannot obtain enough specimen for diagnosis.

Discussion

Painful osteoporotic compression fractures lead to significant morbidity and mortality¹⁴. Although the vertebroplasty was initially performed for back pain of patients with vertebral hemangiomas and metastatic lesion⁷, this procedure has become popular for the management of osteoporotic compression fracture and has been very useful treatment of back pain caused by osteoporotic compression fracture when the conservative treatment has failed¹⁶. However, this procedure has a difficulty in obtaining enough specimen for the path-

ologic diagnosis and also has some risks of complications, for example, bleeding at the puncture site, local infection, cement leakage, and embolic accidents^{3,5,6,8,11,13,15,17}.

Biopsy using vertebroplasty needle is sometimes difficult to make sure the pathologic result because the amount of specimen obtained by vertebroplasty needle is sometimes insufficient for pathologic diagnosis. We tried biopsy using vertebroplasty needle in 15 cases before, but we cannot confirm the pathologic diagnosis in 6 cases (40%) among them due to improper biopsy. The reason is maybe that the diameter of vertebroplasty needle is too small to obtain appropriate specimen.

The osteoplasty system recently developed from the vertebroplasty for effective bone biopsy and safe cement delivery. The procedure of the osteoplasty system is similar to that of the vertebroplasty. Vertebral bone biopsy is easily performed due to its direct access to the vertebral body and the enough amount of specimen for biopsy is obtained through the large cannula of the osteoplasty. Our data suggest the specimen, which obtained by osteoplasty system is enough to confirm the pathologic diagnosis, so the result of biopsy using the osteoplasty system are trustworthy in comparison with vertebroplasty needle. But further study is required for the specificity and sensitivity.

In order to minimize the risk of cement leakage and embolic accidents that is sometimes serious to patients³, the authors have recommend injection of PMMA in a thick viscous or partially polymerized consistency through large-bore cannula². In our study, there were 46 cases of cement leakage in the vertebroplasty but, there are no experience in osteoplasty system. We suggest that the procedure of the osteoplasty system is performed with larger cannula, so the procedure of osteoplasty system fills the role of vertebroplasty in simple osteoporotic compression fracture with low risk of complications.

The percutaneous vertebroplasty mainly plays the role of management for back pain caused by compression fracture. But The osteoplasty system is useful in cases of tumor suspicious compression fracture, which demands pathologic results and pain control. The low pressure delivery system reduces the risks of cement leakage and embolic event that is serious complications in percutaneous vertebroplasty procedure. Therefore, we think that the osteoplasty system is a more useful procedure in suspicious pathologic lesion combined

with spine compression fracture for the diagnosis and management.

Conclusion

The procedure of the osteoplasty system is very useful for vertebroplasty with low risk of serious complications and also for pathologic diagnosis in tumor suspicious lesion and culture of infection suspicious lesion. Therefore, we think that the osteoplasty system is more useful for management and diagnosis in spine pathology combined with spine compression fracture as a percutaneous procedure.

References

1. Barr JD, Barr MS, Lemley TJ, McCann RM : Percutaneous vertebroplasty for pain relief and spinal stabilization. *Spine* 25 : 923-928, 2000
2. Boström MP, Lane JM : Future directions. Augmentation of osteoporotic vertebral bodies. *Spine* 22(Suppl 24) : 38-42, 1997
3. Chen HL, Wong CS, Ho ST, Chang FL, Hsu CH, Wu CT : A lethal pulmonary embolism during percutaneous vertebroplasty. *Anesth Analg* 95 : 1060-1062, 2002
4. Chiras J, Depriester C, Weill A, Sola-Martinez MT, Deramond H : Percutaneous vertebral surgery. Technics and indications. *J Neuroradiol (Fr)* 24 : 45-49, 1997
5. Cotten A, Dewatre F, Cortet B, Assaker R, Leblond D, Duquesnoy B, et al : Percutaneous vertebroplasty for osteolytic metastases and myeloma : effects of the percentage of lesion filling and the leakage of methylmethacrylate at clinical follow-up. *Radiology* 200 : 525-530, 1996
6. Deramond H, Depriester C, Galibert P, Le Gars D : Percutaneous vertebroplasty with polymethylmethacrylate. Technique, indications, and results. *Radiol Clin North Am* 36 : 533-546, 1998
7. Galibert P, Deramond H, Rosat P, Le Gars D : Preliminary note on the treatment of vertebral angioma by percutaneous acrylic vertebroplasty. *Neurochirurgie(Fr)* 33 : 166-168, 1987
8. Jang JS, Lee SH, Jung SK : Pulmonary embolism of polymethylmethacrylate after percutaneous vertebroplasty : a report of three cases. *Spine* 27 : 416-418, 2002
9. Jensen ME, Evans AJ, Mathis JM, Kallmes DF, Cloft HJ, Dion JE : Percutaneous polymethylmethacrylate vertebroplasty in the treatment of osteoporotic vertebral body compression fractures : technical aspects. *AJNR Am J Neuroradiol* 18 : 1897-1904, 1997
10. Lee JU, Ryu KS, Park CK, Cho YS, Ji C, Cho KS, et al : Percutaneous Polymethylmethacrylate Vertebroplasty in the Treatment of Osteoporotic Thoracic and Lumbar Vertebral Body Compression Fractures : Outcome of 159 Patients. *J Korean Neurosurg Soc* 30 : 173-179, 2001
11. Levine SA, Perin LA, Hayes D, Hayes WS : An evidence-based evaluation of percutaneous vertebroplasty. *Manag Care* 9 : 56-60, 2000
12. Noh CH, Yi JS, Lee HJ, Yang JH, Lee IW, Kim MC, et al : Effect of percutaneous vertebroplasty with polymethylmethacrylate to osteoporotic spinal compression fractures and bursting fractures. *J Korean Neurosurg Soc* 35 : 365-371, 2004
13. Padovani B, Kasriel O, Brunner P, Peretti-Viton P : Pulmonary embolism caused by acrylic cement : a rare complication of percutaneous vertebroplasty. *AJNR Am J neuroradiol* 20 : 375-377, 1999
14. Schlaich C, Minne HW, Bruckner T, Wagner G, Gebest HJ, Grunze M, et al : Reduced pulmonary function in patients with spinal osteoporotic fractures. *Osteoporos Int* 8 : 261-267, 1998
15. Scroop R, Eskridge J, Britz GW : Paradoxical cerebral arterial embolization of cement during intraoperative vertebroplasty : Case report. *AJNR Am J Neuroradiol* 23 : 868-870, 2002
16. Wasnich RD : Vertebral fracture epidemiology. *Bone* 18(Suppl 3) : 179-183, 1996
17. Yoo KY, Jeong SW, Yoon W, Lee J : Acute respiratory distress syndrome associated with pulmonary cement embolism following percutaneous vertebroplasty with polymethylmethacrylate. *Spine* 29 : 294-297, 2004