

Wedge Shape Cage in Posterior Lumbar Interbody Fusion : Focusing on Changes of Lordotic Curve

Joon-Seok Kim, M.D., Seong-Hoon Oh, M.D., Sung-Bum Kim, M.D.,
Hyeong-Joong Yi, M.D., Yong Ko, M.D., Young-Soo Kim, M.D.

Department of Neurosurgery, Hanyang University College of Medicine, Seoul, Korea

Objective : Lumbar lordotic curve on L4 to S1 level is important in maintaining spinal sagittal alignment. Although there has been no definite report in lordotic value, loss of lumbar lordotic curve may lead to pathologic change especially in degenerative lumbar disease. This study examines the changes of lumbar lordotic curve after posterior lumbar interbody fusion with wedge shape cage.

Methods : We studied 45 patients who had undergone posterior lumbar interbody fusion with wedge shape cage and screw fixation due to degenerative lumbar disease. Preoperative and postoperative lateral radiographs were taken and one independent observer measured the change of lordotic curve and height of intervertebral space where cages were placed. Segmental lordotic curve angle was measured by Cobb method. Height of intervertebral space was measured by averaging the sum of anterior, posterior, and midpoint interbody distance. Clinical outcome was assessed on Prolo scale at 1 month of postoperative period.

Results : Nineteen paired wedge shape cages were placed on L4-5 level and 6 paired same cages were inserted on L5-S1 level. Among them, 18 patients showed increased segmental lordotic curve angle. Mean increased segmental lordotic curve angle after placing the wedge shape cages was 1.96°. Mean increased disc height was 3.21mm. No cases showed retropulsion of cage. The clinical success rate on Prolo's scale was 92.0%.

Conclusion : Posterior lumbar interbody fusion with wedge shape cage provides increased lordotic curve, increased height of intervertebral space, and satisfactory clinical outcome in a short-term period.

KEY WORDS : Lordotic curve · PLIF · Lordotic shape cage.

Introduction

Lumbar lordotic curve plays an important role to maintain the spinal sagittal alignment. The lordotic curve between L4-S1 vertebral body was important because it bears the most load of body weight and the loss of lordotic curve may be closely related with low back pain^{2,6)}. As well as, the loss of lordotic curve after spinal fusion may cause the flat-back syndrome that is responsible for continuous back pain, postural disproportion and gait disturbance¹⁸⁾. The above-mentioned reason has made the effort to plan reconstruction and preservation of the lumbar lordotic curve^{11,13,19)}. But, in spite of a lot of efforts, the exact measured value of the lumbar lordotic curve was not reported till now.

Posterior lumbar interbody fusion (PLIF) has been used

widely, concerning on the recovery and elevation of lordotic curve on the fused level, which was closely related with improvement of bony fusion rate between vertebral bodies and postoperative outcome¹²⁾. The various shaped cages have been used in PLIF to recover the lordotic curve and the wedge shape cages were designed to make the cage more suitable to the intervertebral shape recently. Although the wedge shape cages may thought to be more available in recovery of the lordotic curve on affected level than other cages theoretically, the studies of lordotic curve recovery after using the wedge shape cage on PLIF have been rarely reported¹⁴⁾.

The purpose of the study was to investigate the change of lordotic curve and height of affected intervertebral bodies after PLIF with wedge shape cage in degenerative lumbar disease.

• Received : November 26, 2004 • Accepted : May 4, 2005

• Address for reprints : Seong-Hoon Oh, M.D., Department of Neurosurgery, Hanyang University College of Medicine, 17 Haengdang-dong, Seongdong-gu, Seoul 133-792, Korea Tel : +82-2-2290-8496, Fax : +82-2-2281-0954, E-mail : osh8496@hanyang.ac.kr

Materials and Methods

Forty five patients, who underwent PLIF with the wedge shape cage of 8 degree angle for degenerative lumbar spinal stenosis during October, 2002 to January, 2003, were selected in the study.

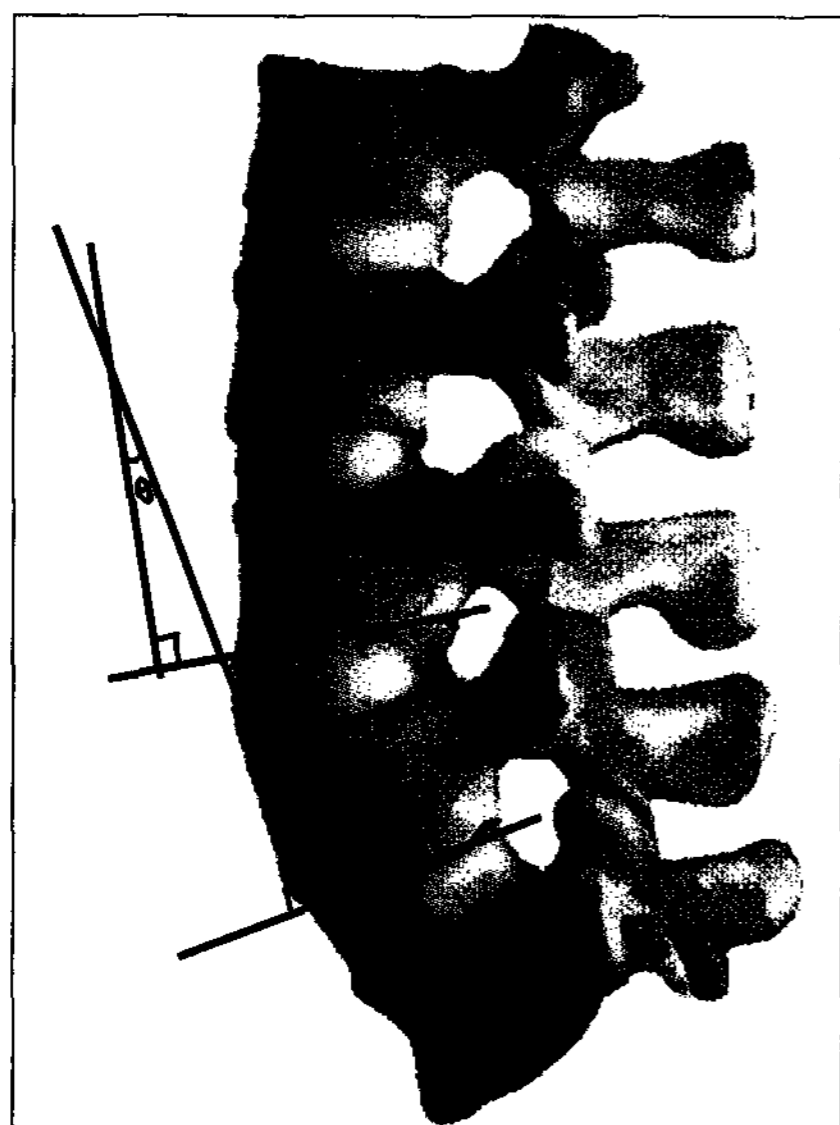


Fig. 1. Measurement lines for segmental lordotic curve of operative level using Cobb method. Segmental lordosis is determined by drawing lines parallel to the cephalad vertebral body endplate and the caudad vertebral body endplate. A second line is drawn perpendicular to each of the previously drawn parallel lines. The intersection angle of the second set of lines defines as the segmental lordotic angle (θ).

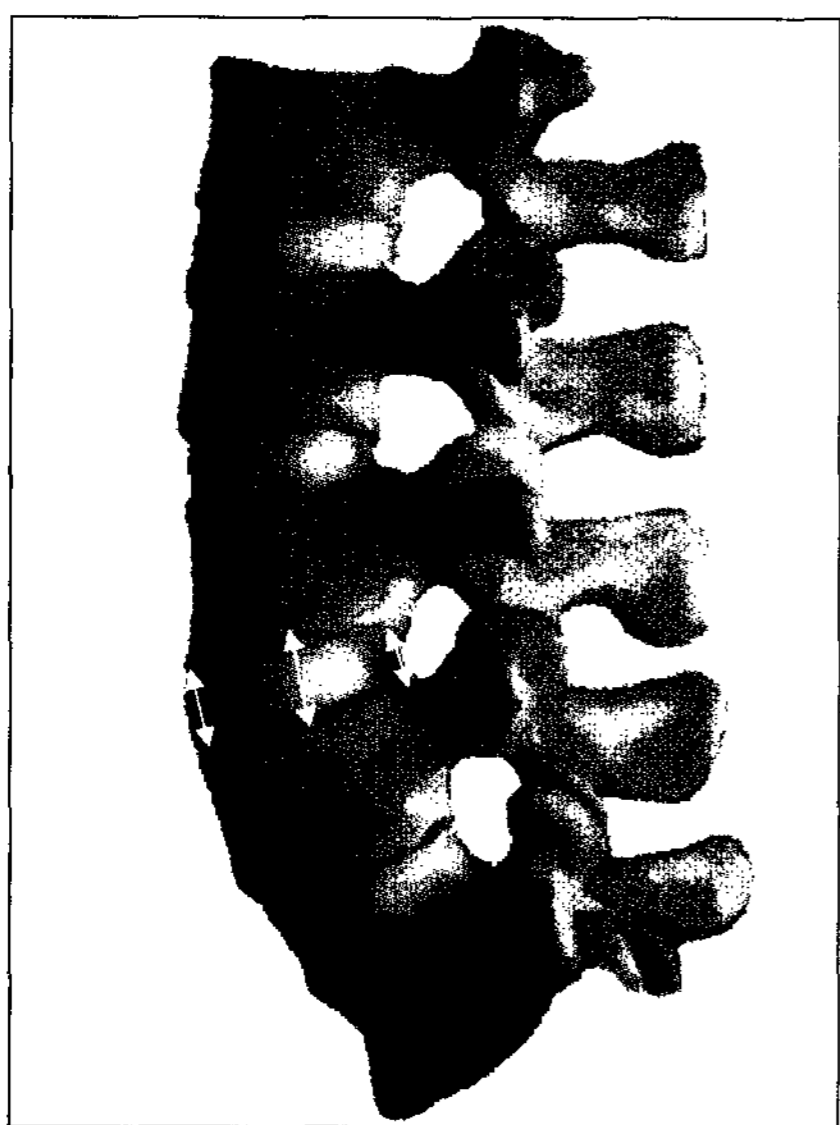


Fig. 2. Measurement for height of intervertebral space, which is measured by dividing the sum of anterior, posterior, and midpoint interbody distance by 3.

The changes of lordotic curve angle and heights of intervertebral space were measured and the clinical outcomes were investigated using Prolo scale retrospectively.

Measurement of the changes of lumbar lordotic curve

The segmental lumbar lordotic curve angle was defined as the angle between superior and inferior vertebral plates of affected level. The segmental lordotic curve angle was measured by calibrating the angle between the lines drawn on the lateral simple radiographs perpendicularly to the lines parallel to each superior and inferior vertebral endplates of the disc space, according to Cobb method (Fig. 1). By this measurement procedure, preoperative and 1 month postoperative segmental

lordotic curve angle were measured and calculated the changes of segmental lordotic curve angle.

Measurement of height changes of the lumbar intervertebral space

The height of intervertebral space was measured by averaging the sum of affected anterior, posterior, and midpoint interbody distance on lateral simple radiographs (Fig. 2). Preoperative and 1 month postoperative intervertebral heights were measured and changes, affected by cage insertion, were figured out.

Clinical outcome

Prolo scale was used to evaluate the surgery related clinical outcome. Clinical outcome was expressed poor when patients felt intolerable pain and excellent when patients participated in premorbid activities without recurrence of pain. Clinical outcome was evaluated at 1 month after the operation.

Results

Age, sex and diagnosis

Thirty three female patients and 12 male were operated. Their mean age was 55.6 years (range 42~64 years). Twenty six cases (57.7%) was operated for spinal stenosis, 12 cases (26.6%) for spondylolisthesis, 5 cases (11.1%) for recurred herniated lumbar disc disorder and 2 cases (4.4%) for essential scoliosis, respectively.

Location and distribution of cages

Wedge shape cages with an angle of 8 degrees were inserted to L4-5 intervertebral space in 33 cases (73.3%), L5-S1 intervertebral space in 6 cases (13.3%), L3-4 intervertebral space in 4 cases (8.8%) and L2-3 intervertebral space in 2 cases (4.4%), respectively.

Change of lordotic curve before and after operation

Preoperative mean lordotic curve angle was 11.6° and 1 month postoperative mean lordotic curve angle was estimated to be 13.31°. Mean lordotic curve angle was increased to 1.71° after operation (Fig. 3).

Among total 45 cases, 37 cases (82.2%) showed increase lordotic curve angle postoperatively.

Change of intervertebral height

43 cases (95.5%) showed increased intervertebral space, postoperatively. Preoperative and 1 month postoperative height of intervertebral space were 7.24 mm and 10.3 mm, respectively. Mean elevated intervertebral height after insertion of wedge shape cage was 3.06 mm.

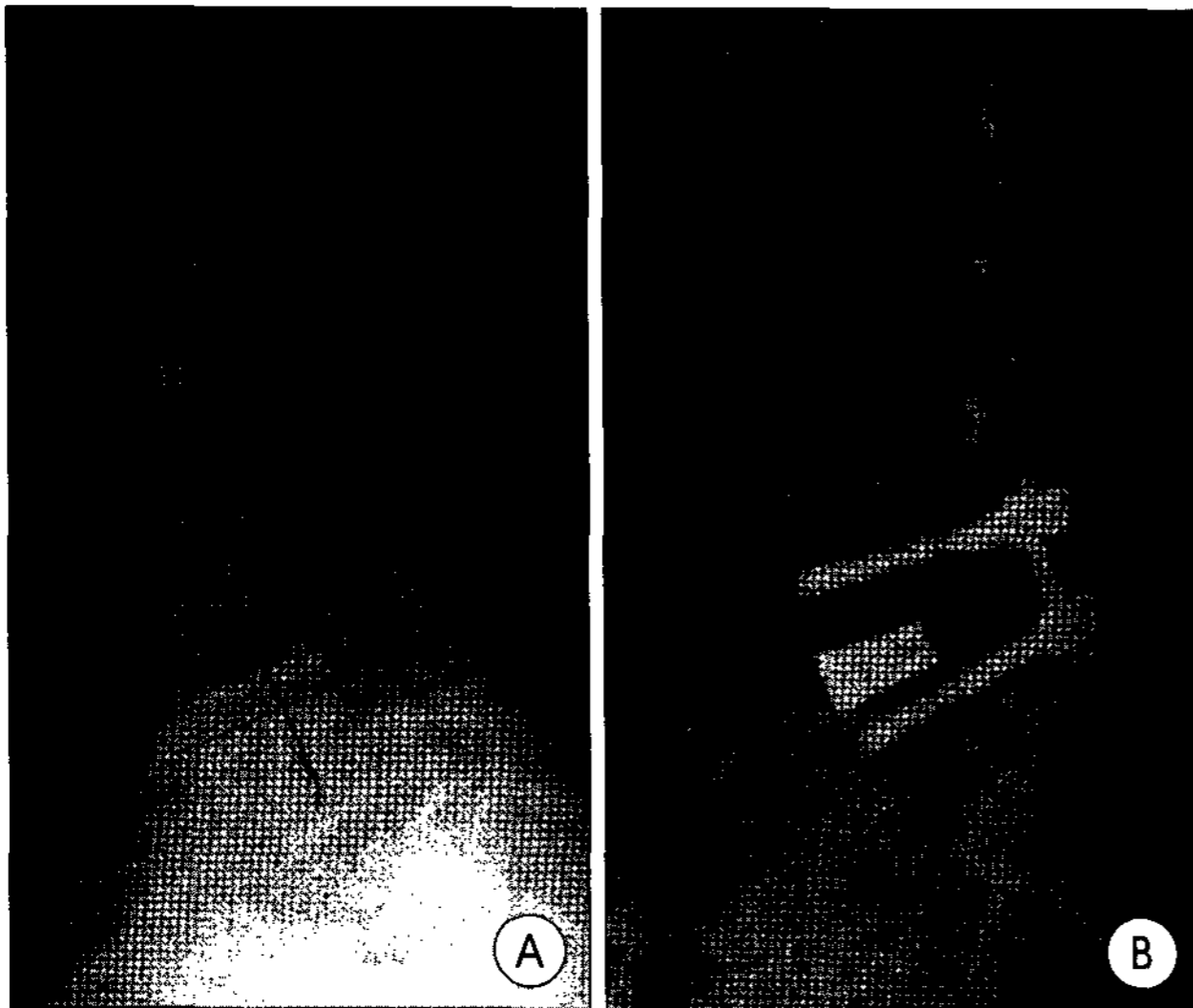


Fig. 3. Example of segmental lordotic curve restoration. A : preoperative lateral simple radiograph shows degenerative spondylolisthesis on L4-5 level with decreased disc height. B : postoperative film shows circumferential fusion using lordotic curve cage with restoration of lordotic curve and increased disc height.

Clinical outcome of postoperative 1 month

According to Prolo's scale, excellent, good, fair and poor outcomes were 18 cases (40%), 23 cases (51.1%), 3 cases (6.6%) and 1 case (2.2%) respectively. Clinical successful outcome including excellent and good outcomes was 91.1%.

Discussion

Various metallic cages have been developed together and used widely with development of operation technique of PLIF. Shape and size of cage were designed for the purpose of maintaining maximal stability and repairing the mechanical defect by performing lumbar segmental fusion^{1,21}.

In the point of restoring of normal lordotic curve and prevention of postoperative kyphosis, many wedge shape cages have been developed and their uses of wedge shape cage have been recently increased gradually in PLIF. Theoretically wedge shape cage would be fused better than other cage, since the shape of intervertebral disc is wedge form between superior and inferior vertebral bodies¹⁴. However, a few has been studied about wedge shape cage in the literatures, regarding not only surgical outcome and bone fusion rate but changes of lordotic curve and angle. From the viewpoint of lordotic curve and angle, lordotic curve contains many definitions, which means that absolute value of lordotic curve and angle does not confirmed actually. Moe et al.¹⁵ reported normal range of lordotic curve from -60° to -40° . Stagnara et al.¹⁷ reported that the range of lordotic curves measured between the first lumbar and sacrum using Cobb method was -79° to -33° . The normal lordotic curve range of people was reported -66° to -56° as

average between the first lumbar and sacrum^{4,6,9,16}. In that matter, every person has different normal range of lordotic curve. Since these studies are not the measurement of adjacent vertebrae but the measurement of the lordotic curve of whole lumbar vertebrae, the precise comparison between the measured segmental lordotic curve is difficult. Regarding segmental lordotic curve, Gelb et al reported that angle of the lordotic curve of L4-5 and L5-S1 in 100 normal people was estimated to be $24 \pm 7^{\circ}$, which was 11.6° in our study. Though direct comparison between above studies and our study would be unreasonable, lordotic curve angle of normal person may be more higher than that of our patients group. This result would be the one of the proof that the decrease of lordotic curve is closely related to the degenerative lumbar disease. Our result would be similar to the assertion of Godde et al.⁷ that clinical improvement had the important relationship with the lordotic curve of the fused segments.

There have been many literatures, emphasizing the lordosis on fused segments. Brantigan et al.³ reported 94.6% rates of success in the group using wedge shape cage for 2 years follow up. Loss of lordosis or kyphosis of fused segments may not only promote segmental degeneration but also induce instability or kyphosis. Umehara et al.²⁰ also assumed that loss of lordosis in the fused segments increased lordotic curve of the adjacent segments. Therefore, maintenance of appropriate lordotic curve is thought to prevent remarkable lordotic change in the segments adjacent to the fused segments. This is related to early degenerative change occurred in the segments adjacent to the fused segments after posterior lumbar interbody fusion, hence recovery of lordosis is thought to take effect in preventing postoperative junctional syndrome.

There also have been many comparative study, focusing on cage shape. Wedge shape cages with an angle of 3 degrees showed better recovery of lordosis and bony fusion than the hexadral cages in the circumferential fusion on postoperative elevation of lordotic curve⁷. Diedrich et al.⁵ also reported that the patients operated by the wedge shape cages with an angle of 4 degrees appeared to be better clinical outcome and recovery of lordosis, comparing with the hexadral cages in their 40 patients, though, they could not find out the statistical difference between two groups in lordotic curve angle.

Regarding the 8 degrees wedge shaped cages that authors studied, we used these cage on the supposition that large angle of wedge shape cage would provide more lordotic curve than small one. That is to say, increased lordotic curve would be achieved more definitely. Gelb DE et al.⁶ insisted that whereas 3° type cage was sufficient at L3-L4, an angulation of 3° was not obviously appropriate to enhance segmental lordosis to normal values at L4-L5. They also asserted that 8° type cage leads to physiologic segmental lordosis at L4-L5. That is the

reason why we used 8 degrees wedge shaped cages. However, the important factors, which we failed to catch, are that recovery of lordosis was affected by not only the shape of cage but also size of cage. Besides intraoperative position of patient and the extent of discectomy for bony fusion were also important factors affecting the lordosis. In this study, time that authors evaluated the lordotic curve angle was 1 month after operation. Since subsidence of interbody could appear during 1 month period, we did not evaluate the lordotic curve angle at immediate postoperative state.

However, there were the reports that lordotic curve did not affect the clinical outcomes. Goldstein et al.⁸⁾ reported that good clinical outcome with cylindrical cage was achieved without relation of lordotic curve, which was decreased gradually for 2 years after interbody fusion. They also mentioned that unnecessary effort for increasing lordotic curve could aggravate clinical symptom and other factor is more important to recovery of lordosis than shape of cage. This was direct apposite to our results. This result would be closely related to the shape of cages they used. Because cylindrical cages were easy to encounter the subsidence, their lordotic curve may be decreased¹⁰⁾.

Distinguishing mark of current study was identification of increased lordotic curve angle after PLIF with 8 degree wedge shape cages at postoperative 1 month, though there were shortcomings including short follow-up period, small size of cases and absence of control group.

Long term follow-up about the change of the postoperative lordotic curve is considered to be necessary.

Conclusion

Authors experienced the good clinical outcome with increased lordotic curve angle and increased intervertebral height after PLIF with the 8 degrees wedge shape cage.

Compound studies about lordotic curve including the size and shape of cage as well as intraoperative position, which are the important factors of lordotic curve, are indispensable.

References

1. Bagby GW : Arthrodesis by the distraction-compression method using a stainless steel implant. *Orthopedics* 11 : 931-934, 1988

2. Beckers L, Bekaert J : The role of lordosis. *Acta Orthop Belg* 57 : 198-202, 1991
3. Brantigan JW, Neidre A : Achievement of normal sagittal plane alignment using a wedged carbon fiber reinforced polymer fusion cage in treatment of spondylolisthesis. *Spine J* 3 : 186-196, 2003
4. Cheng XG, Sun Y, Boonen S, Nicholson PH, Brys P, Dequeker J, et al : Measurement of vertebral shape by radiographic morphometry : sex differences and relationships with vertebral level and lumbar lordosis. *Skeletal Radiol* 27 : 380-384, 1998
5. Diedrich O, Perlick L, Schmitt O, Kraft CN : Radiographic spinal profile changes induced by cage design after posterior lumbar interbody fusion preliminary report of a study with wedged implants. *Spine* 26 : 274-280, 2001
6. Gelb DE, Lenke LG, Bridwell KH, Blanke K, McEneaney KW : An analysis of sagittal spinal alignment in 100 asymptomatic middle and older aged volunteers. *Spine* 10 : 1351-1358, 1995
7. Godde S, Fritsch E, Dienst M, Kohn D : Influence of cage geometry on sagittal alignment in instrumented posterior lumbar interbody fusion. *Spine* 28 : 1693-1699, 2003
8. Goldstein JA, Macenski MJ, Griffith SL, McAfee PC : Lumbar sagittal alignment after fusion with a threaded interbody cage. *Spine* 26 : 1137-1142, 2001
9. Jackson RP, Peterson MD, McMagna AC, Hales C : Compensatory spinopelvic balance over the hip axis and better reliability in measuring lordosis to the pelvic radius on standing lateral radiographs of adult volunteers and patients. *Spine* 23 : 1750-1767, 1998
10. Kim YS, Chin DK, Yoon DH, Cho YE, Jin BH : Posterior Lumbar Interbody Fusion with Threaded Fusion Cage : Long-term Follow-up Results. *J Korean Neurosurg Soc* 28 : 1765-1772, 1999
11. La Grone MO : Loss of lumbar lordosis a complication of spinal fusion for scoliosis. *Orthop Clin North Am* 19 : 383-393, 1988
12. Lazennec JY, Ramare S, Arafati N, Laudet CG, Gorin M, Roger B, et al : Sagittal alignment in lumbosacral fusion : relations between radiological parameters and pain. *Eur Spine J* 9 : 47-55, 2000
13. Lord MJ, Small JM, Dinsay JM, Watkins RG : Lumbar lordosis effects of sitting and standing. *Spine* 22 : 2571-2574, 1997
14. McAfee PC : Interbody fusion cages in reconstructive operations on the spine. *J Bone Joint Surg* 81A : 859-880, 1999
15. Moe JH, Winter RB, Bradford DS, Lonstein JE : Kyphosis-lordosis; general principles. In : *Scoliosis and Other Spinal Deformities*. Philadelphia : W.B. Saunders, 1978, pp325-330
16. Saraste H, Brostrom LA, Aparisi T : Prognostic radiographic aspects of spondylolisthesis. *Acta Radiol Diagn* 25 : 427-432, 1984
17. Stagnara P, De Mauroy JC, Dran G, Gonon GP, Costanzo G, Dimnet J, et al : Reciprocal angulation of vertebral bodies in a sagittal plane: approach to references for the evaluation of kyphosis and lordosis. *Spine* 7 : 335-342, 1982
18. Stephens GC, Yoo JU, Wilbur G : Comparison of lumbar sagittal alignment produced by different operative positions. *Spine* 21 : 1802-1806, 1996
19. Tribus CB, Belanger TA, Zdeblick TA : The effect of operative position and short-segment fusion on maintenance of sagittal alignment of the lumbar spine. *Spine* 24 : 58-61, 1999
20. Umehara S, Zindrick MR, Patwardhan AG, Havey RM, Vrbos LA, Knight GW, et al : The biomechanical effect of postoperative hypolordosis in instrumented lumbar fusion on instrumented and adjacent spinal segments. *Spine* 25 : 1617-1624, 2000
21. Weiner BK, Fraser RD : Spine update lumbar interbody cages. *Spine* 23 : 634-640, 1998