

Effectiveness of Selective Peripheral Denervation for the Treatment of Spasmodic Torticollis

Ryoong Huh, M.D.,¹ Jung Yong Ahn, M.D.,¹ Young Sun Chung, M.D.,¹
Jong Hee Chang, M.D.,² Jin Woo Chang, M.D.,² Sang Sup Chung, M.D.¹

Department of Neurosurgery,¹ Bundang CHA Hospital, Pochon CHA Medical University, Seongnam, Korea
Department of Neurosurgery,² College of Medicine, Yonsei University, Seoul, Korea

Objective : The Bertrand's method of selective peripheral denervation for spasmodic torticollis has already been established as being an effective and safe method. However, such effectiveness has not yet been established in Korea. The authors have performed several cases of selective denervation for the treatment of spasmodic torticollis and we hereby describe the details of the operative method to determine the effectiveness of the method.

Methods : Ten patients who had the selective denervation for the spasmodic torticollis from October 1997 to December 2003, were analyzed. There were 4 rotational and 6 combined types (3 rotational plus retrocollis, 3 rotational plus laterocollis). We performed preoperative electromyograms and neck muscle tonograms in all cases. The technique was used to involve denervation of the ipsilateral posterior paraspinal muscles. Denervation of the sternocleidomastoid muscle was performed on the contralateral side for rotational torticollis and on the ipsilateral side for laterocollis combined type. The surgery was followed by a rigorous physical therapy program.

Results : The surgical results were divided into 4 groups labeled excellent, good, fair, and poor. There were 5 excellent patients who showed no detectable abnormal movements, 4 good patients who showed slight residual deviations or slight residual abnormal movements, and 1 fair patient with appreciable residual abnormal movements. Postoperative pain was well tolerated. There was no significant surgical complications.

Conclusion : The study confirms that selective peripheral denervation for the treatment of spasmodic torticollis is a very useful and safe surgical technique.

KEY WORDS : Spasmodic torticollis · Selective peripheral denervation · Effectiveness.

Introduction

Spasmodic torticollis is the most common form of idiopathic focal dystonia, characterized by deviation of the neck due to involuntary contraction of cervical muscles. Generally, it is classified as rotational torticollis, laterocollis, retrocollis, anterocollis and their various combinations by the presentation of the neck posture and deviation feature. Spasmodic torticollis not only results in substantial deformity, but also is frequently associated with disabling neck pain from sustained muscle contraction. Spasmodic torticollis has been known to be difficult to all treatment modalities. Conservative treatments such as, pharmacotherapy, physiotherapy or psychotherapy are highly unsuccessful and often followed by side effects. But injection of botulinum toxin to the dystonic muscles induces local

weakness but reduces spasms. There are limitations with this therapy, however. The benefits last only 2 to 4 months and several times repeated injections are necessary every year. Some patients fail to respond and in some patients the symptoms become refractory to botulinum toxin with repeated injections, often due to the development of anti-botulinum toxin antibodies^{1-4,11,13,16}.

Due to the limitations of conservative treatments, various neurosurgical procedures have been attempted such as stereotactic thalamotomy, cervical rhizotomy or microvascular decompression of accessory nerve, but the results were unsatisfactory. Bertrand and colleagues¹⁻³ developed a surgical technique that parallels the effects of botulinum toxin. The rationale is the selective weakening of those cervical muscles mediating the dystonic muscle contraction. The Bertrand's

• Received : May 23, 2005 • Accepted : July 7, 2005

• Address for reprints : Ryoong Huh, M.D., Department of Neurosurgery, Bundang CHA Hospital, Pochon CHA Medical University, 351 Yatap-dong, Bundang-gu, Seongnam 463-712, Korea Tel : +82-31-780-5260, Fax : +82-31-780-5269, E-mail : hrnsd@cha.ac.kr

procedure is based on the extraspinal denervation of the primary cervical musculature that participates in the abnormal neck posture, leaving the uninvolved muscles to maintain adequate neck movement. As this surgical procedure gained experience, the effectiveness and safety became established^{1,7,15}. As well, other neurosurgeons have been developing modified surgical procedures based on Bertrand's method^{5,7,12,14,15}. The authors have performed Bertrand's selective denervation for the several cases of spasmodic torticollis and we hereby describe the details of the operative technique to determine the effectiveness of the method.

Materials and Methods

Ten patients who had selective denervation at our institute and Severance university hospital for the spasmodic

torticollis from October 1997 to December 2003, were analyzed retrospectively including medical records, video tape and the results of neck tonometry. The types of spasmodic torticollis and operative results were analyzed by Bertrand's method¹⁻³. There were 5 men and 5 women with a mean age of 52.4 ± 9 years. The mean duration of symptoms was 31.4 ± 12.5 months. Each patient's neck posture at presentation was characterized as one or a combination of two predominant torticollis vectors. Pure rotational torticollis was identified in 4 patients, 3 patients were combined rotational and retrocollis type and the rest 3 patients were combined rotational and laterocollis type. The laterality of rotational type was 2 : 3 (left : right). As the operative techniques were completely different from type to type of spasmodic torticollis, the exact classification of torticollis is very important. The pure rotational torticollis was diagnosed easily by its typical symptomatic

presentation. But, the combined rotational type torticollis must be diagnosed carefully due to their complex clinical presentations (Fig. 1).

All of the patients had been treated with anticholinergics, anticonvulsants, muscle relaxants and analgesics before the surgery. Among them, 6 patients were treated with botulinum toxin injections and 5 patients were treated with herb medicine and acupuncture. All of these patients were taken electromyogram (EMG) and tonogram of posterior neck muscles and sternocleidomastoid (SCM) muscle prior to surgery. These neck muscle tonogram and electromyogram results proved to be very important indications when selecting surgical methods.

Surgical methods and anatomical considerations

The basic concept is selective denervation for the hyperactive individual muscles. In accordance, the muscles and nerves requiring selective denervation for various types of spasmodic torticollis requires different surgical methods (Table 1). Patients preferred the sitting position with a slight flexion of the neck. The sitting position minimized

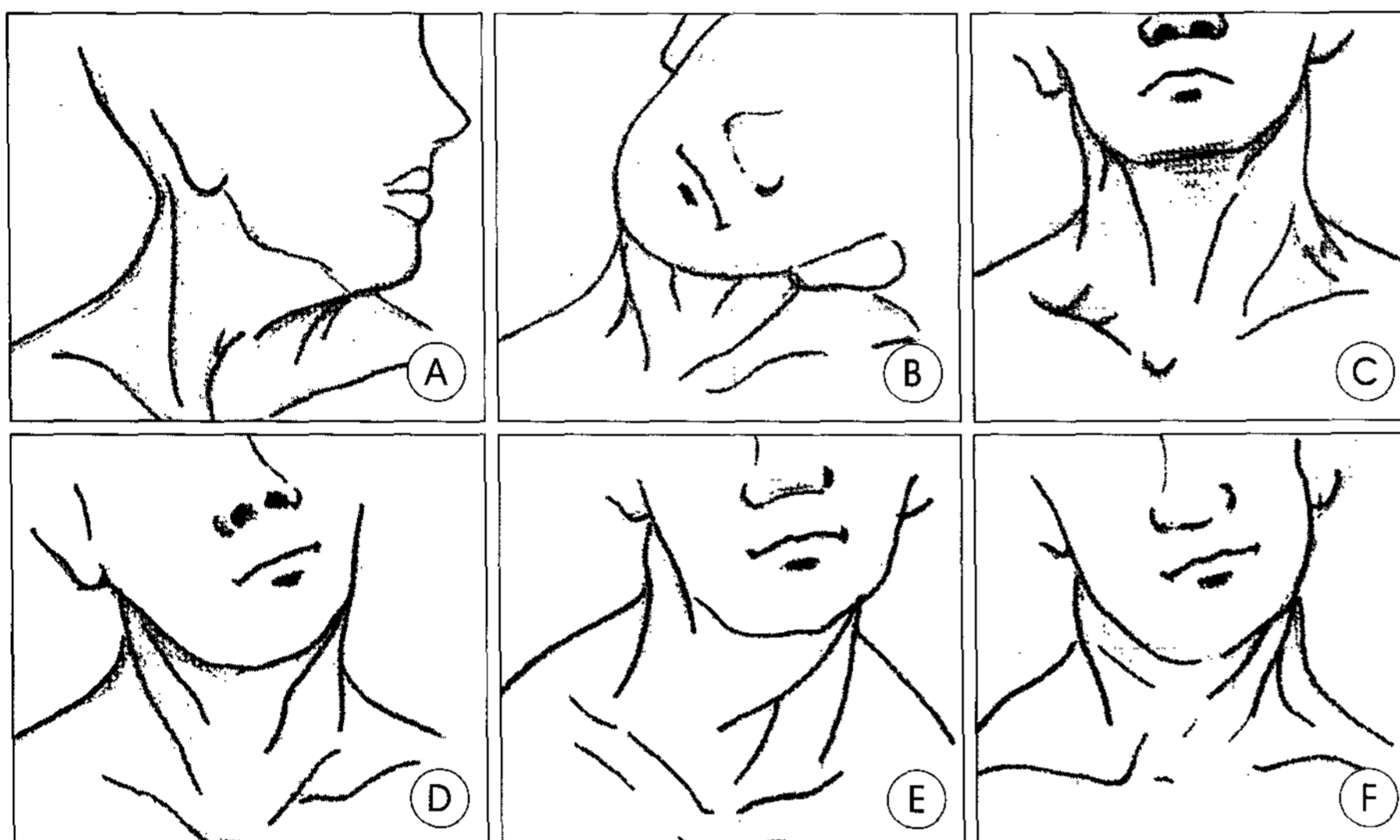


Fig. 1. Schematic drawing of the types of torticollis, A : Rotational Type, B : Laterocollis, C : Retrocollis, D, E : Rotational Type + Retrocollis, F : Rotational Type + Laterocollis

Table 1. Operative procedures for each types of spasmodic torticollis

Type	Operative procedure
Rotation Type	Contralateral SCM denervation and myotomy + ipsilateral post. neck muscle selective rhizotomy (C1,2) and post. Ramisectomy(C3-6)
Retrocollis	Bilateral post. neck muscle selective rhizotomy (C1,2) and post. Ramisectomy(C3-6)
Laterocollis	Ipsilateral SCM denervation and myotomy + ipsilateral post. neck muscle selective rhizotomy (C1,2) and post. Ramisectomy(C3-6)
Rotation + Retrocollis	Contralateral SCM denervation + bilateral post. neck muscle selective rhizotomy (C1,2 and C3) and ipsilateral post. ramisectomy(C4-6)
Rotation + Laterocollis	Bilateral SCM denervation and myotomy + ipsilateral post. neck muscle selective rhizotomy (C1,2) and post. ramisectomy(C3-6)

SCM : sternocleidomastoid

the bleeding of the venous plexus, showing the merit of the simultaneous advancement of accessory nerve denervation and posterior neck muscle denervation. Surgery under general anesthesia is performed with muscle relaxant injection only in the induction stage for the intraoperative EMG monitoring. Before draping, the muscles to be denervated are positioned with EMG electrodes. In the authors' cases, although the types of spasmodic torticollis were different, the sternocleidomastoid muscle, trapezius muscle, splenius capitis muscle, and semispinalis capitis muscle were positioned with EMG electrodes. The usage of longer electrodes was helpful for the accurate EMG monitoring. Each denervation procedure was performed under a microscope.

When the neck is rotated, the ipsilateral agonist and synergist muscles are innervated by the posterior roots of the C1-8 nerves (mainly C1-6). Contralaterally, the agonist is the SCM muscle which is innervated by the accessory nerve. When the neck is extended, bilateral posterior neck muscles are the agonists that are innervated by the posterior roots of the C1-8 nerves (Table 2). Accordingly, the main objectives of the denervation procedure were the posterior roots of the C1-6 nerves and accessory nerves.

Operative procedures consist of two stages. The authors preferred the simpler accessory nerve denervation prior to posterior neck denervation.

Accessory nerve resection and denervation

The incision for the spinal accessory nerve extends from the base of the ear to the junction of the horizontal and vertical portions of the trapezius, at the point where the main branch to the trapezius enters the muscle. The SCM and trapezius muscles were dissected carefully. The branch to the trapezius is easily identified with stimulation in the lower portion of the incision and it is followed upward. Frequently, there is a U-shaped deviation near the point where it joins the branches to the SCM. It must be dissected carefully at that point to avoid injury of the main branch to the trapezius as the posterior portion of the SCM is gradually sectioned. The spinal accessory nerve is then followed upward to the level of styloid process. The accessory nerve is isolated along its entire course and all the branches to the SCM are clipped and sectioned. Only the branch to the

trapezius is spared in order to avoid leaving any recurrent branches to the SCM. After careful hemostasis, the aponeurosis of the muscle is closed and the skin is sutured.

Posterior neck muscle denervation

The skin incision extends from the external occipital protuberance to the spinous process of C7. This facilitates the exposure of C1 and the posterior primary divisions up to their origin. In the case of surgery on only one side, the skin incision is made the shape of the roman numeral 7, while for the bilateral operation skin incision is made the shape of the alphabetic "T". Due to the widened operative field with this shape of incision, excessive retraction, which can produce neurapraxia and hinder stimulation can be prevented. The trapezius, the splenius, and the semispinalis are sectioned just below the insertion. Under the EMG monitoring and stimulation, the root of C1 is identified in the notch for vertebral artery laterally on the posterior arch of atlas. The emergence of C1 is noted underneath the vertebral artery. The vertebral artery is elevated showing the C1 as divided into anterior and posterior branches. Lower down, between the posterior arch of C1 and C2, the root of C2 as it divides into its anterior and posterior branch, the latter emerging between the arches is seen. At each level, the posterior branches were dissected and avulsed. Posterior rami of the C3-6 were visualized on the emerging point of the intervertebral foramen with retraction. The nerve roots stimulations were helpful to identify the posterior rami of C3-6. Careful resections were done at the C3-6 level. After confirmation of denervation by the EMG, surgery is completed by thorough hemostasis and suturing. In circumstances when incisions are made bilaterally, careful

Table 2. Muscles involved in specific movements in spasmodic torticollis

Rotation		Extension	Inclination
Same side	Opposite side		
Splenius capitis/cervicis (A)	SCM (A)		Splenius capitis (A)
PR of C1-C6/ PR of C4-C8	XI, VR of C2, C3	Splenius capitis/cervicis (A)	PR of C1-C6
		PR of C1-C6/ PR of C4-C8	Levator scapulae (A)
		Splenius capitis (A)	VR of C3 C4
		PR of C2-C6	Trapezius (S)
Obli. Capitis Inf. (S)	Obli. Capitis Sup. (S) PR of C1	Longissimus capitis (A)	XI, VR of C3, C
PR of C1-C2		PR of C3-C8	
		Rectus capitis post. major/minor,	
		Obli. Capitis Sup. (S)	
		PR of C1	
Longissimus capitis (S)	Semispinalis capitis (S)		
PR of C3-C8	PR of C2-C6		

(A) agonists, (S) synergists, SCM : sternocleidomastoid, Obli. : oblique, PR : posterior root VR : ventral root, XI : Accessory nerve

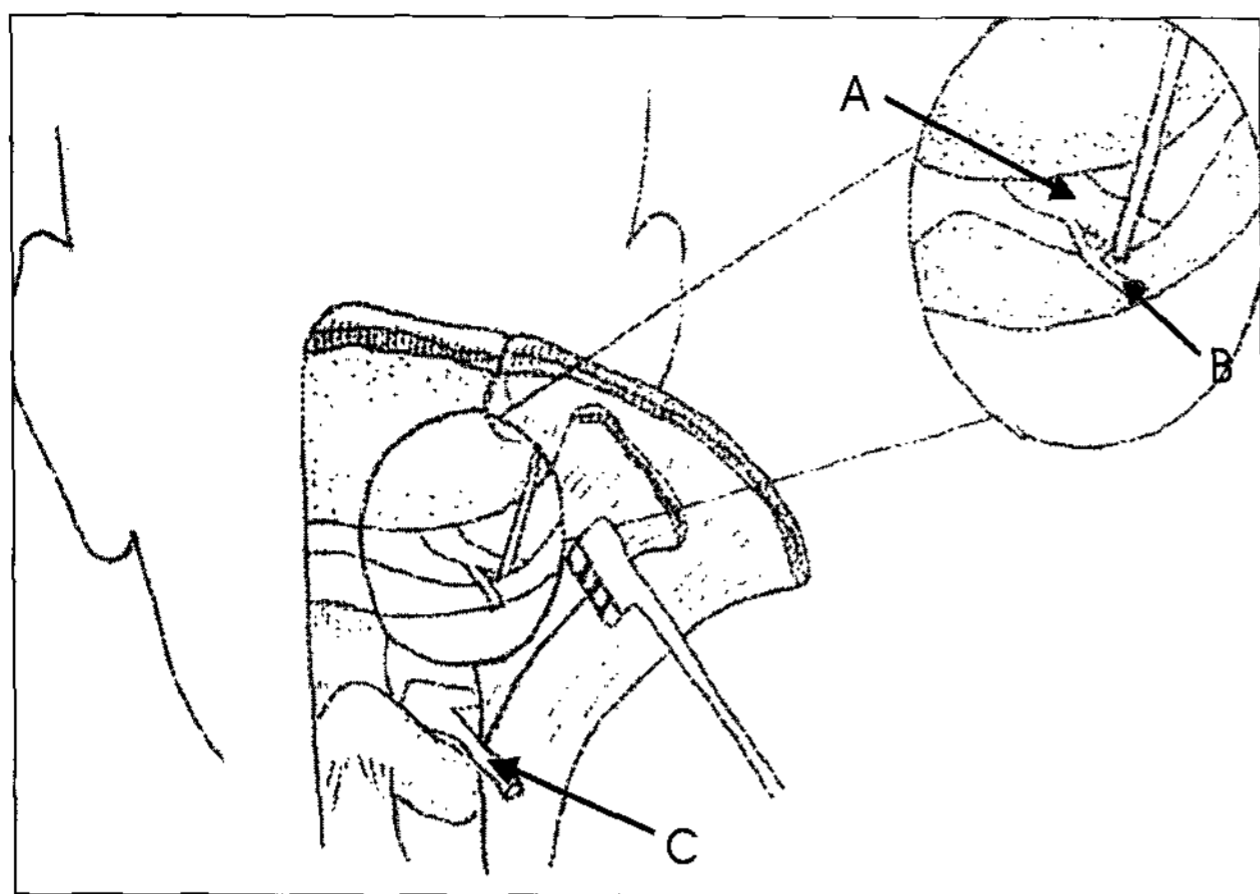


Fig. 2. Schematic drawing of right C1, 2 rhizotomy. It shows the inverted 7 shaped skin incision and the emergence of C1 underneath the vertebral artery on the right. In the circle, the vertebral artery is elevated showing the C1 as divided into anterior and posterior branches. Lower down, between the posterior arch of C1 and C2, it shows the root of C2 as it divides into its anterior and posterior branch, the latter emerges between the arches. A : Vertebral artery, B : C1 Root, C : C2 Root.

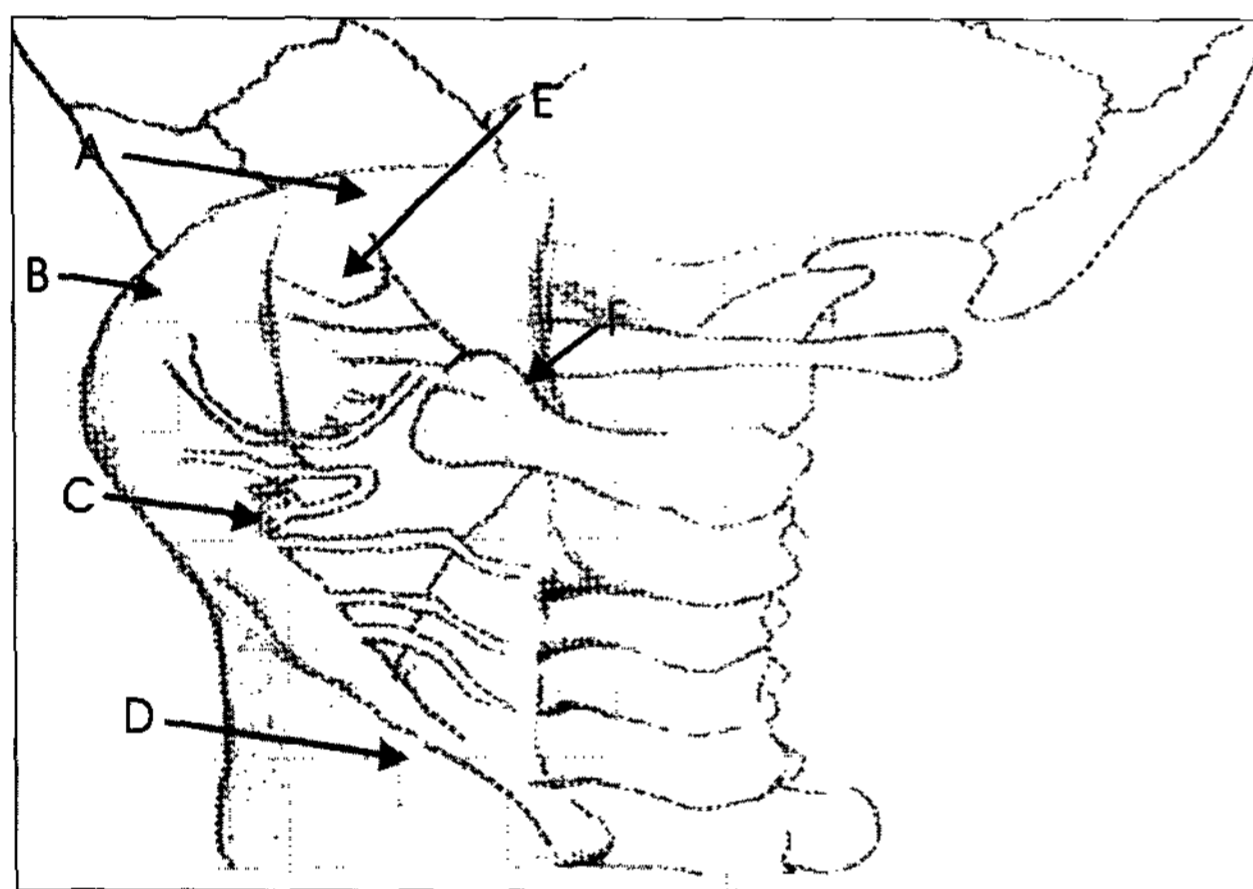


Fig. 3. Schematic drawing of left C3-C6 posterior ramisectomy. The sectioned splenius and semispinalis capitis are retracted laterally. Posterior primary divisions (rami) emerge from the intervertebral foramen, and they give rises to fine collaterals. A : Trapezius muscle : sectioned, B : Splenius capitis muscle : sectioned. C : Semispinalis capitis muscle, D : Splenius cervicis muscle, E : Rectus capitis posterior major muscle, F : Inferior oblique muscle.

monitoring is required because the phrenic nerves can be damaged (Fig. 2, 3). As suppressing pain is utmost important after the surgery, the relatively weakened opposite muscles must receive rehabilitation and physical treatment as quickly as possible.

Results

The results of the neck muscle tonogram showed that in the case of pure rotational spasmodic torticollis, the ipsilateral posterior neck muscles on the side of rotation had developed hyperactivity, accordingly, the contralateral SCM

muscle also developed hyperactivity. In cases of rotation combined with retrocollis, patients developed bilateral posterior neck muscle hyperactivity as well as contralateral SCM muscle hyperactivity. Also, in cases of rotation combined with laterocollis, patients developed bilateral SCM muscle hyperactivity as well as ipsilateral posterior neck muscle hyperactivity.

Operative results were assessed by original Bertrand's method²⁾, with "excellent" condition applying to results with absolutely no dystonia, "good" for results in which there was slight inclination or movement in which no treatment was required, "fair" for results in which there was symptom relief but abnormal movements were present or continuous medical treatment was required, and "poor" for results where there was no effect or the condition was worsened. Under this classification, 5 patients were classified as excellent (50%), 4 patients classified as good (40%), and 1 patient classified as fair (10%). 90% of the patients showed favorable results (Table 3). Typically, pure rotational cases yielded 1 patient as excellent (25%), 2 patients as good (50%), and 1 patient as fair (25%), while rotational combined with retrocollis cases yielded 2 patients as excellent (67%) and 1 patient as good (33%), and rotational combined with laterocollis cases yielded 2 patients as excellent (67%) and 1 patient as good (33%). Although statistically not significant, combined types yielded better results than pure rotational cases. The patients' age and symptom periods did not affect the results of the surgeries significantly. Also, of the 6 patients who received botulinium toxin injections, 5 patients showed good response in the early stages, of which 3 patients showed "excellent" classification results. The one patient that did not show positive response developed "fair" classification results. Although the effect of botulinium toxins and the results of the surgeries were statistically insignificant, there was some degree of proportional relationship (Table 3, Fig. 4). All of the patients experienced reductions in aching, and 7 patients did not require analgesics or muscle relaxants after surgery, however overlapping pain from incisions in the early postoperative periods had a tendency to aggravate aching. It took about 2 months (2.2 ± 1.3 months) for post-surgical pain to completely disappear. The other 3 patients required analgesics or muscle relaxants. After the surgery, the patients were followed-up for about 36 months (35.7 ± 20.6 months). "Excellent" cases required a mean of 3.5 ± 2.2 months for symptoms to completely vanish. The mean time period of post-surgical physical treatment and rehabilitation was 4.2 ± 2.7 months.

Post-surgical complications were not serious, but 2 cases of infection in the incision, 1 case of delirium, and 1 case of generalized weakness developed. The most serious case of infection of the incision required a skin transplant. Temporary neuralgia at the occiput disappeared in 3 months. Thus far,

Table 3. Types of spasmodic torticollis and operative procedures and results on each patients

Sex/Age	Type	Side	Sx.	Operation	F/U(Mos)	Result
F/41	R+L	Lt.	40	Rt. 11 th nerve denervation, myotomy +Selective rhizotomy on Lt. C1,2, Post. Ramisectomy on C3-6	64	E
F/62	R+L	Rt.	16	Bilat.11 th nerve denervation, myotomy +Selective rhizotomy on Rt. C1,2, Post. Ramisectomy on C3-6	52	E
M/67	R	Rt.	22	Lt. 11 th nerve denervation, myotomy +Selective rhizotomy on Rt. C1,2, Post. Ramisectomy on C3-6	50	G
F/51	R	Lt.	51	Rt. 11 th nerve denervation, myotomy +Selective rhizotomy on Lt. C1,2, Post. Ramisectomy on C3-6	46	F
F/42	R+R*	Lt.	32	Rt. 11 th nerve denervation, myotomy +Selective rhizotomy on Both C1,2, Post. Ramisectomy on Lt. C3-6	44	E
F/45	R	Rt.	62	Lt. 11 th nerve denervation, myotomy +Selective rhizotomy on Rt. C1,2, Post. Ramisectomy on C3-6	40	G
M/55	R+R*	Rt.	25	Lt. 11 th nerve denervation, myotomy +Selective rhizotomy on Both C1,2, Post. Ramisectomy on Rt. C3-6	36	G
M/53	R	Rt.	25	Lt. 11 th nerve denervation, myotomy +Selective rhizotomy on Rt. C1,2, Post. Ramisectomy on C3-6	10	E
M/68	R+L	Rt	34	Bilat.11 th nerve denervation, myotomy +Selective rhizotomy on Rt. C1,2, Post. Ramisectomy on C3-6	8	G
M/40	R+R*	Lt.	6	Rt. 11 th nerve denervation, myotomy +Selective rhizotomy on Both C1,2, Post. Ramisectomy on Lt. C3-6	7	E

Sx. : symptom duration , months, F/U : follow-up, months, M : male, F : female, R : rotational type, R* : retrocollis, L : laterocollis, Rt.: right, Lt.: left, E : Excellent ; showed no detectable abnormal movements, G : Good ; showed slight residual deviation or slight residual abnormal movement without treatment, F : Fair ; appreciable residual abnormal movements

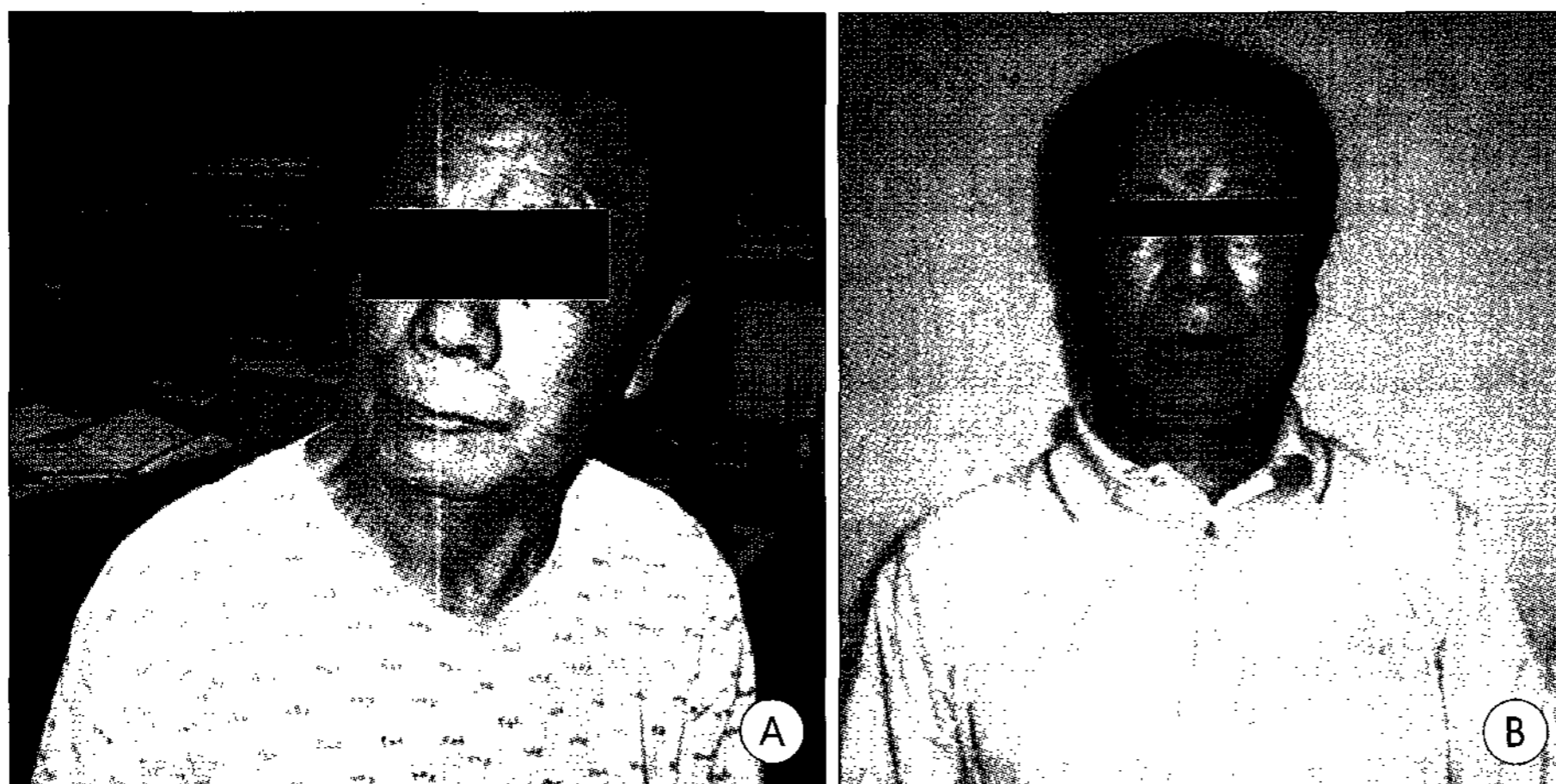


Fig. 4. Photograph showing a preoperative feature of a patient with rotational combined with retrocollis (A) and 2months after selective rhizotomy and denervation feature that normalized neck posture (B).

there have been no cases of symptom relapses which were classified as “excellent” or “good” or diminished treatment effects.

Discussion

As the initial treatment of spasmodic torticollis, most hypertonic muscles responded well to the botulinum toxins. However, there was limitation of botulinum injection because of the antibody production after repeated injections. When the effects of repeated injections diminished or when the patient does not want repeated injections, we can consider surgery. When considering surgery, it will require at least 1~2years to rule out generalized dystonia^{1,4,5,7,12}.

There have been attempts of accessory nerve microvascular decompression, thalamotomy, and spinal cord stimulation. As well, the intradural or extradural procedures contributed significantly to the development of denervation procedures. In the early period, having not yet established an accurate understanding of pathophysiology of spasmodic torticollis, a variety of surgeries that were destructive towards the intradural central nervous system and the peripheral nervous system were conducted. In the year 1923, Cushing¹⁾ performed intradural high cervical rhizotomy and accessory nerve resection. In 1930, Dandy⁸⁾ performed bilateral C1-C3 rhizotomy and accessory nerve resection simultaneously. Although diverse intradural procedures were conducted after these procedures, and although the effects of torticollis treatments were not satisfactory, serious surgical complications such as cervical instability, difficulty in swallowing, weakness

in shoulder elevation, or phrenic nerve paresis have become problems. This resulted from anterior high cervical rhizotomy, and consequently the surgery could not be completed on the C4-C6 rhizotomy because of the risk of phrenic nerve damage. Also, because intraoperative EMG monitoring was not properly carried out, the nerve root selection was not accurate^{2,11,15}.

Under these historical backgrounds, Bertrand¹⁻³) attempted extradural selective rhizotomy in 1982 with reports of high success rates and low complication rates. Afterwards, although other institutes and neurosurgeons modified Bertrand's method, they recognized it as the best surgical treatment for spasmodic torticollis. The basic concept is selective denervation of individual muscles of the hyperactive condition. As a result, the denervation procedure requires different surgical incision according to the involved muscles. The key points of successfully solving Bertrand's method are : 1) proper patient selection, 2) meticulous and accurate denervation, and 3) intensive and rigorous immediate post-surgical rehabilitation. Possible post-surgical complications include hypesthesia on the C2 dermatome, occipital pain^{1,2,15}.

Davis⁷), Braun, and Richter⁵) modified Bertrand's method by making the incision in a straight vertical line. The purpose of this was to be able to see both sides, however increased retraction was required, which would in turn cause neurapraxia. Taira and Hori¹⁴) reported superior alternative processes of Bertrand's method in order to prevent hypesthesia on the C2 dermatome and bleeding from the venous plexus. Waltz¹⁷) and Dieckmann⁹) reported 60~70% symptom relief by spinal cord stimulation, but this procedure could not improve the physiological neck movement. Freckmann and his colleagues¹⁰) performed microvascular decompression on accessory nerves and reported several successful cases, but their concepts were not suitable to the pathophysiology of spasmodic torticollis. Chen and his colleagues⁶) performed extensive myomectomy and reported successful rates, however their method would cause limitations of neck movement.

Conclusion

The authors consider that diagnosis of accurate types of spasmodic torticollis and selecting the most suitable surgical procedure for each patients are the most important

factors for the surgical success. In order to these, preoperative and intraoperative electrical monitoring is essential. Postoperative rigorous physical and rehabilitation therapy is another important factor.

This study confirms that selective denervation for the treatment of spasmodic torticollis is a very useful and safe surgical technique.

References

- Bertrand C, Molima Negro P, Martinez SN : Technical aspects of selective peripheral denervation for spasmodic torticollis. *Appl Neurophysiol* 45 : 326-330, 1982
- Bertrand CM: Operative management of spasmodic torticollis and adult-onset dystonia with emphasis on selective denervation, in Schimideck HH, Sweet WH (eds) : *Operative Neurosurgical Techniques, Indications, Methods and Results*, ed 2, Orlando : Grune & Stratton, 1988, Vol2, pp1261-1269
- Bertrand CM : Selective peripheral denervation for spasmodic torticollis : surgical technique, results, and observations in 260cases. *Surg Neurol* 40 : 96-103, 1993
- Braun V, Richter HP: Selective peripheral denervation for the treatment of spasmodic torticollis. *Neurosurgery* 35: 58-63, 1994
- Braun V, Richter HP : Selective peripheral denervation for spasmodic torticollis: 13-year experience with 155patients. *J Neurosurg (Suppl 2)* 97 : 207-212, 2002
- Chen XK, Ji SZ, Zhu GH, Ma AB : Operative treatment of bilateral retrocollis. *Acta Neurochir* 113 : 180-183, 1991
- Cohen-Gadol AA, Ahlskog JE, Matsumoto JY, Swensen MA, Mc Clelland RL, Davis DH : Selective peripheral denervation for the treatment of intractable spasmodic torticollis : experience with 168 patients at the Mayo Clinic. *J Neurosurg* 98 : 1247-1254, 2003
- Dandy WE : An operation for treatment of spasmodic torticollis. *Arch Surg* 20 : 1021-1032, 1930
- Dieckmann G, Veras G : Bipolar spinal cord stimulation for spasmodic torticollis. *Appl Neurophysiol* 48 : 339-346, 1985
- Freckmann N, Hagenah R, Herrmann HD, Muller D : Bilateral microsurgical lysis of the spinal accessory nerve roots for treatment of spasmodic torticollis. Follow up of 33cases. *Acta Neurochir* 83 : 47-53, 1986
- Friedman AH, Nashhold BS Jr, Sharp R, Caputi F, Arruda J : Treatment of spasmodic torticollis with intradural selective rhizotomies. *J Neurosurg* 78 : 46-53, 1993
- Rondot P, Marchand MP, Dellatolas G : Spasmodic torticollis- review of 220patients. *Can J Neurol Sci* 18 : 143-151, 1991
- Son BC, Kim MC, Lee KS, Park CK : Botulinum toxin a for spasmodic torticollis, hemifacial spasm and facial synkinesis. *J Korean Neurosurg Soc* 31 : 600-604, 2002
- Taira T, Hori T : Peripheral neurotomy for torticollis : A new approach. *Stereotact Funct Neurosurg* 77 : 40-43, 2001
- Taira T, Kobayashi T, Takahashi K, Hori T : A new denervation procedure for idiopathic cervical dystonia. *J Neurosurg (Suppl 2)* 97 : 201-206, 2002
- Tsui JK, Eisen A, Mak E, Carruthers J, Scott CA, Calne DB : A pilot study on the use of botulinum toxin in spasmodic torticollis. *Can J Neurol Sci* 12 : 314-316, 1985
- Waltz JM : Spinal cord stimulation for palsies? *Patient care* 13 : 188-206, 1979