

Epidermoid Cyst of the Fourth Ventricle

Ji Young Jeon, M.D., Jae Min Kim, M.D., Ph.D.,
Jin Hwan Cheong, M.D., Ph.D., Choong Hyun Kim, M.D., Ph.D.

Department of Neurosurgery, Hanyang University, Guri Hospital, Guri, Korea

The authors describe a case of intracranial epidermoid cyst with fourth ventricle involvement. A 43-year-old woman presented with progressive aggravating headache and cerebellar syndrome due to a large tumor in the fourth ventricle, that extended into the left side of foramen of Luschka. The histopathological workup following gross total removal of tumor had revealed the typical features of an epidermoid cyst. Four months after surgery, the cerebellar signs recovered to normal with a remarkable improvement of headache. Epidermoid cysts involving the fourth ventricle have been known to be one of the most rare diseases in the central nervous system. This rare case is discussed and a review of the relevant literature is presented.

KEY WORDS : Epidermoid cyst · Fourth ventricle.

Introduction

Epidermoid cysts (ECs) or tumors, known as pearly tumors or cholesteatomas, are uncommon benign lesions that may arise in the spine or intracranially, and the intracranial type accounts for approximately 1% of intracranial tumors¹⁵⁾. Recently, the development of ECs has been known to be ectopic inclusions of surface ectoderm during the gestational period of neural closure, and most authors consider ECs to be congenital malformations rather than true neoplasms^{11,14)}. They usually occur in the cerebellopontine angle or in the parasellar regions^{9,10)}. Intracerebral cysts account for less than 2% of intracranial type and especially ECs of the fourth ventricle occur very rarely, with less than a dozen reported in the literature^{8,18)}.

We have experienced a patient who had EC within the fourth ventricle with surgical management. Thus we report this rare case and discuss about the clinical importance with reviews of the literature.

Case Report

43-year-old woman presented with a dull headache and vomiting. The nature of headache was deep-seated, vaguely localized. It had become progressively aggravated and then intractable to non-narcotic analgesics prescribed in primary

health care clinic for last one year. She had also suffered from subjective gait disturbance during last 6 months.

On the neurological examination, she was able to maintain the truncal balance regardless of her eye opening (negative Romberg test). However, she had tendency to deviate rightward during tandem-gait test. The brain magnetic resonance image (MRI) disclosed an intraventricular cystic mass mainly located in the fourth ventricle with extension into the left side of the foramen of Luschka. The tumor signal showed hypointensity without definite enhancing rim on T1-weighted, hyperintensity on T2-weighted and heterogenous intensity on fluid-attenuated inversion recovery (FLAIR) image. The ventricular system, which was above the foramen of Magendie was dilated markedly (Fig. 1).

On operation, the patient was placed in Concord prone position with the head held by using the head clamp under the general anesthesia. After positioning the patient, operative procedures were performed via midline suboccipital approach. The dura was incised in a stellate shape, and both cerebellar tonsils and hemispheres were gently retracted laterally. As the tumor could come into view of the microscopic field, the tumor measured about 3.5 × 3.0 × 5.2 cm in dimension and had the typical smooth glistening, "mother-of-pearl" appearance. It adhered to the ventral rhomboid fossa with the confines of about 1.5 cm leftward, 0.5 cm rightward across the dorsal median sulcus, and 1.0 cm superior, 0.5 cm inferior to the striae

• Received : May 19, 2005 • Accepted : July 21, 2005

• Address for reprints : Jae Min Kim, M.D., Ph.D., Department of Neurosurgery, Hanyang University, Guri Hospital, 249-1 Gyomun-dong, Guri 471-701, Korea Tel : +82-31-560-2323, Fax : +82-31-560-2327, E-mail : kjm2323@hanyang.ac.kr

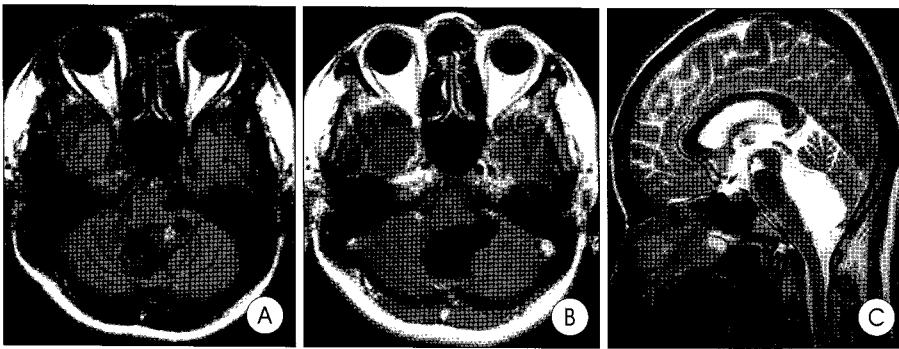


Fig. 1. FLAIR (A), Gd-enhanced T1-weighted axial (B) and T2-weighted sagittal (C) images on admission: The epidermoid cyst occupies the fourth ventricle in which it grows and compresses the surrounding cerebellar hemispheres. It shows hypointensity without definite enhancing rim on T1-weighted, hyperintensity on T2-weighted and heterogenous signal intensity, between cerebrospinal fluid and the brain parenchyme on FLAIR image. The tumor also extends to the left-sided foramen of Luschka, and hydrocephalic change is noted.

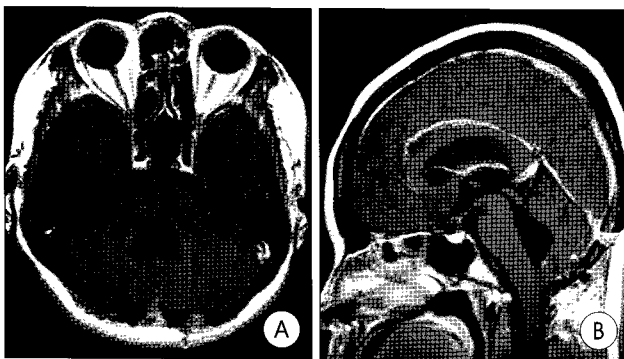


Fig. 2. Postoperative follow-up Gd-enhanced T1-weighted axial (A), and sagittal images (B): after gross total removal of the epidermoid cyst, the fourth ventricle restored to normal contour. However, the previous dilated ventricular size does not come back to normal.

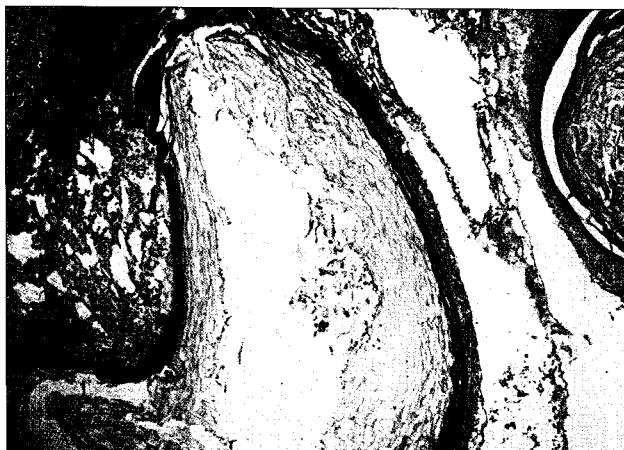


Fig. 3. Photomicrographs demonstrating histopathological features of the epidermoid cyst: The wall consists of a layer of stratified squamous epithelium surrounded by a thin layer of connective tissue. The cyst contains structureless, waxy, keratinous material which is desquamated epidermal cellular debris. (H & E, original magnification $\times 100$).

medullaris. It was also adherent to dorsal roof loosely, and grew into the left side of foramen of Luschka. The tumor capsule was incised and cyst contents were sucked out and took out

as a piecemeal fashion not to overflow into the cerebrospinal fluid (CSF) pathway. After the internal debulking of the cyst, adherent portion of the tumor capsule was dissected with care, and it could be extirpated totally. The tumor capsule loosely adhered to the ependymal layer of rhomboid fossa. At the end of surgery, the patency of CSF pathway including the foramen of Luschka and aqueduct of Sylvius was confirmed microscopically. The surgical field and the adjacent cisterns were irrigated

with hydrocortisone (2g) before the dural closure. During the postoperative period, steroid (hydrocortisone, 20mg/day) was administrated intravenously for 2 weeks and tapered by oral steroid (hydrocortisone, 10mg/day) for 1 week, then stopped.

Four months after surgery, the patient's neurological status has improved with disappearance of truncal ataxia. The intensity of headache was decreased markedly, and the headache subsided finally. On the followed-up brain MRI, there was no remnant tumor mass, however ventricular system was dilated persistently (Fig. 2). The histopathological examination confirmed the epidermoid cyst in the fourth ventricle (Fig. 3).

Discussion

The first case of EC was reported by Duverney in 1683¹². Thereafter, Remak¹³ deduced their ectodermal origin and first used the term "epidermoid", and epidermoid tumors and other related inclusion phenomena have been well documented. The pathogenesis of ECs are explained as primarily a gastrulation dysembryogenesis, with secondary disruption of neural tube closure, during the third to fifth week of gestation^{3,5}. Such a reason, ECs are generally considered to be congenital malformations rather than true neoplasms^{11,14}.

It is well known that ECs have no gender preponderance and the onset of symptom is mostly in the third to fifth decades because of their slow evolutionary potential^{1,6}. Generally, tumors of the fourth ventricle and cerebellum (usually medulloblastoma, ependymoma, or occasionally metastasis) interfere with CSF circulation, and symptoms of increased pressure appear early. However in ECs, a distinct insidious growth pattern allow them flow across the basal surface of brain into the subarachnoid space and only in later stage of growth they behave as expanding lesions, remaining clinically silent for many years^{1,14}. At the time of diagnosis, ECs typically infiltrate sulci and cisterns, displace parenchyme, and engulf cranial

nerves and vessels¹⁷). Particularly, ECs in posterior fossa are often the most troublesome to be removed because of their insinuating growth into vital structures, difficult to reach in a single stage¹⁶. ECs may be found in the spine or cranium, and the intracranial type constitute 0.5% to 1.8% of all brain tumors¹⁵. The parasellar and cerebellopontine angle regions are the most common site, but ECs have been infrequently detected in the fourth and lateral ventricles, cerebellum and brain stem^{2,9,10,16}. Reviewing the literature, we concluded that ECs involving the fourth ventricle have been scarcely described with less than a dozen of reports.

Current recommendations for surgical approach are similar to those of Love and Kernohan in 1936, including primary intracapsular debulking and subsequent removal of the capsule⁷. As concerned above, their adhesive nature to the important structures sometimes make it impossible, therefore it is advocated that complete resection is unwise and should be avoided². Subtotal resection may increase the risk of recurrence, but the rates are often so slow that the patient may not become problematic during the life span. Talacchi et al.¹⁶ reported the surgical results of 28 posterior fossa epidermoids. Total removal was accomplished in 16 patients (57%), capsule fragments attached to neurovascular structures were remained in 4 patients (14%), and distant tumor fragments were left in situ in 8 patients (29%). Five cases harbored tumors in the fourth ventricle usually present higher operative risk because of their adhesion to the brain stem. Among them, the total removal was possible in 3 patients, and subtotal removal was accomplished in the others as the same cause. Two patients presented with gait ataxia improvement (accompanied by either a worsening or a developing fourth cranial nerve palsy), two patients were unchanged, and the remaining patient died from respiratory failure complicated by bronchopneumonia.

The cyst contents, rich in cholesterol and fatty acids, are highly irritating to the meninges⁴. During the surgical resection of cysts, these contents can leak into the CSF pathway, and that may evoke attacks of aseptic meningitis². It can be often prevented by careful dissection of ECs with less spillage of their contents, use of hydrocortisone irrigating solutions during operation and gradual tapering of steroids for several weeks².

In our case, presenting symptoms which were developed by cerebellar compression and obstruction of CSF pathway occurred in the average age of onset time that could be explained well by the slow growing nature of ECs. And radiologic and intraoperative microscopic findings were also appropriate to them of typical ECs. Although the propensity for adhesion to surrounding structures made the operation more difficult, we could remove the cyst successfully without any significant neurological sequela. As we had taken greater care to keep out the gross spillage of intracystic materials by careful suction tech-

nique and used prolonged postoperative steroid. It seems to be the main reason to prevent the apprehended aseptic meningitis.

Conclusion

Although ECs involving the fourth ventricle are extremely rare, they should be considered in the differential diagnosis of the intraventricular tumor, especially in the fourth ventricle. The dense attachment to surrounding structures is one of the major hazards to surgical treatment. Extensive lesions, incomplete initial resection, and limited initial exposure are considered as the primary causes of recurrence. An initial incomplete excision is unlikely to achieve definitive tumor cure. The higher the rate of subsequent operations, the less satisfactory is the outcome for reversal of neurological symptoms. Despite the refutations, we suggest that complete resection of the ECs should be attempted as carefully as possible, since it make this entity be a curable disease.

References

1. Alvord EC : Growth rates of epidermoid tumours. *Ann Neurol* 2 : 367-370, 1977
2. Berger MB, Wilson CB : Epidermoid cysts of the posterior fossa. *J Neurosurg* 21 : 1051-1058, 1984
3. Dias MS, Walker ML : The embryogenesis of complex dysraphic malformation : A disorder of gastrulation? *Pediatr Neurosurg* 18 : 229-253, 1992
4. Ellner JJ, Bennett JE : Chronic meningitis. *Medicine* 55 : 341-369, 1976
5. Gormley WB, Tomecek FJ, Qureshi N, Malik GM : Craniocerebral epidermoid and dermoid tumours : a review of 32 cases. *Acta Neurochir (Wien)* 128 : 115-121, 1994
6. Guidetti V, Gagliardi FM : Epidermoid and dermoid cysts. Clinical evaluation and late surgical results. *J Neurosurg* 47 : 12-18, 1977
7. Gumerlock MK : Epidermoid, dermoid, and neurenteric cysts in Winn HR (eds) : *Youmans Neurological Surgery*, ed 5. Philadelphia : WB Saunders, 2004, Vol 1, pp1223-1230
8. Iaconetta G, Carvalho GA, Vorkapic P, Samii M : Intracerebral epidermoid tumor : a case report and review of the literature. *Surg Neurol* 55 : 218-222, 2001
9. Kim JS, Jung HW, Lee SH, Chung YS, Kim HJ, Choi KS, et al : Surgical outcome of intracranial epidermoid cysts. *J Korean Neurosurg Soc* 24 : 876-881, 1995
10. Lee YS, Lee CR, Hwang SS, Kim SC : A case of epidermoid cyst in the fourth ventricle. *J Korean Neurosurg Soc* 16 : 1227-1233, 1987
11. Niikawa S, Hara A, Zhang W, Sakai N, Yamada H, Shimokawa K : Proliferative assessment of craniopharyngioma and epidermoid by nucleolar organizer region staining. *Childs Nerv Syst* 8 : 453-456, 1992
12. Peron DL, Schuknecht HF : Congenital cholesteatomata with other anomalies. *Arch Otolaryngol* 101 : 498-505, 1975
13. Remak R : Ein Beitrag zur Entwicklungsgeschichte der krebshaften Geschwulste. *Dtsch Arch Klin Med.* 6 : 170, 1854
14. Russel DS, Rubinstein LJ : Dermoid and epidermoid cysts, in Russel DS and Rubinstein LJ (eds) : *Pathology of Tumours of the Nervous System*, ed 5. London : Edward Arnold, 1989, pp 690-702
15. Sabin HI, Bordi LT, Symon L : Epidermoid cysts and cholesterol granulomas centered on the posterior fossa : twenty years of diagnosis and management. *Neurosurgery* 21 : 798-805, 1987
16. Talacchi A, Sala F, Alessandrini F, Turazzi S, Bricolo A : Assessment and surgical management of posterior fossa epidermoid tumors : report of 28 cases. *Neurosurgery* 42 : 242-251, 1998
17. Yasargil MG, Abernathy CD, Sarioglu AC : Microneurosurgical treatment of intracranial dermoid and epidermoid tumors. *Neurosurgery* 24 : 561-567, 1989
18. Yoshizato K, Kai Y, Kuratsu J, Ushio Y : Intramedullary epidermoid cyst in the brain stem : case report. *Surg Neurol* 45 : 537-540, 1996