

A Case of Hypocomplementemic Henoch-Schönlein Purpura Presenting Features of Membranoproliferative Glomerulonephritis

Kyong-A Lee, M.D. and Tae-Sun Ha, M.D.

Department of Pediatrics, College of Medicine, Chungbuk National University, Cheongju, Korea

Henoch-Schönlein purpura (HSP) is a systemic disorder characterized by leukocytoclastic vasculitis that can affect multiple organs predominantly the skin, joints, gastrointestinal tract and kidney. Although the specific pathogenesis of HSP is not known, there are several hypotheses. Although the importance of the complement activation in glomerular injury in HSP has been suggested, the complement levels and the blood pressure in those patients are usually normal and massive proteinuria is not common. And pathologic renal changes also have been reported to show a large variety of glomerular changes. However, to our knowledge, a membranoproliferative glomerulo-nephritis (MPGN) is a rare renal clinicopathologic manifestation of HSP. We report a 6-year-old boy with HSP who developed MPGN with hypertension, massive proteinuria, and hypo-complementemia revealed activation of the classical complement pathway, although we could not exclude the possibility of other hypocomplementemic glomerulonephritis including post-streptococcal acute glomerulonephritis. (**Korean J Pediatr 2005;48:81-84**)

Key Words : Henoch-Schönlein purpura, Hypocomplementemic glomerulonephritis, membranoproliferative glomerulonephritis

Introduction

Henoch-Schönlein purpura (HSP) is a systemic vasculitis of the small blood vessels involving multiple organs and is well described in children^{1, 2)}. The typical clinical manifestations of HSP include non-thrombocytopenic purpura, arthralgia, abdominal pain, and glomerulonephritis with predominant mesangial proliferation and deposit of IgA^{1, 2)}. However, a membranoproliferative glomerulonephritis (MPGN) is a rare renal clinicopathologic manifestation of HSP^{1, 3-5)}.

Although complement activation is thought to play an important role in the pathogenesis of HSP^{6, 7)}, a low serum level of C3 and/or C4 is very unusual^{6, 8)}. We report a child with HSP accompanied by typical features of clinical

course, such as, hypertension, hypocomplementemia, and massive proteinuria, and the pathologic findings of MPGN.

Case Report

A 6-year-old boy presented purpuric rash of the lower extremity with abdominal pain and arthralgia involving the knees and ankles, following upper respiratory infection. His previous medical history was unremarkable. After admission, abdominal pain and arthralgia were slightly relieved after oral steroids, but gross hematuria was seen. Positive findings on physical examination were mild periorbital swelling, pretibial and ankle edema, and fine non-palpable purpuric lesions over the calves and buttocks. Blood pressure was 100/60 mmHg. Clinical and laboratory course of this patient is shown in Fig. 1.

Laboratory evaluation on admission revealed a normal complete blood count, normal serum electrolytes concentrations, blood urea nitrogen 25 mg/dL, creatinine 0.7 mg/dL, protein 6.0 g/dL, albumin 2.9 g/dL, and cholesterol 201 mg/dL. Coagulation and liver enzyme studies were within normal limits. Tests for antinuclear antibody and serum rheu-

This work was supported by Chungbuk National University grant in 2004.

접수 : 2004년 8월 10일, 승인 : 2004년 9월 23일
책임저자 : 하태선, 충북대학교 의과대학 소아과학교실
Correspondence : Tae-Sun Ha, M.D.

Tel : 043)269-6374 Fax : 043)264-6620
E-mail : tsha@chungbuk.ac.kr

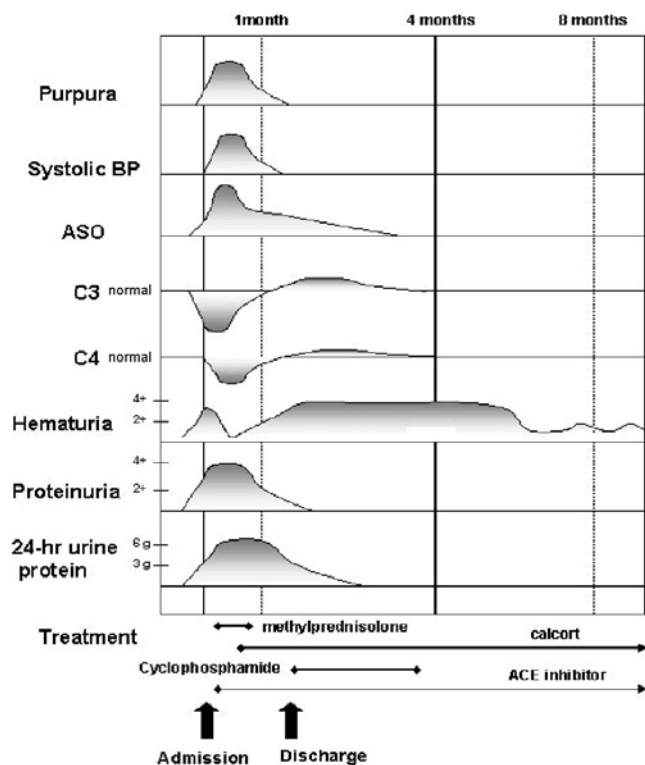


Fig. 1. Clinical and laboratory presentations during the course of case.

matoid factor were negative, but antistreptolysin-O was 2,099 IU/mL. Serum concentrations of C3 and C4 were low at 52 mg/dL and 3 mg/dL, respectively. Serum concentrations of IgG and IgA were 1,774 mg/dL and 167 mg/dL, respectively. The urinalysis revealed many red and white blood cells per high power field and albuminuria of ++++ on albustix. Dysmorphic RBC in urine was 59% and a 24-hr urine sample had 6,710 mg protein/day.

Because of severe proteinuria over 5,000 mg/day, a percutaneous renal biopsy was performed on the second day of hospitalization. The portions of 6 glomeruli were seen by light microscopy of periodic acid-Schiff-stained sections. The glomeruli showed diffuse endocapillary proliferation and thickening of capillary walls with mesangial cell proliferation and matrix expansion. The tubules, blood vessels and interstitium were unremarkable (Fig. 2). Frozen section for immunofluorescence study contained no glomerulus. An electron microscopic study revealed mesangial cell proliferation with subendothelial electron dense deposits as well as mesangial deposits (Fig. 3). Intervening subepithelial spikes were not seen and most of foot processes of podocytes were relatively well preserved if partially effaced portions were excluded.

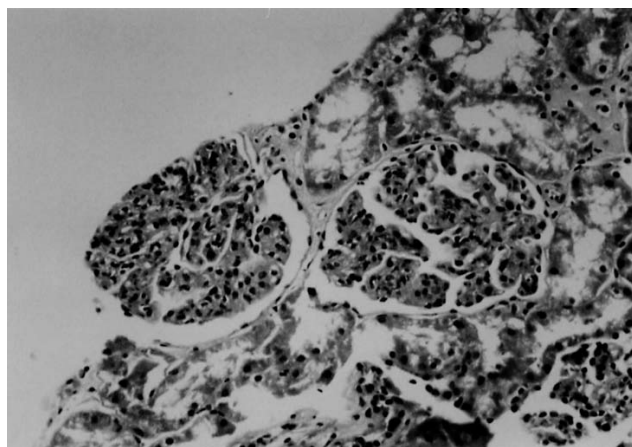


Fig. 2. Light microscopy of glomeruli showing moderate increase of the mesangial matrix and thickened capillary loops (haematoxylin and staining, $\times 100$).

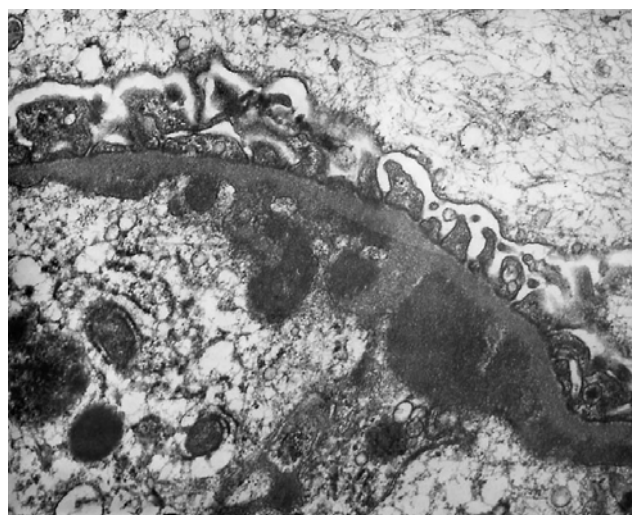

Fig. 3. Electron microscopy showing diffuse subendothelial electron dense deposits ($\times 50,000$).

On the third day of hospitalization, blood pressure increased to 130/90 mmHg. Because severe proteinuric HSP nephritis was diagnosed, alternate-day intravenous high-dose methyl-prednisolone therapy (30 mg/kg/day) and angiotensin converting enzyme inhibitor were started from on the fourth day of hospitalization. Thereafter, his urine abnormalities gradually improved. Serial 24-hr urine protein excretion performed on the ninth, thirteenth, and seventeenth hospital days were 5,355 mg/dL, 4,680 mg/dL, and 3,300 mg/dL, respectively (Fig. 1). Although the severity of the proteinuria was improved, proteinuria remained. We changed intravenous methylprednisolone to oral cyclophosphamide because hypertension was probably worsened with high dose intravenous steroid.

Thereafter urine protein excretion has much improved and returned to normal three months later.

The levels of C3 and C4 were normalized to 52 mg/dL and 3 mg/dL on the hospital day 22, and the blood pressure was normalized on the hospital day 23 (Fig. 1). The follow-up renal biopsy was not performed. Up to now we have followed up urinalysis and renal function and the result has been within normal range.

Discussion

Henoch-Schönlein nephritis (HSN) may be caused by an immune-mediated vasculitis, and pathological features of the disease are similar to those of IgA nephropathy characterized by focal or diffuse mesangial cell proliferation and the predominant deposition of IgA¹⁻⁴. In the literature, to our knowledge, patients with typical clinical courses including hypertension, hypocomplementemia, and massive proteinuria, and the pathologic findings of MPGN are very rare. In this study, we report a child with HSP who showed clinical, laboratory and morphologic features of MPGN.

Pathologic renal changes have been reported to show a large variety of glomerular changes^{1-4, 8}. The histological changes of HSP have been graded according to the ISKDC (International Study Group of Kidney Disease in Childhood) classification reported by Heaton et al⁴. The following categories have been established: grade I-minimal glomerular abnormalities; grade II-pure mesangial proliferation; grade III-(a) focal or (b) diffuse mesangial proliferation with <50% crescents; grade IV-(a) focal or (b) diffuse mesangial proliferation with 50-75% crescents; grade V-(a) focal or (b) diffuse mesangial proliferation with >75% crescents, and grade VI-membranoproliferative (MP)-like lesion. MP-like lesions means that the mesangial proliferation is diffuse and the peripheral glomerular basement membranes may be duplicated, giving them an appearance resembling that of type I MPGN. However, a MP pattern had been rarely reported in patients with HSN^{1, 3-5, 8, 9}.

Heaton et al⁴ reported 2 patients with HSN, who showed a pseudo-MP pattern. Levy et al⁸ described 5 patients presenting lesions mimicking MPGN with subendothelial deposits. Counahan et al⁵ reported the outcome of 8 patients with HSN, already described in a previous study¹.

Yoshikawa et al² reported 83 children with HSN and only 1 patient presented grade VI. Orfila et al⁹ reported a patient who showed clinical, laboratory and morphologic

features consistent with the diagnosis of HSP with the characteristics of MP-like lesion (grade VI). Krause et al¹⁰ presented a child with HSP accompanied by a low serum level of C3 but not C4, leukopenia, and thrombocytopenia who developed diffuse proliferative nephritis and subsequently end-stage renal failure. However, to our knowledge, patients with MPGN of HSN having undergone complete studies resulting hypocomplementemia, hypertension, and the pathologic findings of MPGN could hardly be seen.

Although several studies have demonstrated activation of C3 and C4 in tissue damage in HSP^{6, 7}, they failed to reveal low concentrations of C3 and C4^{6, 11}. Levy et al⁸ reported low serum C1q in 11 out of 32 children with acute HSP and low serum level of C4 levels in 6, suggesting classical pathway activation. Smith et al¹² also reported low serum C4 levels in two of 25 (8%) HSP patients. Garcia-Fuentes et al⁶ and Krause et al¹⁰ each reported one HSP patient with low serum C3. Islek et al¹³ found low serum C3 in 8% of HSP patients, however, this did not correlate with the severity of the renal involvement in patients with hematuria and proteinuria who recovered within 3-6 weeks. They believe that low serum C3 and/or C4 is not an unusual finding in HSP and supports the hypothesis that complement is activated in HSP. However, they failed to find any correlation between the serum complement concentrations and MPGN. West¹⁴ reported that hypocomplementemia was found in all types of MPGN but not in all patients based on the fact that the frequency of hypocomplementemia was 68% of those with MPGN I, 82% with MPGN II, and 84% with MPGN III. Also he suggested that hypocomplementemia at presentation was not a prognostic indicator because the hypocomplementemia disappeared rapidly with initiation of an alternate-day prednisone regimen but in might, for unknown reasons, persist in a few patients despite adequate dosage and compliance. Complement studies in this patient reveal activation of the classical pathway of complement with decreased levels of C3 and C4 and the hypocomplementemia might disappear early due to high-dose methylprednisolone therapy. Other hypocomplementemic glomerulonephritis, including post-streptococcal acute glomerulo-nephritis (PSAGN) and lupus nephritis, might be excluded in our patient by clinical and laboratory findings. Streptococcal infection has been recognized as a possible trigger for the appearance of HSP and one case of concurrent PSAGN with a low level of C3 and HSP has been reported¹⁵, they did not show renal patho-

logic findings. Unfortunately, we could not confirm the presence of C3 or C4 deposits in immunofluorescence stainings because frozen section for IF study contained no glomeruli.

Although our patient had additional low C4 level and no definite subepithelial humps, we could not exclude the possibility of concomitant PSAGN.

In summary, this report describes a detailed study of a case presented with HSP and clinical and morphologic features consistent with MPGN. Classical complement pathway could be activated in HSP and lead to typical features of clinical course, such as, hypocomplementemia, massive proteinuria, and the pathologic findings of MPGN.

국문 요약

저 보체 혈증 및 막성 증식성 사구체 신염의 임상 상을 보인 Henoch-Schölein (Purpura) Nephritis 1례

충북대학교 의과대학 소아과학교실

이 경 아 · 하 태 선

Henoch-Schölein purpura (HSP)는 피부, 관절, 위장관 그리고 신장을 침범하는 혈관염으로 혈소판 감소증이 없는 자반증을 전형적인 증상으로 하는 질환으로 그 원인에 대하여 여러 가지 가설들이 있지만 아직 확실치 않다. HSP에서 신장 침범은 이차적으로 오는 혈관염으로 임상적으로 혈뇨와 단백뇨의 증상을 보이고 병리학적 소견은 IgA 신염과 매우 유사하다. 그 외에도 HSP 신염은 다양한 형태의 사구체 신염을 보이는데 막성 사구체 신염은 드물다. 이에 저자들은 HSP의 임상 양상을 가지면서 혈청 내 보체의 감소, 단백뇨 및 고혈압을 보이고 조직학적으로 막성 사구체 신염 소견을 보인 6세 환아를 경험하였기에 이를 문헌 고찰과 함께 보고하는 바이다.

References

- 1) Meadow SR, Glasgow EF, White RHR, Moncrieff MW, Cameron JS, Ogg CS. Schönlein-Henoch nephritis. Q J Med 1972;163:241-58.
- 2) Yoshikawa K, White RHR, Cameron AH. Prognostic significance of the glomerular changes in Henoch-Schönlein nephritis. Clin Nephrol 1981;16:223-9.
- 3) Brun C, Bryld C, Fenger L, Jorgensen F. Glomerular lesions in adults with Schönlein-Henoch syndrome. Acta Pathol Microbiol Scand [A] 1971;79:569-83.
- 4) Heaton J, Turner DR, Cameron JS. Localization of glomerular 'deposits' in Henoch-Schönlein nephritis. Histopathology 1977;1:93-104.
- 5) Counahan R, Winterborn MH, White RHR, Heaton JM, Meadow SR, Bluett NH, et al. Prognosis of Henoch-Schönlein nephritis in children. Br Med J 1977;2:11-4.
- 6) Garcia-Fuentes M, Martin A, Chantler C, Williams DG. Serum complement components in Henoch-Schönlein purpura. Arch Dis Child 1978;53:417-9
- 7) Wyatt RJ. The complement system in IgA nephropathy and Henoch-Schönlein purpura: functional and genetic aspects. Contrib Nephrol 1993;104:82-91.
- 8) Levy M, Broyer M, Arsan A, Levy-Bentolilia D, Habib R. Anaphylactoid purpura nephritis in childhood: natural history and immunopathology. Adv Nephrol 1976;6:183-228.
- 9) Orfila C, Lepert JC, Modesto A, Pipy B, Suc JM. Henoch-Schönlein purpura and membrano-proliferative-like glomerulonephritis. Nephron 1996;74:209-13.
- 10) Krause I, Garty BZ, Davidovits M, Cleper R, Tamary H, Rosenmann E, et al. Low serum C3, leukopenia, and thrombocytopenia: unusual features of Henoch-Schönlein purpura. Eur J Pediatr 1999;158:906-9.
- 11) Abou-Ragheb HHA, Williams AJ, Brown CB, Milford-ward A. Plasma levels of the anaphylatoxins C3a and C4a in patients with IgA nephropathy/Henoch-Schönlein nephritis. Nephron 1992;62:22-6.
- 12) Smith GC, Davidson JE, Hughes DA, Holme E, Beattie TJ. Complement activation in Henoch-Schönlein purpura. Pediatr Nephrol 1997;11:477-80.
- 13) Islek I, Muslu A, Dagdemir A, Dilber C. Is low serum complement 3 in Henoch Schönlein purpura unusual and of prognostic value? Eur J Pediatr 2001;160:397-8.
- 14) West CD. Idiopathic membranoproliferative glomerulonephritis in childhood. Pediatr Nephrol 1992;6:96-103.
- 15) Onisawa S, Morishima N, Ichimura T. Concurrent post-streptococcal acute glomerulonephritis and Schönlein-Henoch purpura. Acta Paediatr Jpn 1989;31:487-92.