

Effect of Nandrolone Decanoate on Disuse Muscle Atrophy and Bone Healing in Dogs

Seong-jin Yun, Ji-hey Lim, Md. Mizanur Rahman, Ye-eun Byeon, Wan-hee Kim and Oh-kyeong Kweon¹

Laboratory of Veterinary Surgery, College of Veterinary Medicine, Seoul National University, Shillim 9-dong, Kwanak-gu, Seoul 151-742, Korea

Abstract: Anabolic steroid compounds are widely used for the increase of muscle mass, density of bone and athletic ability. The present study conducted to evaluate the effects of nandrolone decanoate (ND), one of the anabolic steroid compounds, on disuse muscle atrophy and healing process of bone in dogs. Twenty physically healthy dogs of both sexes were used in this experiment and divided into three groups: group A (control), group B (low dose ND-1.5 mg/kg) and group C (high dose ND-7.5 mg/kg). One-mm strip of full thickness bone was excised from the radius below the pronator teres muscle for the artificial fracture and then the fractured ends were fixed in apposition with bone plate leaving 1 mm gap, and finally immobilized externally by Robert John's bandage for 4 weeks. ND was administered intramuscularly once a week for 8 weeks. Body weight, muscle mass change and fracture gap of the bone were evaluated immediately after surgery, and 2, 4, and 8 weeks after surgery. The rates of muscle mass change 8 weeks after surgery were $-2.75 \pm 0.16\%$, $1.68 \pm 0.11\%$ and $1.74 \pm 0.48\%$ in groups A, B and C, respectively. The significant increase ($p < 0.05$) of muscle mass increments were found in the treated groups. The fibrous connective tissue layer in the fracture gaps of the treated groups increased more than the control, especially in the group C at 4th week. More dense fibrous connective tissue were found in the treated groups at 8th week. Collectively, our results suggested that ND was an effective anabolic agent for the immobilized disuse muscle and bone healing.

Key words : nandrolone decanoate, muscle, atrophy, dog.

Introduction

Postoperative immobilization of fracture is an important technique for the quick and unhindered healing of bone. But prolonged immobilization may cause disuse muscle atrophy and reduce physiological forces^{26,29}. Delay or failure of healing in bone fracture is a common clinical problem confronting the veterinary surgeon. One of the treatment options for these problems is the administration of anabolic androgenic steroids agent.

Nandrolone decanoate (ND) therapy for patient with muscle atrophy can increase the muscle mass by protein synthesis in the skeletal muscle or connective tissue². It has been known that steroid testosterone can increase the rate of muscle protein synthesis and promote muscle development²⁴. It has also demonstrated that ND pretreatment can alter morphological and cell cycle regulator expression related to muscle growth at the onset of functional overload²⁵. The effectiveness of ND in human and rat skeletal muscles appeared to depend on its combination with exercise training⁶. It has been demonstrated that, at least partly, anabolic steroids increase the bone density by stimulating bone formation^{17,30}.

The aim of the present study is to evaluate the effects of ND on immobilized skeletal muscle atrophy and bone healing in dogs.

Materials and methods

Experimental animals

Twenty mixed breed dogs (3.3~5.5 kg and 2~4 years) were divided randomly into three groups: group A (control), group B (low dose ND, 1.5 mg/kg), and group C (high dose ND, 7.5 mg/kg). The dogs were allowed for free movement in the cage and adequate food, and water was provided *ad libitum*.

Induction of radial fracture

I) Anesthesia

General anesthesia was induced with thiopental sodium, 15 mg/kg intravenously, (Pentothal sodium[®], Joongwei Co., Korea) and maintained with 2% of isoflurane (Aerane[®], Ilsung Co., Korea). Lactated Ringer's solution with 5% dextrose (10ml/kg/h, IV, Deahan hartmandex[®], Deahan Pharm Co., Korea) was administered during the surgical procedure.

II) Radial fracture

The diaphysis of radius was exposed by longitudinal skin incision in the craniomedial aspect of forelimb and careful dissection of muscle and fascia. About 1 mm length of full thickness radius bone was excised with oscillating bone saw just below the pronator teres muscle. Two ends of the fractured bone were fixed in straight by bone plate leaving 1 mm gap between the ends. Muscle, fascia and skin were closed routinely by suturing, and the external surface was supported by Robert John's bandage. The bandage was removed after 4 weeks of immobilization and the dogs were allowed free movement in the cage.

¹Corresponding author.
E-mail : ohkweon@snu.ac.kr

Nandrolone decanoate administration

The dogs of group B were injected with ND (Deca-Durabolin® 50 mg/ml, Hanhwa Co., Korea), 1.5 mg/kg body weight and those of group C, 7.5 mg/kg, intramuscularly immediately after surgery followed by once a week for 8 weeks. The control dogs received 0.1 ml/kg of sterile saline once a week.

Evaluation

I) Body weight

Body weights of two dogs in the control and four dogs in each treated groups were measured using electric balance (AND F-150D®, AND Co., Korea) with accuracy within 10 g, before surgery, 2, 4 and 8 weeks after surgery respectively.

II) Muscle mass

Muscle mass of two dogs in the control and four dogs in each treated groups was measured with tapeline at proximal one fourth of antebrachium before surgery, and 2, 4 and 8 weeks after surgery.

III) Radiographic examination

Lateromedial and craniocaudal radiographs of the antebrachium were made before and immediately after surgery, 2, 4 and 8 weeks after surgery. Radiographic evaluation of bone healing was done with a maximum score of 6⁷. The scoring was based on: 0=no calcification, 1=patchy-calcification, 2=patchy calcification on both fractured ends, 3=calcification takes the appearance of callus, 4=calcification takes the appearance of callus on both fractured ends, 5=callus bridging across the fractured gap, 6=continuity of bone trabeculae. Two radiologists, unaware of the treatment given, read the x-rays of the fractured gap for scoring.

IV) Histological examination

Two dogs in the control and four dogs in each treated groups were euthanized for histological examination at 4th and 8th week respectively. The specimens were fixed in 10% buffered formalin, and decalcified in decalcifying solution (Plank-Rychlo solution) and were taken for routine hematoxylin and eosin (H & E) staining for light microscopic examination.

Statistical analysis

Data were shown as means \pm standard deviations and the significance level was set at $p < 0.05$. For the comparison of increments of body weight and muscle mass among the groups one way ANOVA test was performed followed by multiple pair-wise comparisons using the Turkey and Duncan's tests.

Results

Body weight

Weight gain rates in the groups A, B, and C 8 weeks after surgery were $1.33 \pm 0.14\%$, $11.81 \pm 0.25\%$ and $12.21 \pm 0.44\%$, respectively (Table 1). Significant weight gain was recorded in the groups B and C than that of the group A from 2 weeks

after surgery ($p < 0.05$). There was no difference of weight gain rates between the groups B and C in each week.

Muscle mass

Decreased muscle mass in all dogs until 2 weeks after immobilization of the antebrachium was recorded. The muscle mass of antebrachial girth in the groups A, B and C 8 weeks after surgery changed to $-2.75 \pm 0.16\%$, $1.68 \pm 0.11\%$ and $1.74 \pm 0.48\%$, respectively (Table 2). The enlargement of girth at antebrachium is significantly higher in the treatment groups than that in the control 4 and 8 weeks after ND treatment ($p < 0.05$). However, there were no remarkable differences in muscle mass growth between the groups B and C.

Atrophied muscle mass in the treatment groups was not fully recovered within first 4 weeks but got the initial shape after 8 weeks. A little outgrowth of muscle mass was found in the ND treated group at the 8th week compared with the initial unaffected state. However, the control group failed to get the full recovery of muscle mass even after 8 weeks.

Radiographic findings

The fractured ends begin to lose their sharp margin, as well as callus was formed in each side of the bone at 2nd week after fracture. The callus was continued to grow and began to make a bridge between the fractured gap 4 weeks after surgery. A complete bridge was built by callus at 8th week. There was no significant difference in radiographic score

Table 1. The increment of body weight after the treatment of nandrolone decanoate in dogs

Group	Weeks		
	2	4	8
A	0.62 ± 0.37^{Aa}	0.98 ± 0.15^{Aa}	1.33 ± 0.14^{Aa}
B	3.23 ± 0.37^{Ba}	7.22 ± 0.96^{Bb}	11.81 ± 0.25^{Bc}
C	3.51 ± 0.16^{Ba}	8.69 ± 0.61^{Bb}	12.21 ± 0.44^{Bc}

Data are expressed as mean % of initial body weight \pm SD.

Group A : control, group B : treatment with 1.5 mg/kg ND, group C ; treatment with 7.5 mg/kg ND.

^{a, b, c} = Significant difference ($p < 0.05$) in row.

^{A, B} = Significant difference ($p < 0.05$) in column.

Table 2. The effect of nandrolone decanoate on the disuse muscle mass of the radius in dogs

Group	Weeks		
	2	4	8
A	-3.40 ± 0.43^{Aa}	-3.15 ± 0.34^{Aa}	-2.75 ± 0.16^{Aa}
B	-3.17 ± 0.07^{Aa}	-1.54 ± 0.33^{Bb}	1.68 ± 0.11^{Bc}
C	-3.21 ± 0.39^{Aa}	-1.75 ± 0.30^{Bb}	1.74 ± 0.48^{Bc}

Data are expressed as mean % of initial muscle mass \pm SD.

Group A : control, group B : treatment with 1.5 mg/kg ND, group C : treatment with 7.5 mg/kg ND.

^{a, b, c} = Significant difference ($p < 0.05$) in row.

^{A, B} = Significant difference ($p < 0.05$) in column.

Table 3. Healing of the fractured gap after the treatment of nandrolone decanoate in dogs assessed by radiographic interpretation (scoring)

Group	Weeks		
	2	4	8
A	1.75±0.50	3.25±0.96	5.50±0.71
B	1.38±0.54	3.38±0.82	5.25±0.36
C	1.63±0.54	3.75±0.50	5.50±0.71

Radiographic score was expressed as mean ± SD.

among the groups (Table 3).

Histological examination

The fibrous connective tissue layer was found in the fracture gap of the treatment groups at 4th week (Fig 1). There were no such ingrowths of fibrous connective tissues in the

control group. More dense fibrous connective tissue was found in treated groups B and C at 8th week.

Discussion

Immobilization, disuse, and aging have been documented to produce change in the major functional elements of muscle fiber, such as decrease in muscle mass and strength²¹. Cast or bandage immobilization technique is commonly used in orthopedics and two weeks of immobilization is sufficient to induce muscle atrophy.

In the present study, the changed rates of muscle mass in the ND treated groups were significantly greater than the control 4 weeks after treatment. This result is similar to that of previous report in which ND caused hypertrophy of immobilized and nonimmobilized skeletal muscle in a sedentary rabbit model²⁸. Our result is contrary to the views that

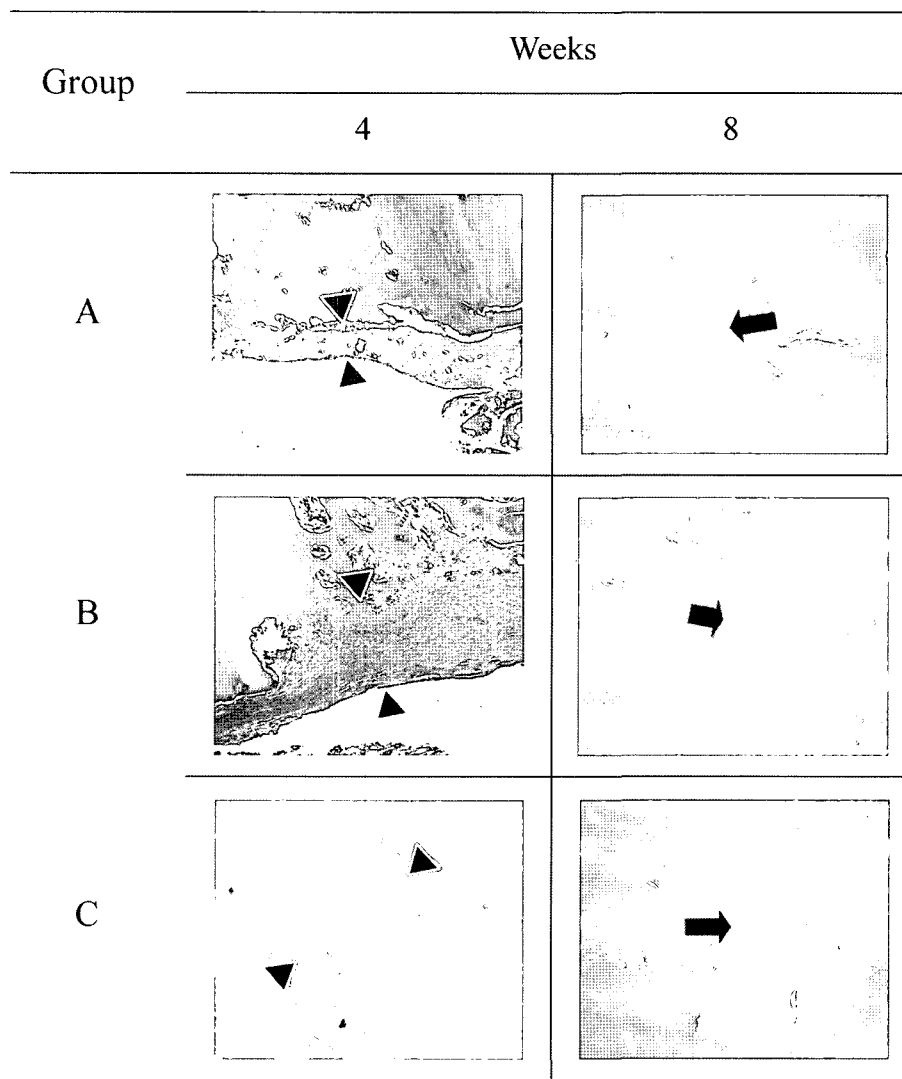


Fig 1. Histological findings revealed the changes in the fibrous connective tissues at the site of the fractured radius in all groups at 4 and 8 weeks after surgery (H&E, 100X). The arrow-heads at 4th week and arrows at 8th week indicate fibrous connective tissue layer. More dense fibrous connective tissue was found at the arrow of 8th week tissue of groups B and C.

the use of anabolic-androgenic steroid lead to muscle hypertrophy only in conjunction with strength training⁶. It is reported that treatment with ND increased the synthesis of muscle or connective tissue protein². Insulin-like growth factor I, growth hormone, testosterone, and estrogen stimulate formation and maintenance of muscle mass in older humans^{3,18}. Anabolic response based on increased sensitivity of the muscle cells to insulin-like growth factor I and fibroblast growth factor. Testosterone and its pharmaceutical derivatives are potent regulators of skeletal muscle mass and have growth effect on the muscle of female, normal male and hypogonadal male^{5,9}.

Significant difference of muscle mass changes were not appeared between the treated groups B and C throughout the study period. Joumaa *et al*²¹ reported that there were no dose-dependent changes in the experimental procedure of ND. However, Bisschop *et al*⁴ reported high-dose treated animal showed stunted growth from 2 weeks. But there were wide dose ranges (1 mg/kg to maximum 25 mg/kg) of ND practiced by other investigators^{1,19}. Minimum dose rate is preferable for the full recovery of muscle mass to the pre-intervention state. In the present study, treatment of disuse muscle atrophy with ND at the dose rate of 1.5 mg/kg body weight was enough to increase the muscle mass to gain the full thickness as before surgery.

In this study, weight gains in the treated dogs were significantly ($P < 0.05$) greater than the control after 2 weeks of treatment. This result is consistent with those of others who have shown that anabolic-androgenic steroid treatment can increase the lean body mass^{2,13}. With this result, significant increments of muscle mass took 2 weeks more than the increments of body weight. These findings are consistent with those of Forbes *et al*¹² who suggested that systemically administered ND does not act selectively on immobilized muscle. The increments of muscle mass in the treated groups were about 2 times greater during free movement period than those during immobilized period. This result is agreeable with previous findings that anabolic androgenic steroids treatment combined with exercise training can increase the rate of muscle protein synthesis and promote muscle development⁸.

ND is a synthetic, anabolic androgenic steroid that has been used for many years in treatment of osteoporosis^{15,20-22}. The effectiveness of ND in treatment of osteoporosis has been established, but the insight mechanism remained unexplored¹¹. In the current study, fibrous connective tissue layer at the fractured gap in the treated groups B and C were thicker than group A at 4 weeks after ND treatment. These findings are similar to that of report described the effect on bone mass in ND treated ovariectomized rat^{23,27}. Androgens are shown to stimulate human and murine osteoblastic cell proliferation in vitro and to induce expression of the osteoblast line differentiation, marker alkaline phosphatase, presumably through an androgen receptor-mediated mechanism^{10,30}. More dense fibrous connective tissue was found in the

treated groups at 8th week in this investigation. The histological findings indicated that large fibrous connective tissue in treated groups at 4th week changed into bone at 8th week. ND has effects on osteoinduction by which undifferentiated mesenchymal cells transform into osteoblast after coming into contact with bone matrix.

Higher physiological level of anabolic steroid has been reported to decrease appetite, convert testosterone to oestradiol, reduce the natural production of testosterone and down-regulate the androgenic-binding receptor²¹. In an animal model, we could not observe any side effects associated with short-term (8-week) anabolic-androgenic steroid treatment. The present study suggested that the treatment of ND was effective for disuse muscle atrophy and bone healing.

Conclusion

Dogs treated with nandrolone decanoate showed significantly increased body weight gain from 2 weeks after treatment ($p < 0.05$) and muscle mass growth from 4 weeks. The fibrous connective tissue layer at the fractured gap was larger in the ND treated groups at 4 weeks after treatment and became more dense at 8 weeks. The present study suggested that the treatment of ND was effective for disuse muscle atrophy and the bone healing.

References

1. Aerssens J, Van Audekercke R, Geusens P, Schot LP, Osman AA, Dequeker J. Mechanical properties, bone mineral content, and bone composition (collagen, osteocalcin, IGF-I) of the rat femur: influence of ovariectomy and nandrolone decanoate (anabolic steroid) treatment. *Calcif Tissue Int* 1993; 53: 269-277.
2. Alen M, Hakkinen K, Komi PV. Changes in neuromuscular performance and muscle fiber characteristics of elite power athletes self-administering androgenic and anabolic steroid. *Acta Physiol Scand* 1984; 122: 535-544.
3. Barret-Connor E, Goodman-Gruen D. Gender differences in insulin-like growth factor and bone mineral density association in old age: the Rancho Bernardo Study. *J Bone Miner Res* 1998; 13: 1343-1349.
4. Bisschop A, Gayan-Ramirez G, Rollier H, Dekhuijzen PN, Dom R, de Bock V, Decramer M. Effects of nandrolone decanoate on respiratory and peripheral muscle in male and female rats. *J Appl Physiol* 1997; 82: 1112-8.
5. Carson JA, Lee WJ, McClung J, Hand GA. Steroid receptor concentration in aged rat hindlimb muscle: effect of anabolic steroid administration. *J Appl Physiol* 2002; 93: 242-250.
6. Celotti F, Negri CP. A review of their effects on the muscles, of their possible mechanisms of action and of their use in athletics. *J Steroid Biochem Mol Biol* 1992; 43: 469-477.
7. Cheung KM, Kaluarachi K, Andrew G, Lu W, Chan D, Cheah KS. An externally fixed femoral fracture model for mice. *J Orthop Res* 2003; 21: 685-690.
8. Elashoff JD, Jacknow AD, Shain SG. Effects of anabolic-androgenic steroids on muscular strength. *Ann Int Med*

- 1991; 115: 387-393.
9. Elbers JMH, Asschenman H, Siedell JC, Gooren LJG. Effects of sex steroid hormones on regional fat depots as assessed by magnetic resonance imaging in transsexuals. *Am J Physiol Endocrinol Metab* 1999; 276: E317-E325.
 10. Erdtsieck RJ, Pols HA, van Kuijk C, Birkenhager-Frenkel DH, Zeelenberg J, Kooy PP, Mulder P, Birkenhager JC. Course of bone mass during and after hormonal replacement therapy with and without addition of nandrolone decanoate. *J Bone Miner Res* 1994; 9: 277-83.
 11. Flicker L, Hopper JL, Larkins RG, Lichtenstein M, Buirski G, Wark JD. Nandrolone decanoate and intranasal calcitonin as therapy in established osteoporosis. *Osteoporosis Int* 1997; 7: 29-35.
 12. Forbes GB, Porta CR, Herr BE. Sequence of changes in body composition induced by testosterone and reversed of changes after drug is stopped. *J Am Med Assoc* 1992; 267: 397-399.
 13. Friedl KE, Dettori JR, Hannan CJ. Comparison of the effects of high dose testosterone and 19-nortestosterone to a replacement dose of testosterone on strength and body composition in normal men. *J Steroid Biochem Mol Biol* 1991; 40: 607-612.
 14. Frisoli A Jr, Chaves PH, Pinheiro MM, Szejnfeld VL. The Effect of Nandrolone Decanoate on Bone Mineral Density, Muscle Mass, and Hemoglobin Levels in Elderly Women With Osteoporosis: A Double-Blind, Randomized, Placebo-Controlled Clinical Trial. *J Gerontol A Biol Sci Med Sci* 2005; 60: 648-653.
 15. Gadeleta SJ, Boskey AL, Paschalis E, Carlson C, Menschik F, Baldini T, Peterson M, Rimnac CM. A physical, chemical, and mechanical study of lumbar vertebrae from normal, ovariectomized, and nandrolone decanoate-treated cynomolgus monkeys. *Bone* 2000; 27: 541-550.
 16. Gebhardt A, Pancherz H. The effect of anabolic steroids on mandibular growth. *Am J Orthod Dentofacial Orthop* 2003; 123: 435-40.
 17. Guesens, P, Dequeker J. Long-term effect of nandrolone decanoate, 1α -hydroxyvitamin D_3 or intermittent calcium infusion therapy on bone mineral content, bone remodeling and fracture rate in symptomatic osteoporosis : A double-blind controlled study. *Bone Miner* 1986; 1: 347-357.
 18. Hedstron M. Hip fracture subjects, a group of frail elderly people with low bone mineral density, muscle mass and IGF-1 levels. Review. *Acta Physiol Scand* 1999; 167: 347-350.
 19. Huang RY, Miller LM, Carlon CS, Chance MR. Characterization of bone mineral Composition in the proximal tibia of cynomolgus monkeys: Effect of ovariectomy and nandrolone decanoate treatment. *Bone* 2002; 30: 492-497.
 20. Jerome CP, Power RA, Obasanjo IO, Register TC, Guidry M, Carlson CS, Weaver DS. The androgenic anabolic steroid nandrolone decanoate prevents osteopenia and inhibits bone turnover in ovariectomized cynomolgus monkeys. *Bone* 1997; 20: 355-364.
 21. Joumaa WH, Bouhlel A, Bigard X, Leoty C. Nandrolone decanoate pre-treatment attenuates unweighting-induced functional changes in rat soleus muscle. *Acta Physiol Scand* 2002; 176: 301-309.
 22. Lane NE, Kelman A. A review of anabolic therapies for osteoporosis. *Arthritis Res Ther* 2003; 5: 214-222.
 23. Li X, Takahashi M, Kushida K, Shimizu S, Hoshino H, Suzuki M, Inoue T. The effects of nandrolone decanoate on bone mass and metabolism in ovariectomized rats with osteopenia. *J Bone Miner Metab* 2000; 18: 258-263.
 24. Lyons GE, Kelly AM, Rubinstein NA. Testosterone-induced changes in contractile protein isoforms in the sexually dimorphic temporalis muscle of the guinea pig. *J Biol Chem* 1986; 26: 13278-13284.
 25. McClung JM, Mehl KA, Thompson RW, Lowe LL, Carson JA. Nandrolone decanoate modulates cell cycle regulation in functionally overloaded rat soleus muscle. *Am J Physiol Regul Integr Comp Physiol* 2005; 288: R1543-1552.
 26. McDonald KS, Fitts RH. Effect of hindlimb unloading on rat soleus fiber force, stiffness, and calcium sensitivity. *J Appl Physiol* 1995; 79: 1796-1802.
 27. Schot LPC, Schuurs AHWM, Kloosterboer HJ. The action of anabolic steroids on bone in experimental animals. *Wien Med Wochenschr* 1993; 143: 385-387.
 28. Taylor DC, Brooks DE, Ryan JB. Anabolic-androgenic steroid administration causes hypertrophy of immobilized and nonimmobilized skeletal muscle in a sedentary rabbit model. *Am J Sports Med* 1999; 27: 718-727.
 29. Tsika RW, Herrick RE, Baldwin KM. Effect of anabolic steroids on skeletal muscle mass during hindlimb suspension. *J Appl Physiol* 1987; 63: 2122-2127.
 30. Vanderschueren D, Van Herck E, Suiker AMH, Visser WJ, Schot LPC, Chung K, Lucas RS, Einhorn TA, Bouillon R. Bone and mineral metabolism in the androgen-resistant (Testicular feminized) male rat. *J Bone Miner Res* 1993; 8: 801-809.

개에서 불용성 근위축과 골절 치유에 대한 Nandrolone decanoate의 효과

윤성진 · 임지혜 · 미자누르 라흐만 · 변예은 · 김완희 · 권오경¹

서울대학교 수의과대학

요약 : 개에서 Nandrolone decanoate(ND)의 수술 후 외고정 등에 의한 불용성 근위축과 골절 치유에 미치는 영향을 평가하기 위하여 본 실험을 실시하였다. 3.3~5.5 kg, 2~4세의 건강한 잡종견 20두를 대조군(A군, 4두), 1.5 mg/kg ND 투여군(수술 직후 투여 - B군, 8두), 7.5 mg/kg ND 투여군(수술 직후 투여 - C군, 8두)으로 나누어 무작위로 실험에 사용하였다. 요골의 골간에 골절을 유발하여 1 mm 간격을 유지하며 plate로 고정하였다. ND (Deca-Durabolin® 50 mg/ml, 한화제약 주식회사) 투여 군은 1.5 mg/kg 혹은 7.5 mg/kg 용량의 ND를 수술 직후, 일주일에 일회씩 근육 내로 8주간 투여하였다. 수술 후 4주간 로버트 존스 포대법을 실시한 후 제거하였다. 체중과 근육의 변화를 수술 직후, 수술 2, 4, 8주 후에 각각 측정하였다. ND 투여 후 4주와 8주에 조직학적 검사를 실시하였다. 근육량의 변화는 A, B 및 C 각 군에서 수술 8주 후에 수술 전 근육량의 $-2.75 \pm 0.16\%$, $1.68 \pm 0.11\%$ 및 $1.74 \pm 0.48\%$ 의 변화를 보였다. 근육량은 대조군과 비교하여 투여군에서 투여 4주 후부터 유의적으로 증가하였다 ($p < 0.05$). 투여군에서 용량 의존적 차이는 보이지 않았다. 조직학적 평가에서 ND 투여 4주 후 투여군에서 골절된 골 사이에 형성된 섬유 결합조직층이 대조군과 비교하여 더 많이 형성되었다. 8주 후 투여군에서 섬유결합 조직층이 더욱 치밀해졌다. 이상의 결과로 보아 ND 투여는 수술 후 외고정 등에 의한 불용성 근위축의 예방과 골절 치유에 유용할 것으로 사료된다.

주요어: 개, Nandrolone decanoate, 불용성 근위축, 골절 치유