

## The Efficacy of Surgical Treatment with Flexible Alligator Forceps in Dogs with Heartworm Infection

Hun-young Yoon, Soon-wuk Jeong<sup>1</sup>, Jun-young Kim, Hyun-jung Han, Ha-young Jang, Bora Lee and Hyo-sun Namkung

Department of Veterinary Surgery, College of Veterinary Medicine, Konkuk University, Seoul 143-701, Korea

**Abstract :** This study was performed to assess the efficacy of surgical treatment with flexible alligator forceps (FAF) on heartworm infected dogs. Twenty dogs (10 males and 10 females) with heartworm infection, age  $5.3 \pm 3.0$  (mean  $\pm$  S.D.) years and weight  $9.3 \pm 6.5$  (mean  $\pm$  S.D.) kg were treated with FAF. Adult heartworms were removed by fluoro-guided technique with FAF under inhalation anesthesia with isoflurane. For evaluation of the efficacy, removal rate and surgical time were measured, and removal sites were found. Antigen ELISA kit test and autopsy were performed to examine remained adult heartworms. Removal rate of total heartworms was 91.4% including 15 complete retrieval cases and surgical time was  $30.0 \pm 7.6$  (mean  $\pm$  S.E.) minutes. Heartworms were removed from the right ventricle, main pulmonary artery, and right and left pulmonary artery. Surgical treatment with FAF is an effective method with high removal rate, short surgical time, and various removal sites and it could be considered for the removal of adult heartworms in a dog.

**Key words :** heartworms, flexible alligator forceps, surgical treatment, dogs.

### Introduction

Dirofilariasis is a disease caused by *Dirofilaria immitis* through various species of mosquitoes throughout the world except cold climate areas<sup>2,13</sup>. Heartworm disease is a common problem in dogs, cats, and other domestic animals in endemic area<sup>19</sup>. In America and Brazil which have similar climate of South Korea, 52% and 31.25% of infection rate were shown<sup>8,18</sup> and in suburbs of Seoul in South Korea, 50.3% of dogs having no prevention of heartworm was already infected<sup>19</sup>. Even in human, it could be a serious problem, and recently infection cases have been reported in United State of America, Japan, Europe, and South Korea<sup>9,14,15</sup>. It is the most common cause of pulmonary hypertension resulting in death in dogs.

The present study was conducted to prove the efficacy of surgical treatment with flexible alligator forceps (FAF) that has never been tried in spite of the requirements of proper treatment to dogs with heartworm infection in South Korea by evaluation of removal rate, surgical time, and removal sites.

### Materials and Methods

#### Experimental dogs

Twenty dogs with heartworm infection for surgical treatment with FAF [Fujinon Type L (FK-480L<sup>®</sup>), Fujinon Type S (FK-380S<sup>®</sup>, Japan)], age  $5.3 \pm 3.0$  years (2-14) (mean  $\pm$  S.D.) and weight  $9.3 \pm 6.5$  kg (2.1-25) were used in this study. There were 10 males and 10 females.

#### Clinical examinations

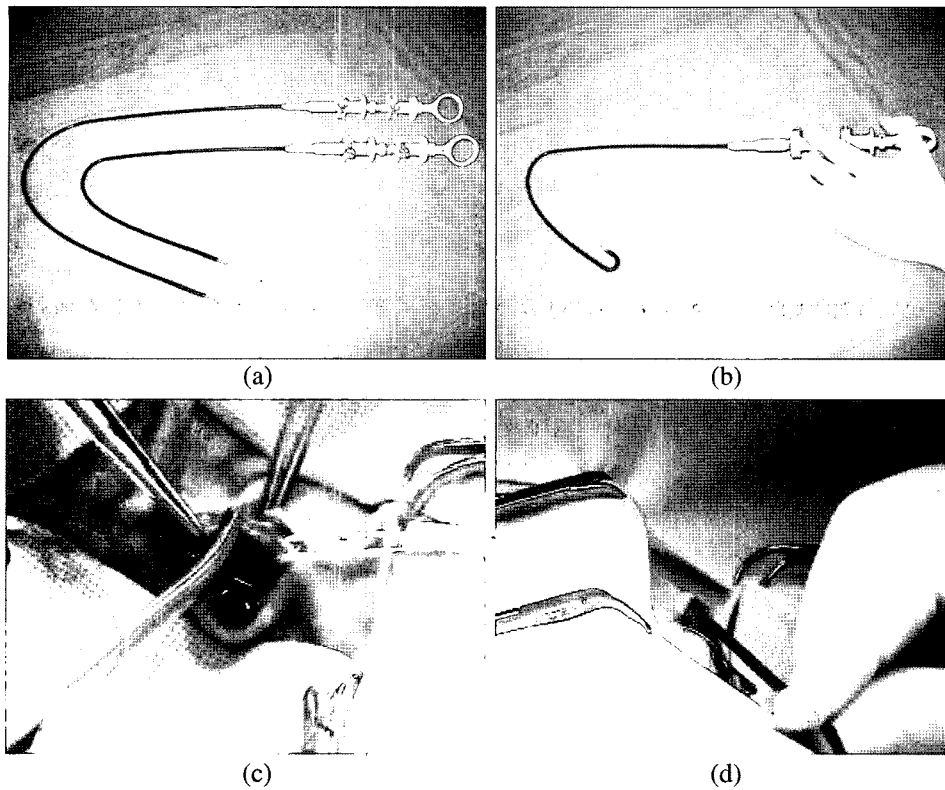
Heartworms infection was confirmed by microscopic test, antigen ELISA test (SNAP<sup>®</sup>, IDEXX Laboratories, Inc, USA), and ultrasonography.

#### Surgical method

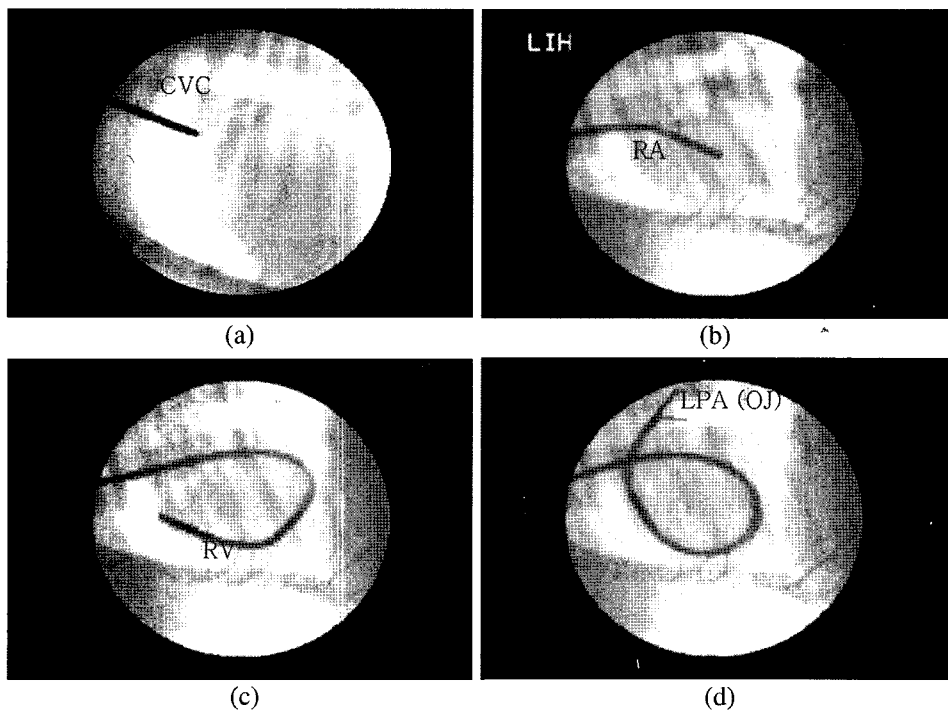
**Pretreatment and anesthesia.** Furosemide (Lasix<sup>®</sup>, Handok Pharm. Co., Ltd, Korea, 2 mg/kg, tid, IV), enalapril (Emalein<sup>®</sup>, Poong Lim Pharm. Co., Ltd, Korea, 0.3 mg/kg, bid, PO), aspirin (Aspirin<sup>®</sup>, Shin Poong Pharm. Co., Ltd, Korea, 5 mg/kg, sid, PO), and silymarin (Silymarin<sup>®</sup>, Shinil Pharm. Co., Ltd, Korea, 3 mg/kg, bid, PO) were medicated for 7 days. Before surgery, cefradine (Cefradine inj<sup>®</sup>, Korea Schnell Pharma. Co., Ltd, Korea, 30 mg/kg, IV), atropine sulfate (Atropine sulfate<sup>®</sup>, Je Il Pharm. Co., Ltd, Korea, 0.02 mg/kg, SC), and butorphanol (Butorphan<sup>®</sup>, Myung Moon Pharma. Co., Ltd, 0.4 mg/kg, IV) were injected. Intubation was performed after thiopental sodium (Pentotal sodium 0.5gr.inj<sup>®</sup>, Choong Wae Pharm. Corp., Korea, 8 mg/kg, IV) induction. Isoflurane (Rhodia Orgranique Fine Ltd., Korea, 0.5%~2.5%) was used for maintenance with 100% oxygen (1-2 L/min). Operation was performed by fluoro-guided technique.

**Surgical technique.** Skin on the jugular vein at the center of neck was incised about 3-4 cm. After blunt dissection of subcutaneous tissue, tissue around jugular vein was dissected to expose jugular vein with right angle forceps. Exposed jugular vein was smoothly tightened with rummel tourniquet (or bulldog clamp) made of umbilical tape to distend jugular vein. Distended jugular vein was vertically incised about 3-4 mm and FAF was inserted (Fig 1). Under fluoroscopy, FAF was introduced to cranial vena cava, right atrium, right ventricle, main pulmonary artery, right pulmonary artery, and left pulmonary artery manipulating first nobs (Fig 2). When the jaw of FAF was positioned in wanted places, it was opened

<sup>1</sup>Corresponding author.  
E-mail : swjeong@konkuk.ac.kr



**Fig 1.** Equipments for removing heartworms and guiding of flexible alligator forceps; flexible alligator forceps (Fujinon Type L (FK-480L): Type S (FK-380S), bottom) (a), bent the front part of flexible alligator forceps with manipulating first nobs (b), jugular venotomy by scissors with rummel tourniquet (c), flexible alligator forceps was guided into incision part on jugular vein (d).



**Fig 2.** Guiding of flexible alligator forceps through the cranial vena cava (a), the right atrium (b), and the right ventricle (c) and grasping of flexible alligator forceps in pulmonary artery (d) in fluoroscopical view. CVC: Cranial Vena Cava; RA: Right Atrium; RV: Right Ventricle; LPA (OJ): Left Pulmonary Artery (Opened Jaw).

and closed by second nobs (Fig 2) and then it was guided out. These procedures were repeated until adult heartworms were sufficiently removed. Incision part on jugular vein was vertically sutured with polypropylene 6-0. Subcutaneous tissues were sutured by simple continuous suture method with polyglycolic acid (safil®) and skin was sutured by transverse mattress suture method with polyamide (dafilon®).

#### Postoperative Management and Evaluation

Furosemide, enalapril, aspirin, and silymarin were medicated for 2 weeks. Aspirin was administered at two times higher doses to prevent thromboembolism made during operating time. Cefradine (Cefradine inj®, Korea Schnell Pharma. Co., Ltd, Korea, 30 mg/kg, IV) was prophylactically injected for 2 weeks. Numbers of removed heartworm were counted according to removal site and whether completely removed or not was confirmed by autopsy and antigen ELISA kit test. Surgical time was calculated from operating start to suturing of incision line.

#### Statistics

Significance among removal sites was calculated by ANOVA-test.

#### Results

The removal rate was confirmed on day 7 after heartworm removal using antigen ELISA kit test and autopsy. Heartworms were perfectly removed in fifteen out of 20 heartworm infected dogs. Removal rate of heartworms was ranged from 50 to 100% (mean removal rate: 91.4%) (Table 1). The number (mean±S.E.) of removed heartworms was 10±1.8. The total number (mean±S.E.) of removed heartworms including autopsy result was 10±1.7. The number (mean±S.E.) of trial was 10.75±0.5. It took from 20 to 50 minutes (mean±S.E.: 30.0±7.6 minutes) for surgery (Table 1). Removal sites were confirmed with fluoroscopy. From right pulmonary artery, main pulmonary artery, left pulmonary artery, and right ventricle, 47, 29.5, 23, and 0.5% were removed, respectively (Table 1). There was a significant correlation among right

**Table 1.** Numbers of removed heartworms, surgical time, and removal sites by flexible alligator forceps in Dogs with Heartworm Infection.

Case No.	Numbers of removed heartworms	Autopsy result	Total number	Removal rate*	Surgical time	The number of trial	Removal Sites			
							RV <sup>a</sup>	MPA <sup>b</sup>	RPA <sup>c</sup>	LPA <sup>d</sup>
1	2	2	4	50%	50 min	8	0	1	0	1
2	2	1	3	67%	45 min	9	0	2	0	0
3	1	0	1	100%	20 min	6	1	0	0	0
4	2	2	4	50%	35 min	9	0	2	0	0
5	5	0	5	100%	30 min	10	0	3	0	2
6	6	0	6	100%	28 min	11	0	1	3	2
7	5	0	5	100%	20 min	13	0	1	2	2
8	8	0	8	100%	22 min	14	0	3	3	2
9	7	2	9	77%	30 min	13	0	1	5	1
10	16	3	19	84%	35 min	12	0	10	4	2
11	17	0	17	100%	30 min	15	0	6	8	3
12	8	0	8	100%	25 min	10	0	2	4	2
13	20	0	20	100%	35 min	13	0	0	12	8
14	7	0	7	100%	25 min	9	0	0	5	2
15	16	0	16	100%	25 min	11	0	3	8	5
16	7	0	7	100%	25 min	10	0	2	4	1
17	11	0	11	100%	33 min	10	0	3	6	2
18	18	0	18	100%	29 min	12	0	5	10	3
19	33	0	33	100%	30 min	11	0	11	16	6
20	9	0	9	100%	27 min	9	0	3	4	2
Mean±S.E.	10±1.8	0.5	10±1.7	91.4%	30.0±7.6	10.75±0.5	0.5% <sup>e</sup>	29.5% <sup>e</sup>	47% <sup>e</sup>	23% <sup>e</sup>

\*. Confirming on day 7 after heartworm removal through antigen ELISA kit test and autopsy

<sup>a</sup>RV: Right Ventricle, <sup>b</sup>MPA: Main Pulmonary Artery, <sup>c</sup>RPA: Right Pulmonary Artery, <sup>d</sup>LPA: Left Pulmonary Artery,

<sup>e</sup>Significance among removal sites was calculated by ANOVA-test, F=+4.40 (P<0.01).

pulmonary artery, main pulmonary artery, left pulmonary artery, and right ventricle (correlation coefficient=+4.40,  $P<0.01$ , Table 1).

## Discussion

The efficacy of surgical treatment with FAF in dogs with heartworm infection was evaluated. In this disease, surgical methods such as thoracotomy and jugular venotomy with rigid alligator forceps<sup>1,7</sup> and medical methods such as arsenamide, diethylcarbamazine, dichlorophenarsine, thiacetarsamide, and melarsomine dihydrochloride have been used<sup>11,16,17</sup>. Medical treatment especially melarsomine dihydrochloride has been mainly used and the outcome of medication has been good. However, in patients showing resistance to medication or possibility of shock induced by dead heartworms playing a role as thromboembolism, surgical removal by thoracotomy and jugular venotomy with rigid alligator forceps has been applied<sup>12</sup>. However, the application of these methods has been also limited because they are invasive and limited in approaching sites to remove heartworm.

In the present study, adult heartworms were successfully removed by surgical treatment with FAF without damage to cardiovascular system. The rate of heartworms removal was 91.4%, which was very important in terms of the fact that adult heartworms which induced pneumonia coming from thromboembolism were removed out of a body. There were not abnormal changes in heart during surgery and after surgery. This surgical rate was similar to the other studies showing 89.3%<sup>3</sup>, 89.9%<sup>4</sup>, 90.4%<sup>5</sup>, 92.2%<sup>10</sup>, and 93.6%<sup>6</sup>. Shortening operation time is important in surgical treatment because long anesthesia is related to life. In present study, jugular venotomy was executed in brief and FAF was easily guided in heart. In addition, manipulation of FAF also was simple. Those procedures made operation time shortened, which helped to decrease rate of death caused by long time anesthesia. Jugular vein was approached for operation and this was less invasive than thoracotomy that could damage to major organs in cardiovascular system. Advantage of this approaching method was introduced in previous studies. According to previous report, during the manipulation of FAF jaws should not be opened for grasping in the right ventricle lest the jaw should hook the tricuspid chordae<sup>6</sup>. However, it was possible in the present study under complete understanding of anatomy of heart and finding heartworm in right ventricle by ultrasonography. Therefore, adult heartworms were removed not only from the main pulmonary artery, left pulmonary artery, and right pulmonary artery but also right ventricle because flexible front part of forceps was manipulated by first nob easily.

## Conclusion

The present study indicated that surgical treatment with FAF was very effective method to treat dogs with heart-

worms infection in terms of high removal rate, shortening operation time, and the possibility of removing from wanted places where heartworm dwells. Therefore, surgical treatment with FAF is considered to be safe and effective and may be alternative to other methods for treatment of heartworm infection.

## Acknowledgements

This work was supported by Konkuk University in 2004.

## References

1. Abadie SH, Black E, Dupuy HJ, Gonzalez R. A procedure for the surgical removal of *dirofilaria immitis*. J Am Vet Med Assoc 1970; 156: 884-889.
2. Grantz NG. Critical review of the vector status of *Aedes albopictus*. Med Vet Entomol 2004; 18: 215-227.
3. Ishihara K, Kitagawa H, Sasaki Y. Efficacy of heartworm removal in dogs with dirofilariasis using flexible alligator forceps. Jpn J Vet Sci 1988; 50: 739-745.
4. Ishihara K, Sasaki Y, Kitagawa H, Hayama M. Clinical effects after heartworm removal from pulmonary arteries using flexible alligator forceps in dogs with common dirofilariasis. Nippon Juigaku Zasshi 1988; 50: 723-730.
5. Ishihara K, Kitagawa H, Sasaki Y, Yokoi H. Changes in cardiopulmonary values after heartworm removal from pulmonary artery using flexible alligator forceps. Nippon Juigaku Zasshi 1988; 50: 731-738.
6. Ishihara K, Sasaki Y, Kitagawa H. Development of a flexible alligator: a new instrument for removal of heartworms in the pulmonary arteries of dogs. Jpn J Vet Sci 1986; 48: 989-991.
7. Jackson RF, Seymour WG, Growney PJ, Otto GF. Surgical treatment of the caval syndrome of canine heartworm disease. J Am Vet Med Assoc 1977; 171: 1065-1069.
8. Kaiser L, Williams JF. *Dirofilaria immitis*: worm burden and pulmonary artery proliferation in dogs from Michigan (United States). Vet Parasitol 2004; 124: 125-129.
9. Kim MK, Kim CH, Yong TS. The first human case of hepatic dirofilariasis. J Korean Med Sci 2002; 17: 686-690.
10. Kitagawa H, Sasaki Y, Ishihara K, Hirano Y. Contribution of live heartworms harboring in pulmonary arteries to pulmonary hypertension in dogs with dirofilariasis. Nippon Juigaku Zasshi 1990; 52: 1211-1217.
11. Kume S, Ohishi I. Observations on the chemotherapy of canine heartworm infection with arsenicals. J Am Vet Med Assoc 1957; 131: 476-480.
12. Kuntz CA, Smith-Carr S, Huber M, Weigand C, Hanks GH. Use of a modified surgical approach to the right atrium for retrieval of heartworms in a dog. J Am Vet Med Assoc 1996; 208: 692-694.
13. Mahmood F. Susceptibility of geographically district *Aedes aegypti* L. from Florida to *Dirofilaria immitis* (Leidy) infection. J Vector Ecol 2000; 25: 36-47.
14. Mumtaz H, Ozdemir A, Schaefer RC. Case of the month. A case report of human pulmonary dirofilariasis in Arkansas. J Ark Med Soc 2004; 100: 240-242.
15. Narnine K, Brennan B, Gilfillan I, Hodge A. Pulmonary

- presentation of *dirofilaria immitis* (canine heartworm) in man. *European Journal of Cardio-thoracic Surgery* 1996; 16: 475-477.
16. Paillet A, Abadie SH, Smith MW, Gonzalez RR. chemotherapeutic heartworm control-the use of diethylcarbamazine in the control of *dirofilaria immitis* infection in dogs in clinical trials. *Vet Med Small Anim Clin* 1968; 63: 691-693.
17. Rawlings CA, Raynaud JP, Lewis RE, Duncan JR. Pulmonary thromboembolism and hypertension after thiace-tarsamide vs melarsomine dihydrochloride treatment of *dirofilaria immitis* infection in dogs. *Am Vet Res* 1993; 54: 920-925.
18. Reifur L, Thomaz-Soccol V, Montiani-Ferreira F. Epidemiological aspects of filariasis in dogs on the coast of Parana state, Brazil: with emphasis on *Dirofilaria immitis*. *Vet Parasitol* 2004; 122: 273-286.
19. Yoon HY, Yoon CS, Jeong SW, Kim TJ, Park SY, Chung BH, Choi YM, Lee WC. Prevalence and relative risk of canine dirofilariosis among dogs in seoul, South Korea. *Vet Rec* 2002; 151: 576-577.

## 심장사상충 감염견에서 Flexible Alligator Forceps을 이용한 외과적 치료

윤현영 · 정순욱<sup>1</sup> · 김준영 · 한현정 · 장하영 · 이보라 · 남궁효선

건국대학교 수의과대학 외과학교실

**요약:** 본 연구는 심장사상충 감염견에 있어서 flexible alligator forceps (FAF)을 이용한 외과적 치료법의 효능을 평가하기 위해 실시 되었다. FAF를 이용한 외과적 치료를 위해 평균 연령 5.3±3.0 (mean±S.D.) 년, 평균 체중 9.3±6.5 (mean±S.D.)kg인 20마리의 심장사상충 감염견을 실험에 사용하였다. 그 중 수컷 10마리, 암컷 10마리였다. 성충 제거를 위한 외과적 치료를 isoflurane 호흡 마취 하에 FAF와 투시기를 이용하여 실시 하였다. FAF를 이용한 외과적 치료 방법의 평가를 위해 제거율과 수술시간을 측정 하였고 제거 부위를 확인하였다. 제거 되지 않고 남아 있을 수 있는 성충 확인을 위해 항원 ELISA kit 검사와 부검을 실시하였다. 제거율은 심장사상충이 완전히 제거된 15마리를 포함 전체 심장사상충의 91.4% 였고 수술에 걸린 평균 시간은 30.0±7.6 (mean±S.E.)분 이었다. 또한 심장사상충은 우심실, 주폐동맥, 우폐동맥, 그리고 좌폐동맥에서 제거 되었다. 결론적으로, FAF를 이용한 외과적 치료법은 높은 제거율, 짧은 수술 시간, 그리고 다양한 제거부위와 같은 장점을 보이는 효과적이 방법이며 심장사상충 감염견에서 적용될 수 있는 좋은 치료법으로 사료된다.

**주요어:** 심장사상충, flexible alligator forceps, 외과적 치료, 개