

Effect of Alginate on Early Bone Healing after Implantation of Particulate Dentin and Plaster of Paris Mixture

Gyung-Ahn Cho*, Su-Gwan Kim*#, Sung-Chul Lim**, Sang-Gon Kim***#

Oral Biology Research Institute#, College of Dentistry, Chosun University, Gwangju, Korea*

Department of Pathology, Medical Research Institute, College of Medicine, Chosun University**

College of Dentistry, Dept. of Human Biology***

Abstract

치아 회분말과 연석고를 이용한 초기 골치유시 알긴산의 효과

조경안* · 김수관* · 임성철** · 김생곤***

조선대학교 치과대학 구강악안면외과학교실*, 조선대학교 의과대학 병리학교실**

조선대학교 치과대학 인체생물학교실***

본 연구의 목적은 치아 회분말과 연석고 및 알긴산을 혼합하여 이식한 후 초기 골 형성을 알아보는 데 있다. 백서 30 마리의 두개골에 8mm 직경의 골결손부를 형성한 후 인간의 치아 회분말과 연석고 및 알긴산을 혼합하여 이식한 후 대조군, 치아 회분말과 연석고 처치군, 그리고 치아 회분말과 연석고 및 알긴산 혼합 처치군에서 각각의 골 결손부 치유과정을 조직병리학적, 조직형태측학적으로 비교 관찰하였다.

통계학적으로 주간 변화(4주, 8주)는 유의하지 않았고, 각 그룹 간에 있어도 치아 회분말과 연석고 처치군과 치아 회분말과 연석고 및 알긴산 혼합 처치군 간 모두(4주, 8주) 유의한 차이가 없었다. 그러나 이들 치아 회분말과 연석고 처치군과 치아 회분말과 연석고 및 알긴산 혼합 처치군은 대조군에 비해서는 유의하게 우수한 신생골 형성을 보였다. 비록 통계학적으로는 치아 회분말과 연석고 처치군과 치아 회분말과 연석고 및 알긴산 혼합 처치군이 유의한 차이를 보이지 않았지만 치아 회분말과 연석고 및 알긴산 혼합 처치군에서 보다 더 우수한 신생골 형성 경향을 보였다. 뿐만 아니라, 신생골의 내용면에서도 치아 회분말과 연석고 및 알긴산 혼합 처치군에서 좀더 많은 신생 직조골의 융합이나 골 소주형성이 관찰되어 신생골의 형성 및 성숙에 알긴산이 역할을 담당하는 것으로 사료되었다.

결론적으로 골결손부 치료 방법으로 치아 회분말과 연석고 처치군 또는 치아 회분말과 연석고 및 알긴산 혼합 처치로 결손부에 이식하는 것은 신생골 형성의 양적, 질적 개선에 통계학적으로 유의하며, 알긴산을 이식재와 함께 처리한 경우에 신생골 형성의 양적, 질적 개선에 도움을 줄 수 있을 것으로 사료된다.

I. Introduction

A variety of bone grafts and other biomaterials are needed in clinical dentistry for the esthetic and functional repair of defects in the jaw¹⁾. There are four forms of bone grafting material: autogenous bone²⁾, allografts, xenografts, and alloplasts. Although autogenous bone is the most effective

for grafting^{3,4)}, bone substitutes, which is a mixture of particulate dentin and plaster of Paris⁵⁻⁷⁾, has become widely used in recent years in place of autogenous bone with the activation of bone banks and the development of tissue preservation techniques. However, the use of particulate dentin and plaster of Paris mixtures is limited owing to associated graft rejection and inflammation during

* This study was supported by research funds from Chosun University, 2004.

bone healing, which result in optimal amount of bone regeneration⁷. Many studies have sought to overcome these limitations⁸⁻¹⁰.

An ideal bone substitute should be biocompatible and gradually replaced by newly formed bone. It should also possess osteoinductive and osteoconductive properties¹¹.

Research on grafting materials began with the development of hydroxyapatite (HA) materials^{3,12,13}. However, it is difficult to maintain stable fusion between powdered HA and the surrounding bone because of the fluid nature of the powder. Although many different solutions to this fluidity problem have been tested, including the use of additives such as dental porcelain¹⁴, dental cement¹⁵, and plaster of Paris^{13,16,17}, the results remain unsatisfactory. A further study examined ways of improving the stability of HA by incorporating plaster of Paris³.

Particulate dentin (tooth ash) is derived from sound teeth and is composed mainly of hydroxyapatite. It has been used as an alternative for implants and is bioresorbable. However, the use of particulate dentin can cause a problem with graft material retention^{1,18}. Mixtures of particulate dentin and plaster of Paris have been studied as new biomaterials, and the biocompatibility and possible use of these mixtures in bony defect reconstruction has been explored¹.

Plaster of Paris is made of calcium sulfate hemihydrate and seems promising because of its long history of safe use and characteristic complete resorption followed by bone formation¹⁹. Plaster of Paris is easy to use and disinfect during surgery. It is also reasonably priced and can even hinder the fluidity of the implant. Its average solidity enables it to resist rupture after consolidation. Although plaster of Paris cannot guide and induce new bone formation, its resorptive characteristics and biocompatibility can help it to act as a bonding agent when mixed with other materials. In addition, the resorption rate becomes faster and invasion around the tissue is facilitated as the material's density decreases³.

Alginate, which is derived from brown algae that grow in waters cooler than 20°C, has a

polyuronic structure consisting of a combination of mannuronic acid and guluronic acid. Brown algae contain 14-40% alginate. The industrial and biological value of alginate is increasing, and studies on the extraction of alginate from kelp and its use as food are underway. The incidence of adult diseases such as hypertension, diabetes, and circulatory disease is on the rise among Koreans, as a result of their improved diet. Alginate is also a source of dietary fiber and can reduce cholesterol levels. Alginate is absorbed in the body and is a biocompatible, non-toxic substance^{20,21}. It is used as a dressing for soft tissue wounds and aids clot formation and hemostasis. Studies have also examined the use of alginate as an absorbable membrane during guided bone regeneration (GBR)²². Alginate promotes osteoblast differentiation by inducing transforming growth factor- β (TGF- β)^{23,24}. In dentistry, alginate is used to make impressions, but other applications in dentistry, such as the use of alginate in bone formation, have not been examined, and the effect of alginate on bone formation has not been determined.

The process of bone healing accompanies inflammation after bone grafting. The resulting production of free radicals hinders bone formation. As there is no effective way to prevent free radical production, ways of reducing the toxicity of free radicals are being developed. Many attempts have been made to remove and prevent the production of free radicals using anti-oxidants². This has been proven effective in patients with degenerative arthritis²⁵, but has never been tested in dentistry. Effective bone healing might be achieved by using an antioxidant to control the cytotoxicity caused by free radicals produced during the inflammatory reaction at the time of bone grafting.

The purpose of this study was to examine the early bonehealing pattern of grafted bone and the degree of new bone formation to determine the effects of the antioxidant alginate after grafting with a particulate dentin and plaster of Paris mixture.

II. Materials and Methods

Subjects

This study was approved by the Animal Research Committee of Chosun University. Sixty healthy Sprague-Dawley rats, each weighing 200 to 300 g, were used. The study animals were divided into three groups of 30 rats each: the control group, experimental group I (particulate dentin and plaster of Paris mixture), and experimental group II (particulate dentin and plaster of Paris mixture soaked in alginate). The rats were reared under the same conditions and fed the same commercial solid feed.

Graft

A mixture of particulate dentin and plaster of Paris was used as the graft material in bone defects.

Preparation of particulate dentin

Particulate dentin was produced in the following manner. First, foreign matter and soft tissue attached to the tooth surface were removed by soaking relatively sound teeth in hydrogen peroxide. Next, the teeth were heated to 1200°C in a furnace for 2 hours and then ground as completely as possible using a mortar and pestle. The ground teeth were filtered using a mesh tray (Sieve No. 100), and the filtered powder was ground minutely two or three times. The final mean particle size of the particulate dentin was 0.149 mm. The particulate dentin was placed in a beaker of distilled water and autoclaved. Then, any floating material was carefully removed using a pipette, and the residue and distilled water in the beaker were shaken. The solution was stored for one day and then sterilized. This autoclaving process was repeated five times to remove all foreign materials. After the final sterilization, the distilled water and residue were removed and dried in an oven. The resulting powder was used as implant material. The material was kept in ethylene oxide after disinfection.

Particulate dentin-plaster of Paris mixture

Particulate dentin and plaster of Paris were mixed in a ratio of 2:1 by weight with saline and placed in the defect. After it dried, the material was sculpted with a bur to match the contour of the remaining bone.

Alginate

H₂SO₄ and HIO₄ were placed in 1% alginate oligosaccharide (in 10 mM Tris-HCl buffer) and reacted for 20 min at 50°C. The reaction was stopped 20 min after reaching the titration state, and the resulting liquid was used for further study. The particulate dentin and plaster of Paris mixture was soaked in the alginate.

Surgery

The rats were anesthetized with intramuscular injections of ketamine HCl (Ketalar, Yuhan, 10 mg/kg) and xylazine (Rompun, Bayer, 3 mg/kg). After shaving and sterilizing the head, 2% lidocaine solution was used for local anesthesia. A 2-cm central incision was made from the frontal portion to the occipital portion, exposing the subcutaneous tissues. The tissue and periosteum were reflected and secured at the sides to expose the skull. While being careful not to damage the blood vessels crossing the middle of the dura mater, a full-thickness cranial defect 8 mm in diameter was created using a dental drill at low speed. Physiologic saline was used to irrigate the defect to prevent excessive heat. After adequate hemostasis, the mixture of particulate dentin and plaster of Paris with or without soaking in alginate was used to fill the defect to the height of the surrounding bone, and the wound was closed and sutured. In the control group, no material was added to the defect. In order to prevent infection after surgery, an intramuscular injection of gentamicin (Daesung Microbiological Labs. Co., 5 mg/kg) was given daily for 5 days.

Sample preparation

Rats from each group were sacrificed at 4 and 8 weeks after surgery by using cervical dislocation after the administration of the same anesthesia used for surgery. The bone defect, the periosteum on top of the defect, and a piece of healthy bone near the skin were dissected en bloc. This block was fixed in 10% neutral formalin and demineralized by soaking in nitric acid (De-Cal Rapid, Patialal Diagnosis, Atlanta, GA, USA) for 4 hours. It was then cut vertically across the longest diameter to obtain three serial sections, each 3 mm thick. Each section was washed, treated histologically using an autoprocesing machine (Hypercenter XP, Shandon, UK), and embedded in paraffin. The paraffin sections were cut into 4- to 5- μm -thick slices. Each slice was placed on a glass slide, left on a plate heated at 68°C for 1 hour, and stained using hematoxylin and eosin (H&E). Histologic examination was made under an optical microscope. In order to measure the amount of newly formed bone in the defect, each sample was analyzed using computer-assisted histomorphometry by creating images of each sample using a Polaroid digital microscope camera (Polaroid Company, Cambridge, MA, USA).

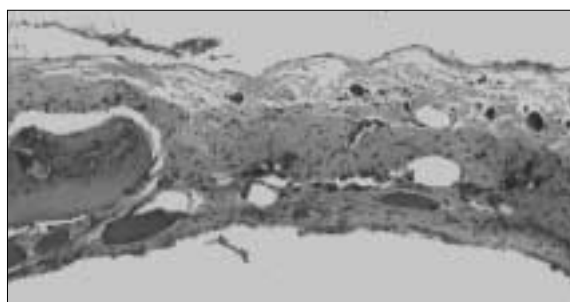


Fig. 1. Histopathologic findings in the control group at 4 weeks. A small area of new-bone formation is seen adjacent to the defect margin (H&E stain, original magnification $\times 100$).

Statistical analysis

The area of newly formed bone was measured from the edge toward the middle of the defect. The results were compared using analysis of variance (ANOVA). Scheff's test was used to determine the significance between the different experimental groups. Values of $p < 0.05$ were considered statistically significant.

III. Results

Control group

At 4 weeks, the formation of new bone was poor, and new bone was only found at the edge of the bone defect (Fig. 1). The remainder of the defect was filled with fibroblasts and proliferating blood vessels. At 8 weeks, the formation of new bone was slightly increased compared with that at 4 weeks but still poor. Most of the new bone was at the edge of the bone defect or in the adjacent area, and the remainder of the defect was filled with fibroblasts and proliferating blood vessels (Fig. 2). The fibrosis was slightly denser and the vascular proliferation slightly reduced compared with those at 4 weeks.



Fig. 2. Histopathologic findings in the control group at 8 weeks. New-bone formation is only seen adjacent to the defect margin (H&E stain, original magnification $\times 100$).

Experimental group I (Particulate dentin and plaster of Paris mixture alone)

At 4 weeks, new bone formation was detected along the edge of the bone defect and in the central area. The organization of woven bone was evident peripherally, and the new bone was fused to the adjacent bone. Bony trabeculae formation was seen locally (Fig. 3). Some fibrosis and infiltration of chronic inflammatory cells were detected. In several places, the edge of the implant was resorbed and connected to new bone.

At 8 weeks, the area of newly formed woven bone was greater than that at 4 weeks, and the bone was well fused (Fig. 4). In some cases, continuous, uninterrupted new bone filled the defect. The implants were fused to the new bone. In some cases, the edge of the implant had been

resorbed, and the original shape of the implant was difficult to distinguish.

Experimental group II (Particulate dentin, plaster of Paris, and alginate)

At 4 weeks, new woven bone was seen and well-developed bone trabeculae formed over a wide area. In some areas, lamellar bone had formed (Fig. 5). In cases of poor bone formation, the implants could still be clearly detected; in some cases with good bone formation, extensive resorption had occurred, and the implant was difficult to identify.

At 8 weeks, more new woven bone had formed than at 4 weeks, and it was more organized, with lamellar bone formation (Fig. 6).

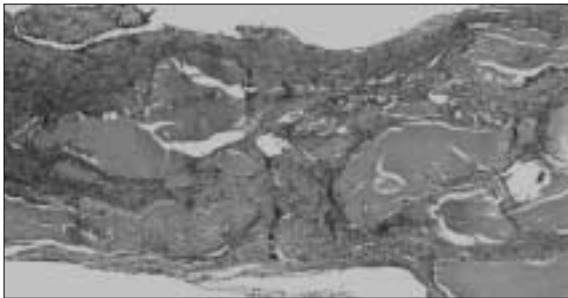


Fig. 3. Histopathologic findings in the group with particulate dentin and plaster of Paris alone at 4 weeks. Newly formed woven bone creating a fused, trabecular pattern is seen. Implanted chips are discernible (H&E stain, original magnification $\times 100$).

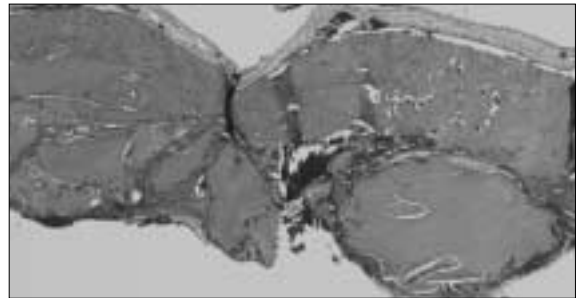


Fig. 4. Histopathologic findings in the group with particulate dentin and plaster of Paris alone at 8 weeks. The newly formed woven bone is more widely fused than that in Fig. 2. The implanted chips are still discernible (H&E stain, original magnification $\times 100$).

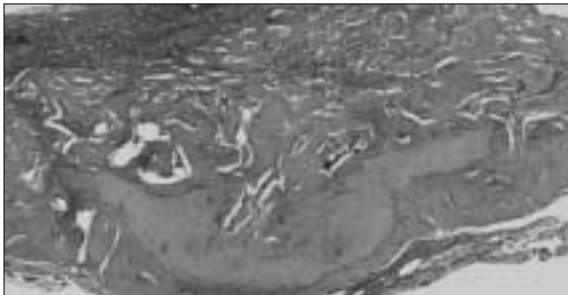


Fig. 5. Histopathologic findings in the group with particulate dentin, plaster of Paris, and alginate at 4 weeks. The newly formed woven bone created well-developed trabeculae and focal areas of lamellar bone (H&E, original magnification $\times 100$).




Fig. 6. Histopathologic findings in the group with particulate dentin, plaster of Paris, and alginate at 8 weeks. The newly formed woven bone is more abundant, and organized lamellar bone is seen (H&E stain, original magnification $\times 100$).

Table 1. Histomorphometric Analysis of the New Bone-forming Activity in Each Group at 4 and 8 weeks (units: mm²)

Group	Control	Group I	Group II
4 weeks	0.220±0.036	2.660±0.759*	2.784±0.569*
8 weeks	0.293±0.035	2.848±1.333*	3.260±0.699*

Mean ± standard deviation.

*Significantly more new bone-forming activity was seen in the experimental groups than in the control group.

Statistical analysis

In this study, the differences within groups at 4 and 8 weeks were not significant ($p > 0.05$), nor were the differences between the two experimental groups at 4 and 8 weeks. There was a statistically significant ($p < 0.05$) difference in new bone formation between the two experimental groups and the control group in each period (Table 1).

Although the difference between the two experimental groups was not statistically significant, a tendency for superior new bone formation was detected with the combination of particulate dentin, plaster of Paris, and alginate.

IV. Discussion

Alternatives to autogenous bone as graft materials are needed for the aesthetic and functional restoration of bone defects in clinical dentistry. Although autogenous bone is currently considered the best graft material^{1,3,4}, the amount of autogenous bone that can be harvested is limited, and morbidity can follow surgery at the donor site^{1,2,26}. In order to overcome these problems, studies have examined the use of allogenic bone, heterogenous bone, and synthetic materials¹. But, the use of graft materials other than autogenous bone runs the risk of inflammation owing to antigenicity.

Since Dreesman first tested the use of plaster of Paris (calcium sulfate), mixtures of particulate dentin and plaster of Paris have been studied as bone substitutes in experimental and clinical studies¹². Particulate dentin (tooth ash, tooth particles) is derived from teeth and is composed

mainly of HA^{1,3}.

De Leonardis and Pecora²⁷ reported a 98.5% overall success rate for 130 implants one year post-implantation, using sinus grafting with calcium sulfate. This suggested the suitability of calcium sulfate for sinus grafting.

Najjar *et al.*¹³ examined whether the addition of calcium sulfate to HA implant material improved its working properties without adversely affecting its osseointegration capability. The highest rate of bone ingrowth occurred with an HA composite (HA plus calcium sulfate), followed by HA alone. Bone was deposited directly on the surface of HA and HA composite implant materials. Calhoun *et al.*²⁸ reported that natural gypsum produced little tissue reaction, such as inflammation. McKee and Bailey²⁹ observed that the worst problem resulting from the use of plaster of Paris was infection. They also reported that because such infection could be controlled effectively, successful replacement of the calcium sulfate with new bone occurred with or without the presence of the periosteum.

In an animal study, Kim *et al.*⁷ reviewed the cytotoxicity and sensitivity of particulate dentin and found that it had no cytotoxicity, it produced no allergic reaction, and it could be used safely in humans. In a retrospective study of ten patients whose jaw defects were reconstructed using a particulate dentin and plaster of Paris mixture, Kim *et al.*¹ stated that this mixture was an effective, easily manipulable bone substitute material. Furthermore, Kim *et al.*⁶ used this mixture to reconstruct the defect around an implant and reported excellent bone-implant contact, suggesting the extensive clinical application of plaster of Paris. Kim *et al.*¹⁶ found that the implanted particulate dentin and plaster of Paris implants were broken into small particles and that the number of particles decreased gradually over the first eight postoperative weeks. Most of the implanted sites were repaired by newly formed bone by the twelfth postoperative week.

Many macrophages proliferate during the inflammatory response. Macrophages use oxygen in a series of biochemical reactions to kill microor-

ganisms by forming oxygen free radicals, which eventually become hydroxyl radicals that are lethal to the cells. Therefore, minimizing inflammation during bone grafting is a must for effective bone healing²⁵⁾. Park *et al.*³⁰⁾ explored the role of alginate as an antioxidant. They suggested that alginate is a biocompatible substance that could be used in conjunction with grafting to reconstruct bone defects safely and effectively.

In this study, we expected that alginate would act as an antioxidant, owing to its antimicrobial and anti-parasitic effects and to clinical results in arthritic patients²⁵⁾, and would thereby reduce the number of cytotoxic free radicals and the inflammatory reaction in response to grafting with a particulate dentin and plaster of Paris mixture, resulting in effective bone healing. In this study, the differences within groups at 4 and 8 weeks were not significant ($p > 0.05$), nor were the differences between the two experimental groups at 4 and 8 weeks. In comparison with the control group, however, both experimental groups showed superior new bone formation.

Although the difference between the two experimental groups was not statistically significant, a tendency for superior new bone formation was detected with the combination of particulate dentin, plaster of Paris, and alginate. Furthermore, more fusion of woven bone and bony trabeculae formation occurred in this group, suggesting that oligosaccharides play a role in the formation and maturation of new bone.

In conclusion, the treatment of bone defects by grafting with a mixture of particulate dentin and plaster of Paris alone or with alginate significantly improved the formation of new bone, both quantitatively and qualitatively. The oligosaccharide treatment appeared to improve the formation of new bone quantitatively and qualitatively.

References

1. Kim SG, Yeo HH, Kim YK : Grafting of large defects of the jaws with a particulate dentin-plaster of Paris combination. *Oral Surg Oral Med Oral Pathol Oral Radiol Endod* 88 : 22, 1999.
2. Kim SG, Kim HK, Lim SC : Combined implantation of particulate dentine, plaster of Paris, and a bone xenograft (Bio-Oss) for bone regeneration in rats. *J Craniomaxillofac Surg* 29 : 282, 2001.
3. Kim SG, Chung CH, Kim YK, et al : Use of particulate dentin-plaster of Paris combination with/without platelet-rich plasma in the treatment of bone defects around implants. *Int J Oral Maxillofac Implants* 17 : 86-94, 2002.
4. Kim SG, Kim YK : Use of a bone wax analogue to determine the amount of chin bone needed for sinus augmentation. *J Oral Maxillofac Surg* 60 : 600, 2002.
5. Kim SG, Kim WK, Park JC, et al : A comparative study of osseointegration of Avana implants in a demineralized freeze-dried bone alone or with platelet-rich plasma. *J Oral Maxillofac Surg* 60 : 1018, 2002.
6. Kim SG, Chung CH, Kim YK : Grafting defects using a particulate dentin-plaster of Paris combination for implant placement: a case report. *Hosp Dent Oral Maxillofac Surg* 13 : 127, 2001.
7. Kim YK, Kim SG, Lee JH : Cytotoxicity and hypersensitivity test of toothash. *J Korean Maxillofac Plastic Reconstructive Surg* 23 : 391, 2001.
8. Aspenberg P, Andolf E : Bone induction by fetal and adult human bone matrix in athymic rats. *Acta Orthop Scand* 60 : 195, 1989.
9. Hosny M, Sharawy M : Osteoinduction in rhesus monkeys using demineralized bone powder allografts. *J Oral Maxillofac Surg* 43 : 837, 1985.
10. Hosny M, Sharawy M : Osteoinduction in young and old rats using demineralized bone powder allografts. *J Oral Maxillofac Surg* 43 : 925, 1985.
11. Snyders RV, Eppley BL, Krukowsky M : Enhancement of repair in experimental calvarial bone defects using calcium sulfate and dextran beads. *J Oral Maxillofac Surg* 51 : 517, 1993.
12. Frame JW : A composite of porous calcium sulfate dihydrate and cyanoacrylate as a substitute for autogenous bone. *J Oral Surg* 38 : 251, 1980.
13. Najjar TA, Lerdrit W, Parsons JR : Enhanced osseointegration of hydroxyapatite implant material. *Oral Surg Oral Med Oral Pathol* 71 : 9, 1991.
14. Cho YH : A light and scanning electron microscopic study on the implant of toothash-porcelain mixture. *J Korean Academy Prosthet* 22 : 33, 1984.
15. Wittkamp AR : Fibrin glue as cement for HA-granules. *J Craniomaxillofac Surg* 17 : 179, 1989.
16. Kim YK, Yeo HH, Park IS : The experimental study on the healing process after inlay implantation of toothash-plaster mixture block. *J Korean Maxillofac Plastic Reconstructive Surg* 18 : 253, 1996.
17. Kim SY, Kim SG, Lim SC, Bae CS : Effects on bone formation in ovariectomized rats after implantation of tooth ash and plaster of Paris mixture. *J Oral Maxillofac Surg* 62 : 852, 2004.
18. Donath K, Rohrer MD, Hormann K : Mobile and immobile hydroxyapatite integration and resorption and its influence on bone. *J Oral Implantol* 13 : 120, 1987.
19. Pecora GE, Leonardis DD, Rocca CD, et al : Short-term healing following the use of calcium sulfate as a grafting material for sinus augmentation: a clinical report. *Int J Oral Maxillofac Implants* 13 : 866, 1998.
20. De Vos P, De Haan B, Van Schilfgaarde R : Effect of the alginate composition on the biocompatibility of alginate-polylysine microcapsules. *Biomaterials* 18 :

- 273, 1997.
21. Vandebossche GM, Bracke ME, Cuvelier CA, et al : Host reaction against empty alginate-polylysine microcapsules. Influence of preparation procedure. *J Pharm Pharmacol* 45 : 115, 1993.
 22. Milella E, Barra G, Ramires PA, et al : Poly(L-lactide)acid/alginate composite membranes for guided tissue regeneration. *J Biomed Mater Res* 57 : 248, 2001.
 23. Alsberg E, Anderson KW, Albeiruti A, et al : Cell-interactive alginate hydrogels for bone tissue engineering. *J Dent Res* 80 : 2025, 2001.
 24. Okuda K, Nakajima Y, Irie K, et al : Transforming growth factor-beta 1 coated beta-tricalcium phosphate pellets stimulate healing of experimental bone defects of rat calvariae. *Oral Dis* 1 : 92, 1995.
 25. Simpson JA, Smith SE, Dean RT : Scavenging by alginate of free radicals released by macrophages. *Free Radic Biol Med* 6 : 347, 1989.
 26. Misch CE : *Contemporary Implant Dentistry: bone augmentation for implant placement: keys to bone grafting*. 2nd edn. Mosby, St. Louis 1998, 451-467.
 27. De Leonardis D, Pecora GE : Augmentation of the maxillary sinus with calcium sulfate: one-year clinical report from a prospective longitudinal study. *Int J Oral Maxillofac Implants* 14 : 869, 1999.
 28. Calhoun NR, Neiders ME, Greene GWJr : Effects of plaster-of-paris implants in surgical defects of mandibular alveolar processes of dogs. *J Oral Surg* 25 : 122, 1967.
 29. McKee JC, Bailey BJ : Calcium sulfate as a mandibular implant. *Otolaryngol Head Neck Surg* 92 : 277, 1984.
 30. Park KK, Kim SG, Lim SC, et al : Effect of alginate on early bone healing of demineralized freeze-dried bone grafts in rats. *Hosp Dent (Tokyo)* 15 : 107, 2003.

저자 연락처

우편번호 501-825
광주광역시 동구 서석동 421
조선대학교 치과대학 인체생물학교실
김생곤

원고 접수일 2004년 11월 20일
게재 확정일 2005년 2월 4일

Reprint Requests

Sang-Gon Kim
Dept. of Human Biology, College of Dentistry, Chosun University
421, Seosuk-Dong, Dong-Gu, Gwangju, 501-825, Korea
Tel : 82-62-230-6871 Fax : 82-62-228-7316
E-mail : sgakim@chosun.ac.kr

Paper received 20 November 2004
Paper accepted 4 February 2005