

The Effect of Estrogen Deficiency on Rat Pulpodentinal Complex

Miri Kim¹, Won-Kyung Yang¹, Jin Baek², Jong-Jin Kim², Won-Kyung Kim³, Young-Kyoo Lee^{3*}

¹*Department of Conservative Dentistry, Asan Medical Center, Seoul,*

²*Department of Prothodontics, Asan Medical Center, Seoul,*

³*Department of Periodontology, Asan Medical Center, Seoul*

ABSTRACT

The purpose of this study was to investigate the effects of estrogen deficiency on pulpodentinal complex of tooth in ovariectomized rats. Thirty female Sprague-Dawley rats, 10 weeks old, were used. Rats were grouped into two groups. One group (n = 15) was subjected to sham surgery (SHAM) and the other group (n = 15) was ovariectomized bilaterally (OVX). Animals were sacrificed 12 weeks later, and their mandibular molars and associated periodontal supporting tissues were dissected out, and fixed in 10% buffered formalin. For comparison of groups, immunostained for osteonectin. Histomorphometrical measurement of change of teeth was performed using an image analysis system and paired t-test was used and the level of significance for overall differences was set at $p < 0.05$.

In immunostaining of osteonectin, they were significantly different from each other. The predentin thickness in OVX rats was wider than in SHAM rats. And in SHAM rats, osteonectin was more specifically stained in predentin areas than in OVX rats. These results indicate that estrogen deficiency increased the unmineralized predentin areas and decreased osteonectin content in pulpal tissues in rats. If our result is applicable to human studies, odontoblast is affected by estrogen deficiency. [J Kor Acad Cons Dent 30(5):402-408, 2005]

Key words: Ovariectomy, Estrogen deficiency, Osteonectin, Predentin, Pulp

- Received 2005.3.23., revised 2005.6.22., accepted 2005.8.24. -

I. INTRODUCTION

Dental pulp, which occupies the center of each tooth, consists of soft connective tissue. Although the composition and structure of pulp differ from

those of dentin, the two tissues exist in an intimate embryologic and functional relationship. The dentin and pulp are usually considered together as a functional complex termed the pulpodentin complex¹⁾. Osteoporosis is a condition of low bone mass and microarchitectural deterioration of bone tissue, which can result in pain, deformity, or fracture. According to the World Health Organization (WHO), osteoporosis is considered to be present when bone mineral density (BMD) is 2.5 standard deviations (SD) below the young normal BMD²⁾. Bone loss due to osteoporosis has been

* Corresponding author: Young-Kyoo Lee

Department of Dentistry, Asan Medical Center
388-1 Poongnap-Dong, Songpa-Gu, Seoul, Korea 138-736
Tel: 82-2-3010-3824 Fax: 82-2-3010-6967
E-mail: kmr333@unitel.co.kr

※ This study was supported by a grant (2004-359) from the Asan Institute for Life Sciences, Seoul, Korea.

reported to affect the jaws³⁾, and ovariectomy has been shown to cause significant decreases of trabecular and cortical BMD⁴⁾. Although BMD has been shown to be related to tooth loss⁵⁾, and estrogen deficiency affects incisor odontoblasts⁶⁾, but it has not been determined whether osteoporosis affects the pulpodentinal complex of teeth.

In recent years, a number of morphologic studies have used immunohistochemical techniques to localize matrix proteins in bone. Osteonectin is a glycoprotein of 32 kD, and a homologous protein, SPARC, an anagram for secreted protein, acidic and rich in cysteine^{7,8)}. High levels of immunodetectable osteonectin are found in active osteoblasts and marrow progenitor cells, odontoblasts, periodontal ligaments and gingival cells and some chondrocytes and hypertrophic chondrocytes. Osteonectin can be detected in osteoid, bone matrix proper and dentin. Osteonectin was originally isolated from bone, and high affinity binding of calcium ions to this protein suggested that osteonectin plays an important role in mineralization of bone⁹⁾.

The purpose of this study was to evaluate the changes in the pulpodentinal complex of teeth in rats by comparing and analyzing immunohistochemical sections in ovariectomized rats.

II. MATERIALS AND METHODS

1. Animal preparation

The animal experimental protocol was approved by the Animal Research Committee of Asan Medical Center. Thirty female Sprague-Dawley rats, 10 weeks old, were fed standard rat chow and water *ad libitum*. One group of fifteen rats was subjected to sham surgery (SHAM), and the other group of fifteen rats was ovariectomized bilaterally (OVX). Rats were anesthetized with ketamin, xylazine, and local anesthetics. In the Sham group, the ovaries were exposed through the skin, abdominal muscles, and peritoneum by making 1-cm incisions and then sutured. In the OVX group, the ovaries were exposed, the ovarian tubes were ligated using silk threads, the ovaries

were excised, and the incisions were sutured back.

Twelve weeks later, the rats were sacrificed by subcutaneous injection of an overdose of pentobarbital sodium and perfused with 10% buffered formalin through the aorta. Mandibular molars and their associated periodontal supporting tissues were dissected out and fixed in 10% buffered formalin.

Block sections included three molars. For radiograph, each section was placed directly onto a dental intraoral occlusal X-ray film. The dental X-ray unit was set at 70KVp, 7mA and an exposure time of 0.1 s: X-rays were projected perpendicularly at a target-film distance of approximately 300 mm.

2. Histologic preparation

The sections were decalcified with 10% EDTA for 5 - 7 days. The teeth were processed by standard paraffin embedding procedures and at least five μ m thick step serial sections per tooth were taken at 0.5 to 1.0 mm intervals. The resultant sections were immunostained. For immunohistochemistry, tissue sections were picked up on silanized slides from a protein-free water bath, air-dried overnight, deparaffinized and dehydrated with alcohol, and washed with automation buffer. Sections were treated with enzyme before immunostaining. The test sections were received a 1:750 dilution of the primary antiserum: mouse anti osteonectin (Zymed 33-5500, San Francisco, CA, USA) in 1X buffer, washed with automation buffer, and incubated with secondary antibody (Dako LSAB system HRP; Carpinteria, CA, USA) for 30minutes at room temperature. After washing, the sections were treated with streptavidine enzyme (Dako, Carpinteria, CA, USA), washed thoroughly, counterstained with Mayer's hematoxylin, washed in running water, and mounted.

3. Histologic evaluation

Histomorphometrical measurement of change of teeth was performed using an image analysis sys-

tem (BMI plus, Ver.2.19) coupled to a video camera on a light microscope (Nikon Eclipse TE 200, Tokyo, Japan). The predentin thickness in tooth (M1) was measured in ten different points. The three evaluators were blinded to the origin of the rats prior to evaluating the histological sections. Paired t-test was used and the level of significance for overall differences was set at $p < 0.05$.

III. RESULTS

In radiographs, generally the pulpodentinal complexes of OVX and SHAM rats did not differ. (Figure 1 & 2).

Immunohistochemical staining for osteonectin, however, showed significant differences in the two groups of rats. The predentin thickness in OVX rats was greater than in SHAM rats. Paired t-test was used and the level of significance for overall differences was set at $p < 0.05$. (Table 1).

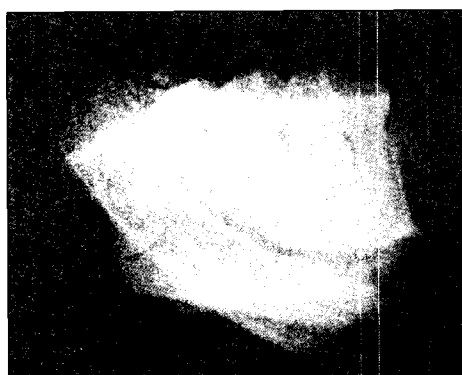


Figure 1. Radiographic view of mandibular sections of SHAM Rat.




Figure 2. Radiographic view of mandibular sections of OVX Rat.

Table 1. The mean and standard deviation for predentin thickness of the OVX rats and SHAM rats are shown ($p < 0.05$)

	SHAM	OVX
Rat 1	0.8	1.2
Rat 2	1.0	2.0
Rat 3	0.7	1.5
Rat 4	0.6	1.6
Rat 5	0.8	1.5
Rat 6	0.7	1.4
Rat 7	0.6	1.8
Rat 8	0.9	1.7
Rat 9	1.0	2.0
Rat 10	0.7	1.2
Rat 11	0.6	1.1
Rat 12	0.9	1.5
Rat 13	0.8	1.2
Rat 14	0.9	1.2
Rat 15	1.1	1.2
Mean (S.D.)	0.81 (0.16)	1.47 (0.30)




Figure 3. Immunohistochemical staining of SHAM Rat (original magnification $\times 400$). Osteonectin (Arrow-brown) in the cytoplasm of active, matrix-producing odontoblasts in predentin areas.




Figure 4. Immunohistochemical staining of SHAM Rat (original magnification $\times 400$). Adjoining immunoreactive polarized odontoblasts (Arrow) were stained heavily with osteonectin antibodies.




Figure 5. Immunohistochemical staining of OVX Rat (original magnification $\times 400$). Absence of staining of quiescent odontoblasts in the predentin areas.

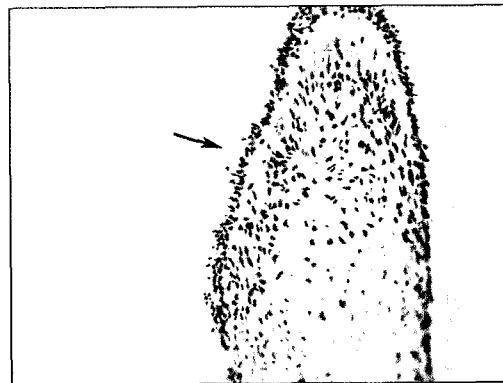


Figure 6. Immunohistochemical staining of OVX Rat (original magnification $\times 400$). Weakly osteonectin labeling (Arrow) is present in polarized odontoblasts, but absent from the cells of the central pulp and dentin.

Furthermore, in SHAM rats, osteonectin was more specifically stained in predentin areas than in OVX rats. In SHAM rats, the mineralized compartment of intratubular dentin was not immunoreactive, whereas the unmineralized predentin and adjoining immunoreactive polarized odontoblasts were stained heavily with antibodies to osteonectin antibodies. In OVX rats, however, the predentin layers were weakly stained with osteonectin antibodies. The osteonectin staining pattern in fibrous dental pulp cells of OVX rats was similar to that of SHAM rats. Generally, weakly osteonectin labeling is present in polarized

odontoblasts, but absent from the cells of the central pulp and dentin (Figure 3 - 6).

These results indicate that estrogen deficiency increased unmineralized predentin areas and decreased osteonectin contents of predentin areas.

IV. DISCUSSION

Osteonectin is the major noncollagenous protein in the extracellular matrix of developing bones and teeth. Though the function of this protein is not known, its location in newly deposited osteoid, its high affinity for calcium, hydroxyap-

atite, and collagen, and its reduction in bone from some animals and humans with osteogenesis imperfecta point up its importance to bone metabolism. The high degree of cross-species immunoreactivity observed using monoclonal antibodies against bone osteonectin indicates that common epitopes have been conserved during evolution¹⁰⁾. Although bone is a particularly rich source of osteonectin, this protein and/or its mRNA are also detected in several non-bone tissues^{11,12)}.

Dentin is composed primarily of proteins common to both dentin and bone, including collagen types I, III, and V, bone sialoprotein, osteopontin, dentin matrix protein-1, osteocalcin, and osteonectin^{13,14)}. In the previous study⁹⁾, periodontal tissues demonstrated different staining intensities for osteonectin: strong staining existed in osteoid and moderate staining was seen in the PDL. The intense staining for osteonectin specifically in the osteoid, but not mineralized bone and cementum leads us to speculate that osteonectin may prevent premature mineralization of the osteoid by inhibiting hydroxyapatite formation. Therefore, immunostaining of osteonectin was effective tool for hard tissue regeneration.

The stronger labeling of osteonectin in pulps of dental germs than in those of erupted teeth suggests that osteonectin is more functionally active in young odontoblasts than in older odontoblasts¹⁵⁾. We have observed similar results, in that the mineralized compartment of intratubular dentin in Sham rats was not immunoreactive, whereas the unmineralized predentin and adjoining immunoreactive polarized odontoblasts stained heavily with osteonectin antibodies in these animals.

As like previous study¹⁶⁾, the use of conventional radiographs alone to assess bone mineral density of rat mandible as unsatisfactory, and should not be regarded as a substitute for histological examination for the determination of bone mineral loss.

Predentin, which is located adjacent to the pulp tissue, is 2 to 6 μ m wide, depending on the activity of the odontoblasts in human. Predentin is the earliest form of dentin and is not mineralized. As the collagen fibers undergo mineralization at the

predentin-dentin front, the predentin becomes dentin and a new layer of predentin forms circumferentially. Thickening of the predentin zone may be due to a cumulative lack of calcification over time or may result from the excessive formation of predentin by odontoblasts. The cause of the thickened predentin zone may be twofold. First, there may be a cumulative lack of calcification of physiologically deposited predentin with time. Second, the thickened predentin layer may, in part, be the result of excessive formation of predentin by odontoblasts¹⁷⁾.

Estrogen deficiency causes osteoporosis, which is associated with the enhancement of bone remodeling soon after ovariectomy. In another study, long-term estrogen deficiency in ovariectomized rats decreased the mandibular cortical thickness¹⁸⁾. Loza et al.²⁾ examined the relationship between osteoporosis and intraoral bone tissues and reported that the alveolar bone loss in the presence of progressed periodontal disease is more significant in men than with in women, suggesting that hormones and habitual factors such as drinking and smoking affect men more seriously than osteoporosis in women. Postmenopausal osteoporosis progresses immediately after menopause, suggesting it is due primarily to the lack of estrogen production by the ovaries¹⁹⁾.

We found that the pulpodentinal complex demonstrated different staining intensities for osteonectin. While intense staining in the osteonectin may indicate active changes in the pulpodentinal complex, weak staining of osteonectin in OVX rats may indicate low content of proteins. These findings suggest that predentin is the metabolic equivalent of osteoid in bone and that increases in predentin thickness may therefore be a reliable indicator of estrogen deficiency. If our result is applicable to human studies, odontoblast is affected by estrogen deficiency.

Little is known, however, about the effects of ovariectomy on odontoblast metabolism, suggesting the need for additional studies to determine the participation of this protein in the metabolism of dental pulp.

V. CONCLUSION

We investigated changes in the pulpodentinal complex resulting from ovariectomy. Fifteen 10-week-old female Sprague-Dawley rats were subjected to sham surgery (SHAM), and other rats were ovariectomized bilaterally (OVX). Animals were sacrificed 12 weeks later, and their mandibular molars and associated periodontal supporting tissues were dissected out and fixed in 10% buffered formalin. Each section was dentally radiographed and immunostained for osteonectin. We found that the two groups differed significantly in immunostaining for osteonectin. The predentin thickness in OVX rats was wider than in Sham rats, whereas, in the latter, osteonectin was more specifically stained in predentin areas than in OVX rats. These results indicate that estrogen deficiency increases unmineralized predentin areas and decreases osteonectin contents of the pulpodentinal complex.

REFERENCES

- Hargreaves KM, Goodis HE. Seltzer and Bender's Dental Pulp. Quintessence publishing Co., Chicago, p95-99, 2002.
- Geurs NC, Lewis CE, Jeffcoat MK. Osteoporosis and periodontal disease progression. *Periodontology* 2000 32:105-110, 2003.
- Jiang G, Matsumoto H, Fujii A. Mandible bone loss in osteoporosis rats. *J Bone Miner Metab* 21:388-395, 2003.
- Gilles JA, Carnes DL, Dallas MR, Holt SC, Bonewald LF. Oral bone loss is increased in ovariectomized rats. *J Endodon* 23:419-422, 1997.
- Kribbs PJ, Chestnut CH 3rd, Ott SM, Kilcoyne RF. Relationships between mandibular and skeletal bone in a population of normal woman. *J Prosthet Dent* 63: 86-89, 1990.
- Yokose S, Zhungfeng C, Tajima Y, Fujieda K, Katayama I, Katayama T. The effects of estrogen deficiency on glycosylation of odontoblasts in rats. *J Endodon* 24:645-647, 1998.
- Termine JD, Kleinman HK, Whitson SW, Conn KM, McGarvey ML, Martin GR. Osteonectin, a bone-specific protein linking mineral to collagen. *Cell* 26:99-105, 1981.
- Jundt G, Berghauer KH, Termine JD, Schulz A. Osteonectin -a differentiation marker of bone cells. *Cell Tissue Res* 248:409-415, 1987.
- Kim M, Kim B, Yoon S. Effect on the healing of periapical perforations in dogs of the addition of growth factors to calcium hydroxide. *J Endodon* 27:734-737, 2001.
- Bolander ME, Robey PG, Fisher LW, Conn KM, Prabhakar BS, Termine JD. Monoclonal antibodies against osteonectin show conservation of epitopes across species. *Calcif Tissue Int* 45:74-80, 1989.
- Sage H, Mecham R, Johnson C, Bornstein P. Fetal calf ligament fibroblasts in culture secrete a low molecular weight collagen with a unique resistance to proteolytic degradation. *J Cell Biol* 97:1933-1938, 1983.
- Tracy RP, Shull S, Riggs BL, Mann KG. The osteonectin family of proteins. *Int J Biochem* 20:653-660, 1988.
- Papagerakis P, Berdal A, Mesbah M, Peuchmaur, Malaval L, Nydegger J, Simmer J, Macdougall M. Investigation of osteocalcin, osteonectin, and dentin sialophosphoprotein in developing human teeth. *Bone* 30:377-385, 2002.
- Ninomiya M, Ohishi M, Kido J, Ohsaki Y, Nagata T. Immunohistochemical localization of osteopontin in human pulp stones. *J Endodon* 27:269-272, 2001.
- Garcia JM, Martins MD, Jaeger RG, Marques MM. Immunolocalization of bone extracellular matrix proteins (type I collagen, osteonectin and bone sialoprotein) in human dental pulp and cultured pulp cells. *Int Endod J* 36:404-410, 2003.
- Chong BS, et al. Radiological assessment of the effects of potential root-end filling materials on healing after endodontic surgery. *Endod Dent Trauma* 13:176-179, 1997.
- Wysocki GP, Daley TD, Ulan RA. Predentin changes in patients with chronic renal failure. *Oral Surg Oral Med Oral Pathol* 56:167-173, 1983.
- Yang J, Farnell D, Devlin H, Horner K, Graham J. The effect of ovariectomy on mandibular cortical thickness in the rat. *J Dent* 33:123-129, 2005.
- Kim SY, Kim SG, Lim SC, Bae CS. Effects on bone formation in ovariectomized rats after implantation of tooth ash and plaster of Paris mixture. *J Oral Maxillofac Surg* 62:852-857, 2004.

국문초록

에스트로겐 호르몬 결핍 백서에서의 상아-치수 복합체의 변화에 관한 연구

김미리¹ · 양원경¹ · 백진² · 김종진² · 김원경³ · 이영규^{3*}

서울아산병원 ¹보존과, ²보철과, ³치주과

난소 절제술을 시행한 백서에서 에스트로겐 호르몬의 결핍으로 인한 상아-치수 복합체의 변화를 관찰하였다. 30 마리의 암컷 Sprague-Dawley rats을 두 군으로 나누어 1 군은 Sham-surgery를 시행하였고, 2 군은 양측 난소 절제술을 시행하였다.

백서는 12주 뒤에 모두 희생시켜, 하악 치아와 인접한 치주조직을 포함하여 절제하였고, 10% 중성 포르말린 용액에 고정하였다. 두 군의 차이점을 비교하기 위하여 방사선 사진을 촬영하고, osteonectin을 이용한 면역 화학 염색법을 시행하였다. 조직 형태학적 차이점을 측정하기 위하여 영상 분석 프로그램을 사용하였고, 분석 방법으로는 Paired t-test를 사용하였다 ($p < 0.05$).

Osteonectin을 이용한 면역 화학 염색 결과, 두 군간에는 유의성 있는 차이점이 존재하였다. 난소 절제술을 시행한 백서군에서는 전상아질층의 두께가 현저히 증가하였고, Sham-surgery 군에서는 전상아질 층과 치수 조직에서 osteonectin이 좀 더 특이적으로 염색되어 나타났다.

이러한 결과로 결론지어보면, 백서에서 인위적으로 난소 절제술을 시행하였을 때 광화되지 않은 전상아질층의 두께가 증가하고, 치수 조직과 전상아질층내의 osteonectin 함량이 감소되며, 결국 에스트로겐 결핍은 조상아 세포의 기전을 변화시킨다고 할 수 있다.

주요어: 난소절제술, 에스트로겐 결핍, Osteonectin, 전상아질, 치수