

A human infection of *Echinostoma hortense* in duodenal bulb diagnosed by endoscopy

Young-Doo CHANG¹⁾, Woon-Mok SOHN²⁾, Jae-Hwa RYU³⁾,
Shin-Yong KANG¹⁾ and Sung-Jong HONG^{1)*}

¹⁾Department of Parasitology, College of Medicine, Chung-Ang University, Seoul 156-756,

²⁾Department of Parasitology, Gyeongsang National University College of Medicine, Jinju 660-751,

³⁾Ryujaehwa Internal Medicine Clinic, Bangu-dong 446, Chung-gu, Ulsan 681-261, Korea

Abstract: As gastroduodenoscopy performed more frequently, case reports of human echinostomiasis are increasing in Korea. A Korean woman presented at a local clinic with complaints of abdominal pain and discomfort that had persisted for 2 weeks. Under gastroduodenoscopy, two motile flukes were found attached on the duodenal bulb, and retrieved with endoscopic forceps. She had history of eating raw frog meat. The two flukes were identified as *Echinostoma hortense* by egg morphology, 27 collar spines with 4 end-group spines, and surface ultrastructural characters. This report may prove frogs to be a source of human echinostome infections.

Key words: *Echinostoma hortense*, duodenal bulb, gastroduodenoscopy, frog

INTRODUCTION

Echinostoma hortense is a member of the Echinostomatidae family, and is characterized by a large elongated body, a head crown with collar spines, a large oral sucker, tandem testes in the anterior body, and rich vitelline glands in the posterior body. The fluke inhabits the small intestine and prefers the upper region. Human echinostomatid infections, about 120 cases, have been reported in Korea. The echinostomatid species with a parasitologic history in Korean are *Echinostoma hortense*, *E. cinetorchis*, *Echinochasmus japonicus* and *Acanthoparypium tyosenense* (Seo et al., 1983, 1985; Ryang et al., 1985; Chai et al., 1994, 2001). Of these *E. hortense* is a dominant

species in Korea. The mountainous villages of inland Korea represent its endemic foci (Lee et al., 1988). Recently human *E. hortense* infections were diagnosed by gastroduodenal endoscopy in Korea (Chai et al., 1994; Lee and Hong, 2002; Cho et al., 2003). Here we describe a case of infection by *E. hortense* in the duodenal bulb, which was diagnosed by upper endoscopy.

CASE RECORD

A Korean woman, 55-year-old, visited a local clinic with complaints of upper abdominal pains and discomfort on October 1999. Her symptoms had persisted for 2 weeks at the time of her visit. She lived in Ulsan-city, Gyeongsangnam-do, Korea. During gastroduodenal endoscopy, two motile flukes were found attached to the duodenal bulb. The flukes were slender, elongate, about 5 mm in length, with a red spot at anterior end (Fig. 1). The flukes were removed from

• Received 29 April 2005, accepted after revision 23 May 2005.

*Corresponding author (e-mail: hongsj@cau.ac.kr)




Fig. 1. Echinostomes (arrows) on the duodenal bulb.

the duodenal bulb with endoscopic forceps. The patient was treated with single dose of praziquantel, 10 mg/kg. After treatment, the abdominal symptoms were subsided.

She had worked in a small restaurant, and had eaten raw frog meat several times about two months before onset of her symptoms. She denied ever eating freshwater fish in raw. Laboratory data were not available. A stool examination revealed six echinostome eggs, but none were found in family members. The eggs were bright yellow, elliptical, thin shelled with a shallow operculum, and measured 114.1 (111.2-118.6) μm long and 76.7 (74.1-79.0) μm wide (Fig. 2).

The flukes were processed for parasitological identification by light and scanning electron microscopic studies. The anterior of the fluke was bent ventrally at the acetabulum, and the surface was wrinkled transversely over the whole body. The body surface was covered with cobblestone-like cytoplasmic processes. Tegumental spines, scale-shaped with a broad base, were densely packed on the anterior surface of the body and then reduced in density and size on moving posteriorly (Fig. 3). The anterior end bulged into a head crown around the oral sucker. The head crown was armed with uninterrupted 27 collar spines, of which the 4 end-group spines were present at the both ends of the the head crown (Fig. 4). The outer surface

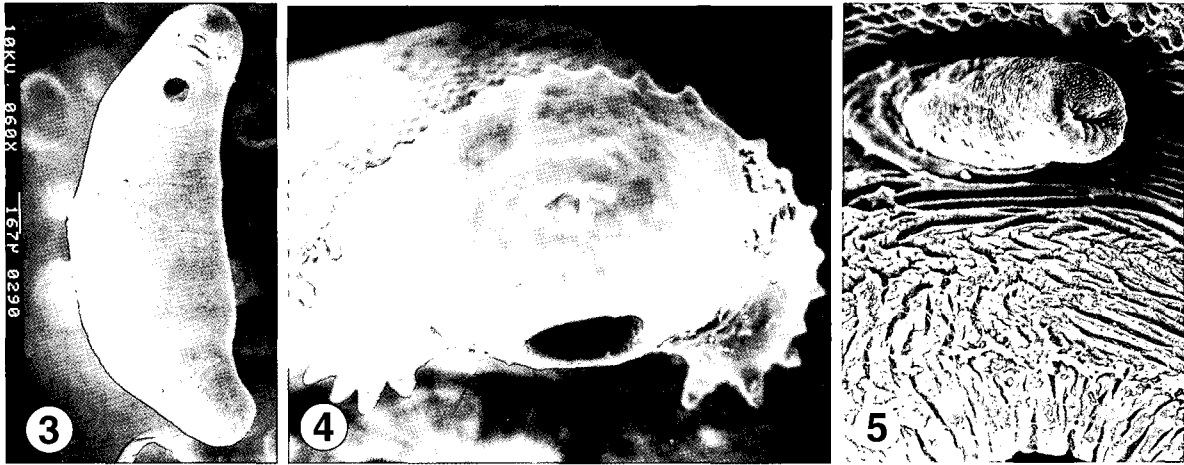


Fig. 2. An egg of *Echinostoma hortense* from the patient. Bar = 54 μm .

of oral sucker was smooth and encircled with ciliated sensory (Type I) papillae arranged in 2-3 rows. Unciliated sensory (Type II) papillae, dome-like round structures, appeared on posterior half of the oral sucker lip. The acetabulum, wide-open, was aspinous with velvety cytoplasmic processes, and surrounded with Type I papillae. The cirrus erected from the genital opening revealed a velvety tegumental surface, and dense Type I sensory papillae, as compared with other parts of the body surface (Fig. 5).

DISCUSSION

The number of collar and end-group spines is species-identifying morphological characteristic of echinostomatid flukes. The echinostomes retrieved from the present patient under scanning electron microscopy revealed 27 and 4 spines, which is a species-characteristic of *E. hortense*. Surface ultrastructures, such as the arrangement of Type I sensory papillae on the oral sucker and around the acetabulum, and scale-shaped tegumental spines distributed at decreasing density posteriorly are consistent with previous descriptions of *E. hortense* (Lee et al., 1986b). After referring to surface ultrastructural characteristics and egg morphology (Seo et al., 1983), the isolated



Figs. 3-5. Scanning electron micrographs of an *Echinostoma hortense* specimen retrieved from the patient. **Fig. 3.** Ventral view. **Fig. 4.** The oral opening and head crown spikes with collar spines. **Fig. 5.** The cirrus erected from the genital pore anterior to the acetabulum.

flukes were identified as *E. hortense*.

Adult *E. hortense* inhabits the upper part of the small intestine in mammalian final hosts. The flukes produce ulcerative lesions in intestinal mucosa, villous atrophy characterized by blunting, villous fusion, and loss of villous tips, and crypt hyperplasia. In the stroma of villi were found inflammatory cell infiltration, vascular congestion, and edema (Lee et al., 1990). The collar spines in the head crown of *E. hortense* were stout and damaged the intestinal mucosa. Ulcerative lesions produced by adult *E. hortense* in the duodenal bulb were previously observed by upper endoscopy (Chai et al., 1994). In consideration of the pathologic findings, the symptoms experienced by the present patient, i.e., epigastric pain and abdominal discomfort, might be provoked by the abrasive action of *E. hortense*. The frequent symptoms reported by infected individuals, though not pathogen-specific, are abdominal pain, cramps, anorexia, postprandial burning, flatulence, and diarrhea (Lee et al., 1986a; Chai et al., 1994; Lee and Hong, 2002). It has also been suggested that chronic and severe infection may cause intestinal villous atrophy and lead to manifestations of malabsorption.

Freshwater fish have been recorded as infection sources of echinostomiasis *hortense*, most frequently loaches in Korea, followed by frogs (Chai et al., 1985; Ryang et al., 1985; Cho et al., 2003). Frog tadpoles

become infected with metacercariae of echinostomes and metamorphose to adult frogs with the metacercariae in their tissues, predominantly in muscles. Metacercariae were previously found mainly in the dorsal pharyngeal wall, body cavity, and mesentery of *Rana nigromaculata* (Rim et al., 1982). People may become infected by eating inadequately cooked frog meat, as occurred in the present case. The reservoir hosts have been recognized to play a significant role in an ecosystem of digenean trematodes. They initiate the trematode's life cycle by supplying trematode eggs to the first intermediate molluscan hosts. Of reservoir hosts, rats and dogs are reported to show a high prevalence of *E. hortense* infection in Korea (Seo et al., 1981). This human case reports that frogs are a source of human echinostome infections in Korea.

REFERENCES

- Chai JY, Han ET, Park YK, Guk SM, Lee SH (2001) *Acanthoparyphium tyosenense*: the discovery of human infection and identification of its source. *J Parasitol* **87**: 794-800.
- Chai JY, Hong SJ, Sohn WM, Lee SH, Seo BS (1985) Studies on intestinal trematodes in Korea XVI. Infection status of loaches with the metacercariae of *Echinostoma hortense*. *Korean J Parasitol* **23**: 18-23.
- Chai JY, Hong ST, Lee SH, Lee GC, Min YI (1994) A case of echinostomiasis with ulcerative lesions in the duode-

- num. *Korean J Parasitol* **32**: 201-204.
- Cho CM, Tak WY, Kweon YO, Kim SK, Choi YH, Kong HH, Chung DI (2003) A human case of *Echinostoma hortense* (Trematoda: Echinostomatidae) infection diagnosed by gastroduodenal endoscopy in Korea. *Korean J Parasitol* **41**: 117-120.
- Lee OJ, Hong SJ (2002) Gastric echinostomiasis diagnosed by endoscopy. *Gastrointest Endosc* **55**: 440-442.
- Lee SK, Chung NS, Ko IH, Ko HI, Chai JY (1986a) Two cases of natural human infection by *Echinostoma hortense*. *Korean J Parasitol* **24**: 77-81 (in Korean).
- Lee SK, Chung NS, Ko IH, Sohn WM, Hong ST, Chai JY, Lee SH (1988) An epidemiological survey of *Echinostoma hortense* infection in Chongsong-gun, Kyungbuk Province. *Korean J Parasitol* **26**: 199-206 (in Korean).
- Lee SH, Hong SJ, Chai JY, Hong ST, Seo BS (1986b) Tegumental ultrastructures of *Echinostoma hortense* observed by scanning electron microscopy. *Korean J Parasitol* **24**: 63-70 (in Korean).
- Lee SH, Noh TY, Sohn WM, Kho WG, Hong ST, Chai JY (1990) Chronological observation of intestinal lesions of rats experimentally infected with *Echinostoma hortense*. *Korean J Parasitol* **28**: 45-52 (in Korean).
- Rim HJ (1982) Echinostomiasis. CRC Handbook Series in Zoonoses, Section C: Parasitic Zoonoses, Vol. III (Trematode Zoonoses) 53-69, CRC Press, Inc. Boca Raton, Florida, USA.
- Ryang YS, Ahn YK, Lee KW, Kim TS, Han MH (1985) Two cases of natural human infection by *Echinostoma hortense* and its second intermediate host in Wonju area. *Korean J Parasitol* **23**: 33-40 (in Korean).
- Seo BS, Cho SY, Hong ST, Hong SJ, Lee SH (1981) Studies on parasitic helminthes of Korea. V. Survey on intestinal trematodes of house rats. *Korean J Parasitol* **19**: 131-136.
- Seo BS, Chun KS, Chai JY, Hong SJ, Lee SH (1985) Studies on intestinal trematodes in Korea XVII. Development of egg lying capacity of *Echinostoma hortense* in albino rats and human experimental infection. *Korean J Parasitol* **23**: 24-32.
- Seo BS, Hong ST, Chai JY, Lee SH (1983) Studies on intestinal trematodes in Korea VIII. A human case of *Echinostoma hortense* infection. *Korean J Parasitol* **21**: 219-223.