

Necrotizing Pneumonia Complicated by *Streptococcus Pyogenes* Bacteremia in Patient with COPD

In Sung Jung, M.D., Do Seok Bang, M.D., Yol Park, M.D.,
Jae Su Kim, M.D., Sung Hoon Lee, M.D., Young Gul Yoon, M.D.,
Beom Cheol Bag, M.D., Ki Man Kang M.D., and Dong Jib Na, M.D.

Department of Internal Medicine, Sun Hospital, Dae Jeon, Korea

=국문초록=

만성 폐쇄성 폐질환 환자에서 *Streptococcus Pyogenes* 에 의한
균혈증을 동반한 괴사성 폐렴 1예

대전 선병원 내과

정인성, 방도석, 박 열, 김재수, 이성훈,
윤영걸, 박범철, 강기만, 나동집

Streptococcus pyogenes 는 지역 사회 폐렴의 드문 원인균으로 독감, 홍역, 만성 폐쇄성 폐질환등의 합병증으로 대부분 발생하고 진행 경과가 빠르며, 고령 및 폐혈증을 동반한 경우 특히 사망률이 높다고 알려져 있다. 저자들은 만성 폐쇄성 폐질환 환자에서 균혈증을 동반한 *Streptococcus pyogenes* 폐렴 1 예를 보고한다. (Tuberculosis and Respiratory Diseases 2004, 56:536-541)

Key words : *Streptococcus pyogenes*, Community acquired Pneumonia.

INTRODUCTION

In the preantibiotic era, group A β -hemolytic streptococcal (GAS) pneumonia was a common clinical entity, accounting for 3 to 5% of community-acquired pneumonia. Most cases occurred after outbreaks of viral illness, such as influenza or me-

asles and local complications, such as empyema, were common. A high mortality rate and rapid progression occurred despite early appropriate antibiotic therapy. A case of pneumonia, complicated with empyema caused by *Streptococcus pyogenes*, was reported by Lim et al in Korea in 1995¹.

Correspondence to :

Dong Jib Na, M.D.

Department of Internal Medicine, SUN HOSPITAL

10-7 Mok-Dong, Jung-Gu, Dae-Jeon, 301-725 Korea

Tel: 82-42-220-8800 Fax: 82-42-335-1431 E-mail: djna@sunhospital.com

Herein, a case of severe community-acquired pneumonia due to *Streptococcus pyogenes* is reported.

CASE REPORT

A 67 year-old-man was admitted to this hospital due to increasing hypoxia with minimal activity. He also reported a productive cough of clear sputum, anorexia and fatigue. Fever, chills, night sweats and hemoptysis were absent.

He had a 10 year history of advanced COPD, including several hospital admissions for acute exacerbation of COPD. These conditions were variously diagnosed as purulent exacerbations of COPD or community-acquired pneumonia. The patient never required intubation. He tended to improve with antibiotics, systemic corticosteroids, and bronchodilator treatments. He was a non-smoker.

A clinical examination revealed a thin, slightly tachypneic patient, with a blood pressure of 150/55 mm Hg, a temperature of 36.8°C, a heart rate of 78 beats/min and a respiratory rate of 26 breaths/min. He was 161 cm in height and weighed 38 kg. The patient was comfortable while resting in bed, but became short of breath when he tried to speak in complete sentences. The patient had clubbing of his fingers and toes. The head, eyes, ears, nose and throat were normal. A lung examination revealed scattered rhonchi and reduced breath sounds over both lung bases. The remainder of the examination was normal. An arterial blood gas analysis showed a pH of 7.44; PCO₂, 35.9 mm Hg; PO₂, 48.9 mm Hg; and oxygen saturation, 86.1%,

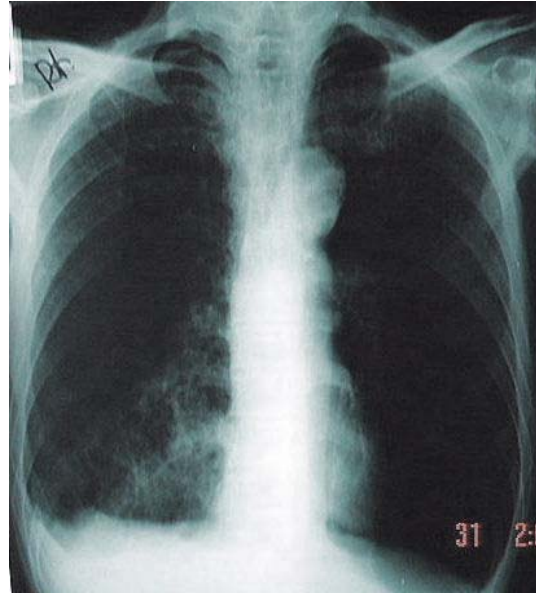


Fig. 1. Chest radiograph on the first day of admission showing some infiltrations of the right lower lobe

while breathing ambient air.

The initial results of the laboratory, liver function and renal function test, and urinalysis were within normal limits. His serum IgE measured 866 IU/mL and WBC count was 22,300 cells/ μ L, with 94% polymorphonuclear cells, 4% lymphocytes and 2% monocytes. His hemoglobin level and platelet count were 14.5 g/dl and 282,000 cells/ μ L, respectively. His chest radiograph showed some suspicious infiltrates of the right lower lobe (Fig. 1). He was admitted to the hospital with a presumed diagnosis of exacerbated COPD.

Appropriate blood and sputum cultures were obtained, and he was initially treated with several antiasthmatic medications, including intravenously methylprednisolone and macrolide, without any relief of symptoms. Subsequently, his

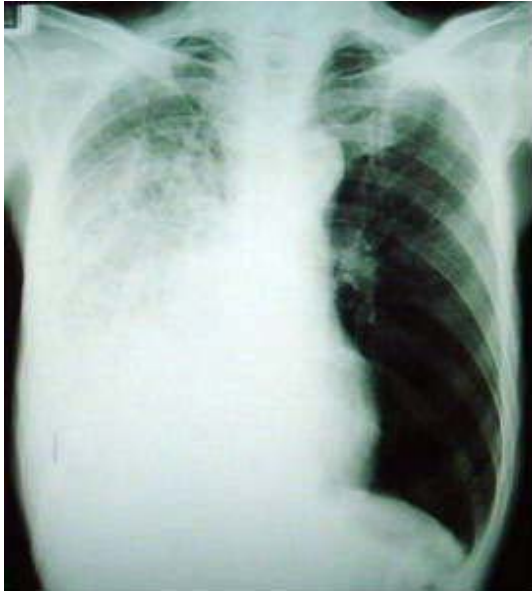

Fig. 2 Posteroanterior chest radiograph 3 days after admission demonstrating increased opacification in the right lower zone

shortness of breath became progressively worse over time, despite the intermittent use of an epinephrine and ventolin nebulizer for dyspnea.

Three days after the patient's admission to hospital, he suddenly became cyanotic, diaphoretic and only semiconscious, with a BP of 150/90 mm Hg and a pulse of approximately 134 beats/min. An arterial blood gas analysis on 2 L/min of oxygen by nasal cannula revealed the following: pH, 7.26; PCO_2 , 46.4 mm Hg; PO_2 , 63.4 mm Hg and oxygen saturation, 88.3%. A chest roentgenogram showed overt extensive consolidation in the right lobe, a finding consistent with the presence of pneumonia (Fig. 2). He underwent emergency intubation and transferred to a medical intensive care unit. Thick purulent secretions were suctioned from his airway. Synchronized intermittent mandatory ventilation

(SIMV) was initiated with a fraction of inspired oxygen of 0.7, and positive end-expiratory pressure of 5 cm H_2O , but the patient was oxygenating poorly and became increasingly agitated. His arterial blood gas levels while receiving mechanical ventilation were as follows: pH 7.379; PCO_2 , 60 mm Hg; and PO_2 , 92 mm Hg and oxygen saturation, 96%. To control his agitation and minimize the peak inspiratory pressures, the patient was sedated with midazolam and lorazepam in the form of a bolus. The patient's WBC count increased to $32 \times 10^3/\mu L$, with 45% band neutrophils and 37.4 mg/dl C-reactive protein. Ceftriaxone and levofloxacin were administered intravenously, but the steroids were rapidly tapered.

His tracheal aspirates and blood eventually grew *Streptococcal pyogenes* that was sensitive to penicillin and levofloxacin, similarly to the initial sputum culture. Testing for the susceptibility to macrolide was not performed. The patient was continued on levofloxacin and ceftriaxone. On the 10th day, he underwent a tracheostomy and thereafter was able to tolerate reduced mechanical ventilatory support. His condition improved slightly, and the arterial blood gas levels were obtained with a tidal volume of 400 mL, a pressure support level (PSV) of 5 cm H_2O , 30 % oxygen and SIMV at 8 breaths/min, and were as follows: pH, 7.335; $PaCO_2$, 54.3 mm Hg and PaO_2 , 62.9 mm Hg. A decreased consolidation was observed on the chest radiograph although the pneumonic infiltrations and areas of cavitation were still present (Fig. 3). There was a dramatic fall in the level of C-reactive protein, but no microbiological evidence of continuing

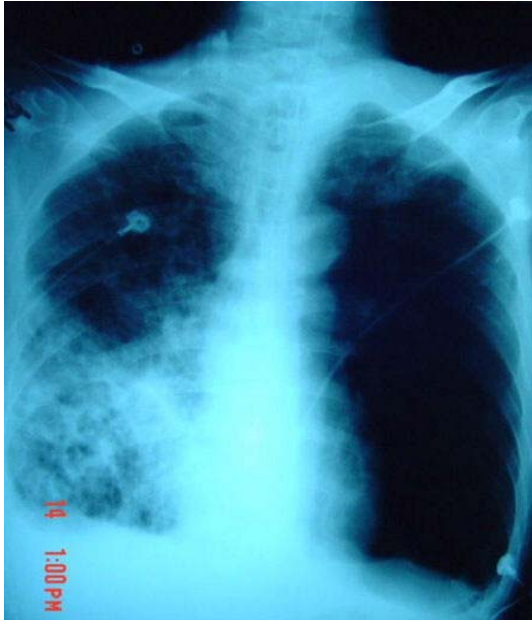

Fig. 3. The consolidation observed on the chest radiograph on the 10th day decreased, although pneumonic infiltrations and areas of cavitation were still present

septicemia. However, on Day 12, the patient suddenly lost consciousness and a hemodynamic collapse, which culminated in pulseless bradycardia, ventricular fibrillation and death.

DISCUSSION

Streptococcus pyogenes is an ubiquitous microorganism that is properly classified as a Lancefield Group A β -haemolytic streptococcus (GAS). Its common associations include acute pharyngitis, impetigo (pyoderma) and the nonsuppurative sequelae, acute rheumatic fever and acute glomerulonephritis. In addition, it is responsible for serious invasive illnesses, e.g., necrotizing fasciitis and streptococcal toxic shock syndrome

(TSS).

The features of GAS pneumonia were well characterized in the preantibiotic era, when it represented a common cause of community-acquired pneumonia²⁻³. An active bacterial core surveillance from 1997 to 1999 reported an overall incidence of invasive GAS of 3.5 per 100,000 population, with 11% presenting as pneumonia⁴. Although GAS pneumonia is rare compared with the common causes of community-acquired pneumonia, such as *Streptococcus pneumoniae*, its frequency of occurrence is similar to that of other well-recognized causes of severe community-acquired pneumonia, such as *Staphylococcus aureus* or *Klebsiella pneumoniae*.

In the past, GAS pneumonia was particularly associated with outbreaks in closed populations, such as military recruits⁵ and nursing home residents⁶. More recently, small outbreaks of invasive streptococcal infections, including GAS pneumonia, have also been described within families⁷⁻⁹. These results emphasize the importance of the transmission of GAS in institutional settings.

In older adults, diabetes mellitus, cardiac disease, cancer and corticosteroid use are associated with an invasive GAS infection. The association with diabetes, cancer and corticosteroids again suggests that immune dysfunction is important in the development of this disease¹⁰. GAS pneumonia usually occurs as a secondary pneumonia following other respiratory infections, including influenza, pertussis, varicella and measles, and in patients with COPD. However, in our case, pneumonic infiltration was overlooked on the initial chest radiography, and there-

fore, an inadequate initial treatment might have resulted in the rapid clinical deterioration.

Streptococcal pneumonia infrequently follows streptococcal pharyngitis. In one large series of 95 patients, one third of the patients reported a sore throat, and positive cultures were seen in only 17% of the 51 patients with pharyngitis. Our patient had no other clinical manifestations of a streptococcal infection, such as pharyngitis or a skin infection.

The clinical presentation of streptococcal pneumonia is similar to that of pneumococcal pneumonia, with the rapid onset of dyspnea and fever, with a predominant symptom of chest pain, and a high rate of pleural effusion and empyema²⁵; other complications included bacteremia, shock, necrotizing pneumonia, pulmonary cavitation, osteomyelitis and metastatic abscesses¹¹. Isolation of the organism from blood or pleural fluid cultures is diagnostic in an appropriate clinical setting. Blood cultures are frequently negative in GAS pneumonia⁵.

Penicillin remains the treatment of choice for both invasive and non-invasive infections¹². Severe invasive infections, such as overwhelming sepsis, necrotizing fasciitis or myositis, where a large number of bacteria are found, may reduce the efficacy of penicillin. Clindamycin should be considered in such a situation. Although penicillin should be administered, as a clinical improvements have been observed, with levofloxacin also having been reported to be sensitive to *Streptococcus pyogenes*, our patient was continued on levofloxacin and ceftriaxone.

The rapid progression from diagnosis to death was a particularly striking feature¹³. The case

fatality rate accounts 30 to 60% of the mortality found in bacteremic GAS pneumonia¹⁴⁻¹⁵.

Streptococcus pyogenes could be a causative microorganism of severe and possibly of fulminating community-acquired pneumonia. The medical history, clinical symptoms and radiological signs should be taken into account to evoke the diagnosis and for the early initiation of antibiotic therapy.

REFERENCES

1. Lim HY, Cho YJ, Song CW, Kim YR, Choi JH, Yoo JH et al. A Case of Pneumonia Complicated with Empyema Caused by *Streptococcus pyogenes*. Journal of the Korean Society for Chemotherapy 1995;13:183-87
2. Keefer CS, Rantz LA, Rammelkamp CH. Hemolytic streptococcal pneumonia and empyema: a study of 55 cases with special reference to treatment. Ann Intern Med 1941; 14:1533-50.
3. Parker MT. Necropsy studies of the bacterial complications of influenza. J Infect 1(suppl 2) 1979: 9-16.
4. Active Bacterial Core Surveillance (ABCs) Report, Emerging Infections Program Network. Group A *Streptococcus*, 1997-99. Available at: <http://www.cdc.gov/ncidod/dbmd/abcs>. Accessed January 2001
5. Basiliere JL, Bistrong HW, Spence WF. Streptococcal pneumonia: recent outbreaks in military recruit populations. American Journal of Medicine 1968;44:580 - 9.
6. Centers for Disease Control: Nursing home outbreaks of invasive group A streptococcal

- infections—Illinois, Kansas, North Carolina, and Texas. *Morbidity & Mortality Weekly Report* 1990;33:577 - 9.
7. Schwartz B, Elliott JA, Butler JC, Simon PA, Jameson BL, Welch GE, et al. Clusters of invasive group A streptococcal infections in family, hospital, and nursing home settings. *Clin Infect Dis* 1992;15:277 - 84.
 8. A household cluster of fulminant group A streptococcal pneumonia associated with toxic shock syndrome—Quebec, Canada. *Commun Dis Rep* 1996;22:41-3.
 9. Gamba M-A, Martinelli M, Schaad HJ, Strueli RA, DiPersio J, Matter L, et al. Familial transmission of a serious disease producing group A streptococcus clone: case reports and review. *Clin Infect Dis* 1997; 24:1118 - 21.
 10. Stephanie H. Factor, Orin S. Levine, Benjamin Schwartz, Lee H. Harrison, Monica M. Farley, Allison McGeer, et al. Invasive group A streptococcal disease: risk factors for adults *Emerg Infect Dis* 2003;9: 970-7.
 11. M. Barnham, N. Weightman, A. Anderson, F. Pagan, S. Chapman Review of 17 cases of pneumonia caused by *Streptococcus pyogenes* *Eur J Clin Microbiol Infect Dis.* 1999; 18:506-9.
 12. Holm SE. Invasive Group A Streptococcal infections. *N Eng J Med* 1996;8:590-1.
 13. Matthew P. Muller, Donald E. Low, Karen A. Green, Andrew E. Simor, Mark Loeb, Daniel Gregson, Allison McGeer, and the Ontario Group A Streptococcal Study Clinical and Epidemiologic Features of Group A Streptococcal Pneumonia in Ontario, Canada *Arch Intern Med* 2003;163:467-72.
 14. Kalima P, Riordan T. Necrotizing pneumonia associated with group A streptococcal bacteremia. *Eur J Clin Microbiol Infect Dis* 1998;17:296-8.
 15. Clementsen P, Milman N. Bilateral pulmonary abscesses caused by *Streptococcus pyogenes*: diagnostic importance of fiberoptic bronchoscopy. *Scand J Infect Dis* 1994;26: 755-7.
-