

**Abstract**

**Skin Paddle Salvage in Atypical Fibula Osteocutaneous Free Flap  
with Peroneal Flow through Vascular Anastomosis**

**Min Soo Kim, M.D., Daei Hyun Lew, M.D., Won Jai Lee, M.D., Kwan Chul Tark, M.D.**

*Department of Plastic & Reconstructive Surgery, Yonsei University College of Medicine, Seoul, Korea*

The vascularity of a skin island in fibula osteocutaneous free flap often depends on musculocutaneous perforators that find their origin in the proximal peroneal artery. But a potential drawback has been reported on the unreliability of the skin paddle. The perforating vessels to the skin paddle of the fibula osteocutaneous free flap were rarely derived from a common tibio-fibula trunk, an anterior tibial artery and a posterior tibial artery. Previous studies have emphasized total loss of the overlying skin paddle, if the expected perforating vessels are not present. We report here on our experience that the skin paddle of the fibula osteocutaneous free flap was vascularized not by a peroneal artery but a direct branch of the posterior tibial artery. There were no intraseptal nor intramuscular pedicles in the posterior crural septum which connected to the overlying skin island. Therefore, we performed microsurgical anastomoses between distal peroneal vessels of the fibula and the perforating branches of the posterior tibial vessels of the skin paddle. The anastomosed skin paddle was salvaged with a peroneal flow through vascular anastomosis and was transferred to the bone and intraoral soft tissue defects with the fibula graft. The patient had no evidence of vascular compromise in the postoperative period and showed good healing of the intraoral skin flap.

---

**Key Words:** Fibula osteocutaneous free flap, Skin paddle, Flow through.

1975 Taylor

가

가

가

가

가

60

(T<sub>4</sub>N<sub>0</sub>M<sub>0</sub>, Stage IV)

(skin paddle)

(septocuta-  
neous), (musculocutaneous)  
(musculoseptocutaneous)  
가  
(reliability)

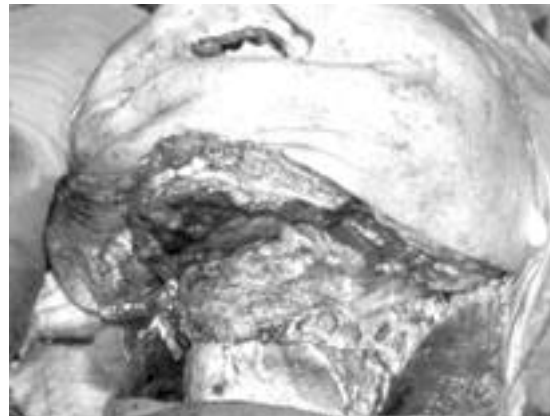.1-3

가

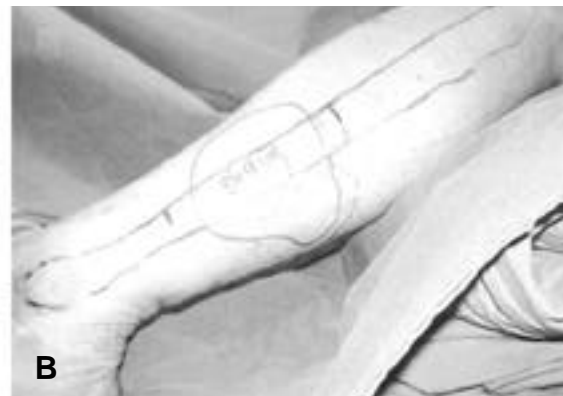
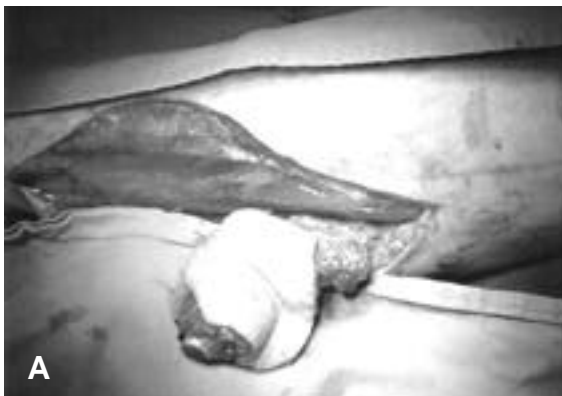가

가

가



**Fig. 1.** Note that the defect extends throughout the mandible bodies and includes considerable intra-oral soft tissue loss.



**Fig. 2.** (A) Preoperative design of fibula osteocutaneous free flap (B) After elevation of fibula osteocutaneous free

4 × 6 cm                      6 cm  
 (Fig. 1).                      가

(osteoseptocuta  
 neous)

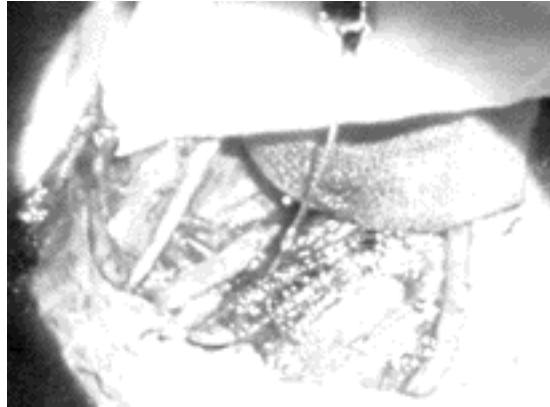1/3                      8 × 9 cm  
 (Fig. 2).                      (Doppler)

가

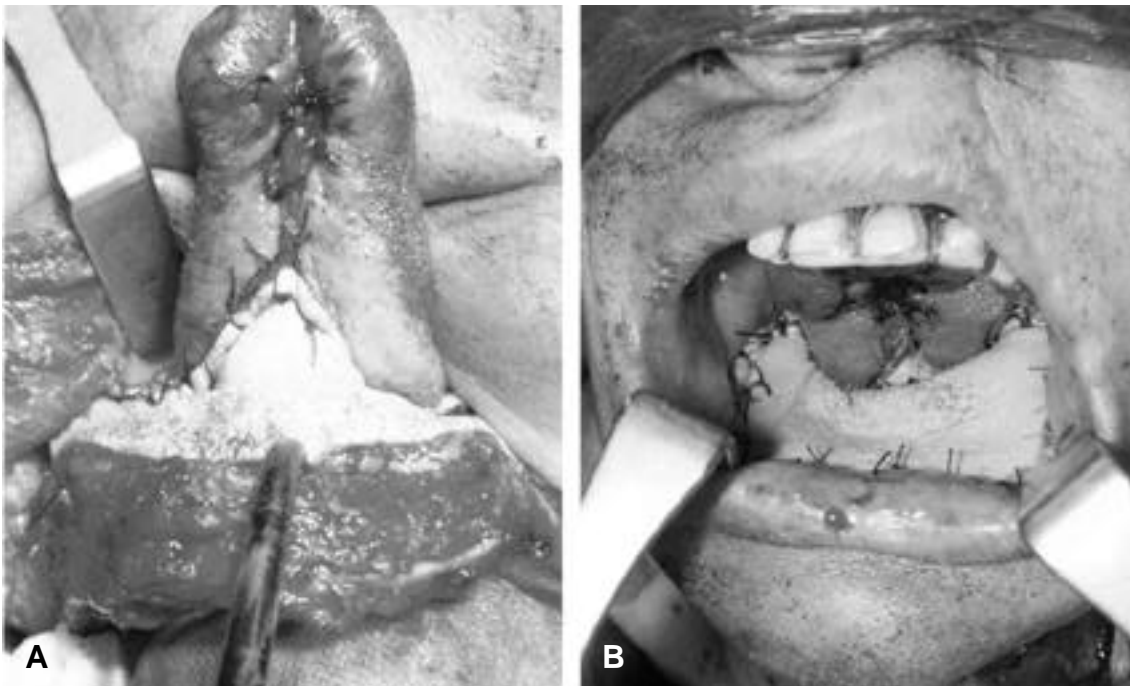
가                      (posterior  
 crural septum)                      가

가                      (soleus)                      (flexor hallu-  
 cis longus muscle)

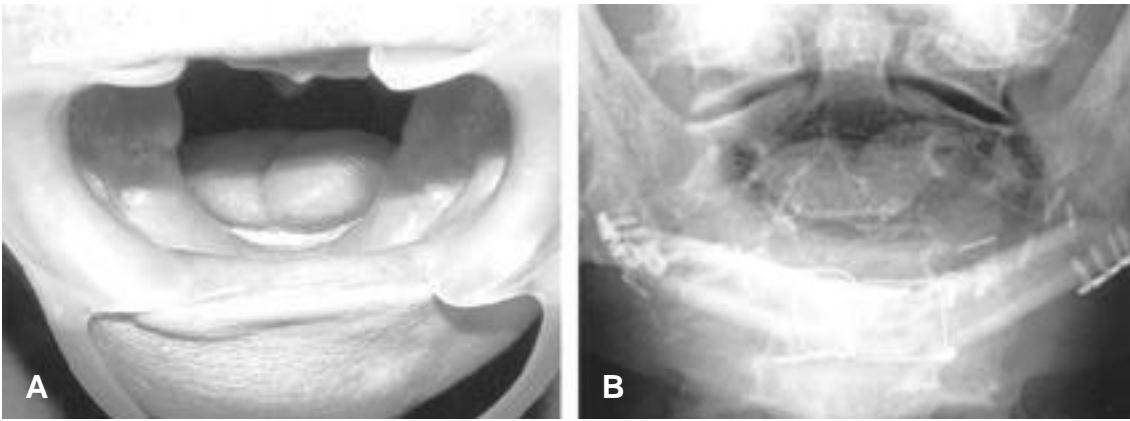
가



**Fig. 3.** A separate microsurgical anastomosis was done between the peroneal artery of the fibula graft and a branch of the posterior tibial artery of the skin paddle.



**Fig. 4.** (A) Note that an inset of the elevated flap was done to the defects in the mouth floor. (B) Separate microanastomosed skin flap showed no vascular compromise.



**Fig. 5.** (A) Appearance of the skin paddle of the fibula osteoseptocutaneous flap inside the oral cavity 3 months after reconstruction. (B) X-ray view 3 months after reconstruction.

(peroneal artery) 가

(oscillating saw) (Fig. 3). 가

가 가<sup>5,6</sup>

1/3 가

(Fig. 4). 가 20%

5, (reliability) 가 (soleus muscle)

(flexor hallucis longus muscle)

(Fig. 5).<sup>2,5</sup>

가 Wei<sup>1</sup>

(posterior crural septum)

25 cm 20 25 cm 10 14 cm

가

가

(peroneal artery)

(posterior tibial artery), (anterior tibial artery),

or tibial artery), (common tibial-peroneal trunk) (popliteal artery)

가<sup>2</sup>

artery)

Flow (CDF)

Yoshimura <sup>7</sup> 80 227  
 (90.4%)  
 (5.7%), (3.5%),  
 (0.4%)

0.3 mm ~ 1.5 mm (  
 0.6±0.2 mm)  
 0.5 mm ~ 2.8 mm (  
 1.2±0.4 mm) 가  
 5.4±1.5 cm 가

1995 Weber <sup>3</sup>  
 (common tibioperoneal trunk)  
 (external carotid artery) Y  
 가

(Doppler)  
 angiography, MRA (magnetic  
 resonance angiography) Color Doppler

가  
 가  
 가

**REFERENCES**

- 1) Fu-Chan Wei, Chee-Seng Seah: *Fibula Osteosep-  
 tocutaneous flap for reconstruction of composite  
 mandibular defect. Plast Reconstr Surg. 93: 294-  
 304, 1994.*
- 2) David A. Hidalgo: *Fibula free flap mandible recon-  
 struction. Microsurgery. 15:138-244, 1994.*
- 3) Moroe Beppu, Douglas P. Hanel: *The osteocuta-  
 neous fibula flap: An anatomic study. Journal of  
 Reconstr. Microsurgery. Vol. 8, No 3:215-223,1992.*
- 4) Robert A. Weber, William C. Pederson: *Skin pad-  
 dle salvage in the fibula osteocutaneous free flap  
 with secondary skin paddle vascular anastomosis.  
 Journal of Reconstr. Microsurgery. Vol. 11, No  
 4:239-244,1995.*
- 5) Mark A. Schusterman: *The osteocutaneous free  
 fibula flap : Is skin paddle reliable? Plast Reconstr  
 Surg. 90:787-793, 1992.*
- 6) Henry A.H. Winters: *Reliability of the proximal  
 skin paddle of the osteocutaneous free fibula flap :  
 A prospective clinical study. Plast Reconstr Surg.  
 103:846-849, 1999.*
- 7) Mitsuo Yoshimura, Takao Shimada: *The vascula-  
 ture of the peroneal tissue transfer. Plast Reconstr  
 Surg. 85:917-921, 1990.*
- 8) Peter Kessler et al.: *The role of angiography in the  
 lower extremity using free vascularized fibular  
 transplants for mandibular reconstruction. Journal  
 of Cranio-Maxillofacial Surgery. 29:332-336, 2001.*