

## Ultrasonographic Measurements in Comparison with the Rectal Palpation and Echotexture of Reproductive Organs of Buffaloes (*Bubalus bubalis*) during Different Stages of the Estrous Cycle

M. Honparkhe\*, V. K. Gandotra and A. S. Nanda

Department of Animal Reproduction, Gynaecology and Obstetrics, Punjab Agricultural University  
Ludhiana-141004, Punjab, India

**ABSTRACT :** Ultrasonographic study was undertaken to establish the echogenecity and size of reproductive organs of 18 cycling buffaloes of different parities and compared with the sizes measured by palpation per rectum at estrus (day 0), met estrus (day 2), mid diestrus (day 10) and late diestrus (day 16). The overall mean size of cervix, uterine body, right horn, left horn, right ovary and left ovary measured by palpation per rectum were  $2.70 \pm 0.43$ ,  $2.36 \pm 0.36$ ,  $2.17 \pm 0.37$ ,  $2.12 \pm 0.38$ ,  $2.63 \pm 0.41$  and  $2.72 \pm 0.37$  cm, respectively. The corresponding ultrasonographic observations were  $2.10 \pm 0.40$ ,  $1.85 \pm 0.30$ ,  $1.73 \pm 0.36$ ,  $1.64 \pm 0.37$ ,  $2.16 \pm 0.36$  and  $2.29 \pm 0.38$  cm respectively. Variations in the size of genitalia due to stages of estrous cycle were non-significant. The size of genitalia measured by palpation per rectum was significantly higher ( $p < 0.05$ ) than by ultrasonography. However, there was linear positive correlation ( $r = +0.87$ ) in the measurements by the two techniques. The ultrasonographic characteristics of tubular genitalia revealed different echogenic gray shades around the nonechogenic (black) central area of lumen depending upon the stage of cycle. The ovarian stroma appeared as hyperechoic (white) area with nonechogenic (black) follicle. The corpus luteum (CL) exhibited different echogenic texture viz. grayish black, grayish granular and grayish white at met estrus, mid diestrus and late diestrus, respectively. Therefore, ultrasonography can be effectively employed to record the exact size and echotexture of the buffalo genitalia during different stages of estrous cycle. (*Asian-Aust. J. Anim. Sci.* 2004. Vol 17, No. 7 : 919-923)

**Key Words :** Ultrasound, Estrous Cycle, Buffalo, Ovary, Per Rectal Palpation

### INTRODUCTION

Buffalo is the principal dairy animal of India. The estrous cycle length in buffalo is 18 to 22 days (Hafez, 2000), which comprised of proestrus (2 to 3 days), estrus (17 to 24 h), met estrus (2 to 3 days) and diestrus (12 to 14 days). Maximum number of buffaloes comes into estrus during winter season (Tailor et al., 1990). The intensity of estrus is reduced by the high environmental temperature and makes estrus detection more difficult (Agarwal and Tomer, 1998). Accordingly, higher conception rates have been reported in buffaloes during winter than in summer (Takkar et al., 1979; Tailor et al., 1990). Normal size and texture of genitalia is essential for optimal reproductive performance of the animal. Changes therein due to various physiological or pathological conditions may affect the functional status. Pathological lesions such as congenital abnormalities, tumors, cysts and inflammatory conditions alter the shape and performance of genitalia (Sane et al., 1964), the exact knowledge of which is very essential for undertaking corrective measures to optimize the reproductive performance. Conventionally, changes in the bovine genitalia during different stages of estrous cycle are monitored by trans rectal palpation (Roberts, 1971; Settergren, 1980), which however, is not accurate at all the

times (Ott et al., 1986; Pathiraja et al., 1986; Ribadu et al., 1994; Hanzen et al., 2000). Contrarily, ultrasonography is more accurate and reliable technique for diagnosing various ovarian structures than per rectal palpation (Ribadu et al., 1994; Hanzen et al., 2000). The device allows the exact evaluation of the reproductive tract, which could not be ascertained even by the most skilled palpators (Reeves et al., 1984). The technique has wide scope for the research as well as field application as it contributed to recent advances in understanding of follicular dynamics (Baruselli et al., 1997; Manik et al., 1998), embryo production (Kitiyant et al., 1995) and fetal development (Pawsche et al., 1994) in buffaloes. Application of ultrasonography has dramatically influenced our understanding of reproduction and its clinical management in different farm animals (Palmer and Driancourt, 1980; Pierson and Ginther, 1984, 1987, 1988; Kahn and Leidl, 1986; Makek et al., 1996; Battocchio et al., 1999; Douthwaite and Dobson, 2000; Hanzen et al., 2000) but very limited information is available on the same in buffaloes. Therefore, the present study was undertaken to determine the correlation between measurements of the buffalo reproductive tract by ultrasonography and per rectal palpation and to establish the echogenic characteristics of uterine and ovarian structures.

### MATERIALS AND METHODS

The study was conducted on eighteen normal cycling

\* Corresponding Author: Mrigank Honparkhe. Tel: +91-161-2400917, Fax: +91-161-2400945, E-mail: hmrigank@yahoo.co.in  
Received September 25, 2003; Accepted March 4, 2004

**Table 1.** The size (mean±SEM; cm) of reproductive organs of buffalo at different stages of estrous cycle

| Organs<br>(n=18) | Estrus<br>(Day 0) |           | Met estrus<br>(Day 2) |           | Mid diestrus<br>(Day 10) |           | Late diestrus<br>(Day 16) |           |
|------------------|-------------------|-----------|-----------------------|-----------|--------------------------|-----------|---------------------------|-----------|
|                  | P/R               | U/S       | P/R                   | U/S       | P/R                      | U/S       | P/R                       | U/S       |
| Cervix           | 3.00±0.41*        | 2.25±0.29 | 2.80±0.34*            | 2.26±0.39 | 2.52±0.39                | 1.99±0.40 | 2.50±0.37*                | 1.89±0.35 |
| Body of uterus   | 2.58±0.45*        | 1.98±0.28 | 2.36±0.33*            | 1.90±0.31 | 2.31±0.24                | 1.81±0.25 | 2.19±0.24                 | 1.70±0.28 |
| Right horn       | 2.44±0.52*        | 1.98±0.43 | 2.14±0.22             | 1.73±0.28 | 2.08±0.25*               | 1.66±0.23 | 2.03±0.26*                | 1.55±0.31 |
| Left horn        | 2.31±0.41*        | 1.87±0.37 | 2.25±0.42             | 1.74±0.39 | 1.97±0.26*               | 1.51±0.28 | 1.95±0.23                 | 1.41±0.16 |
| Right ovary      | 2.52±0.35*        | 2.05±0.27 | 2.58±0.42*            | 2.14±0.37 | 2.81±0.45*               | 2.36±0.37 | 2.58±0.34*                | 2.09±0.31 |
| Left ovary       | 2.67±0.37         | 2.29±0.46 | 2.72±0.34             | 2.28±0.27 | 2.83±0.33*               | 2.33±0.38 | 2.67±0.41*                | 2.25±0.36 |

P/R=per rectal, U/S=ultrasonographic. \* Values significantly ( $p<0.05$ ) higher than corresponding ultrasonographic values.

buffaloes of different parities maintained at Dairy Farm, Department of Animal Breeding and Genetics, Punjab Agricultural University, Ludhiana, India. Estrus detection was carried out by parading a vasectomized bull. The size of genitalia was measured through per rectal palpation followed by ultrasonography at estrus (day 0), met estrus (day 2), mid diestrus (day 10) and late diestrus (day 16) by the same operator. The echogenicity of genitalia was also recorded by ultrasonography.

#### Rectal palpation of genitalia

The genitalia were palpated per rectally as described by Settergren (1980). The cervix, body of uterus, right and left uterine horns were palpated per rectally to know their diameters. The length of each ovary and presence of any structures, viz. follicle, corpus luteum (CL), follicular or luteal cyst, adhesions etc. were recorded. The measurements were recorded in centimetres at fixed points as mentioned below:

| Part of the genitalia | Measurement site             |
|-----------------------|------------------------------|
| Cervix                | Middle                       |
| Body of uterus        | Just anterior to internal os |
| Uterine horns         | At the level of bifurcation  |
| Ovaries               | Anterior to posterior pole   |

#### Ultrasonography

Ultrasonographic examination of genitalia was performed with a B-mode ultrasound scanner (Pie medical, Scanner 200) equipped with inbuilt interchangeable 5/7.5 MHz linear-array rectal transducer. The animals were properly restrained manually to avoid the image distortions. The fecal material was removed from the rectum before introducing the transducer. A coupling medium, K.Y. gel was applied over the transducer to obtain better contact with rectal wall. The transducer was placed over the cervix, body of uterus right and left uterine horns transversely to obtain the cross sectional image of the lumen. The ultrasonic measurements were done at the positions similar to those in per rectal examination. The measurements were taken using the inbuilt electronic callipers after freezing the image. Each ovary was scanned in several planes by moving the transducer along its surface to identify various ovarian

**Table 2.** Correlation coefficient values (r) between the size of the reproductive organs irrespective of stage of estrous cycle measured by palpation per rectum and ultrasonography

| Organs                                | Correlation coefficient (r) |
|---------------------------------------|-----------------------------|
| Cervix (n=72)                         | +0.88                       |
| Body of uterus (n=72)                 | +0.66                       |
| Uterine horns (n=144; right and left) | +0.81                       |
| Ovaries (n=144; right and left)       | +0.87                       |
| Overall correlation (n=432)           | +0.87                       |

structures. Representative images were printed with a thermal printer (Sony; Video Graphic UP-890MD).

#### Statistical analysis

The data obtained by per rectal and ultrasonographic examinations were analyzed statistically by student's t-test with 95% level of significance ( $p<0.05$ ) and by direct method of finding out correlation coefficient (Singh et al., 1991; Gupta, 2000).

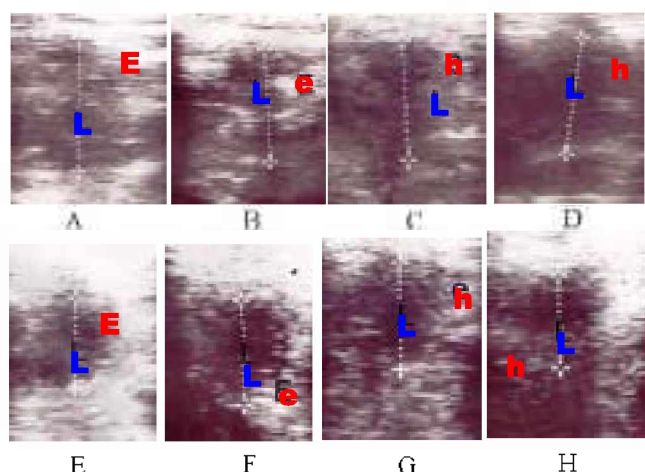
## RESULTS

#### Size of genitalia

The measurements of buffalo genitalia at four different stages of the estrous cycle are shown in Table 1. The overall mean sizes (n=72) of the cervix, body of uterus, right horn, left horn, right ovary and left ovary irrespective of the stage of the estrous cycle and parity were 2.70±0.43, 2.36±0.36, 2.17±0.37, 2.12±0.58, 2.63±0.41 and 2.72±0.37 cm by palpation per rectum. The corresponding ultrasonic values were 2.10±0.40, 1.85±0.30, 1.73±0.36, 1.64±0.37, 2.16±0.36 and 2.29±0.38 cm, respectively. There was non-significant variation in the size of reproductive organs measured both the techniques with respect to stage of estrous cycle. The correlation coefficient values between the size of the reproductive organs measured by palpation per rectum and ultrasonography are shown in Table 2. There was linear positive correlation ( $r=+0.87$ ) between measurements by the two techniques.

#### Ultrasonographic characteristics of genitalia

Ultrasonographic characteristics of cervix and uterus of buffalo during different stages of estrous cycle are shown in



**Figure 1.** Ultrasonographic images of cervix and uterus (A to H). A and E- showing heterogeneous gray shades (E) reflecting edema of wall around nonechogenic (black) central area of lumen (L) on the day of estrus, B and F- showing reduced heterogeneous gray shades (e) of wall indicating reduction in edema during met estrus, C, D and G, H- showing homogeneous gray shades (h) of wall around lumen indicating no edema of wall during mid and late diestrus.

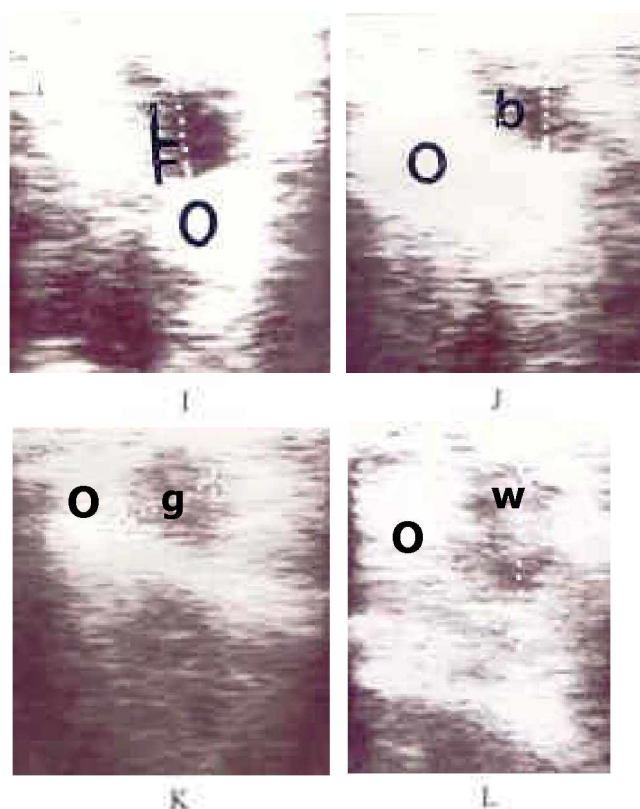
Figure 1 (A to H). Ultrasonographically, the tubular genitalia of buffaloes at estrus appeared as heterogeneous gray shades reflecting development of edema around the nonechogenic (black) central area representing the lumen. During met estrus heterogeneous gray shades were reduced indicating reduction in edema. The image was homogeneous gray without edematous development during mid and late diestrus.

The ovarian stroma appeared as uniformly hyperechoic area throughout the estrous cycle in all the buffaloes, however, structures like follicle and CL altered the echotexture. The follicle appeared as a dark nonechogenic (black) structure surrounded by hyperechoic border of ovarian stroma (Figure 2I). The ultrasonic image of CL on day 2 was poorly defined irregular and grayish black structure (Figure 2J). The mid-cyclic CL (day 10) was well-defined, granular, grayish, echogenic structure with a demarcation line visible between it and ovarian stroma (Figure 2K). On day 16, the CL was grayish white and its demarcation with ovarian stroma was faint due to slight difference in echogenicity between the tissues (Figure 2L).

## DISCUSSION

### Size of genitalia

The observations on the size of genitalia, measured by palpation per rectum or by ultrasonography were in close agreement with the findings of Luktuke and Rao (1962), Bhalla et al. (1964), Dobson and Kamonpatana (1986) on slaughterhouse genitalia. The per rectal measurements were significantly higher ( $p < 0.05$ ) than the ultrasonographic



**Figure 2.** Ultrasonographic images of ovarian structures (I-L). I- showing nonechogenic (black) follicle (F) within hyperechoic (white) ovarian stroma (o), J- showing CL on day 2 as grayish black structure (b) within ovarian stroma, K- depicting grayish granular area (g) as mid-cyclic CL and L- indicating grayish white structure (w) as regressing CL.

values. However, there was a linear positive correlation ( $r=0.87$ ) in the measurements by the two techniques. The tubular genitalia were largest at estrus than in other stages, however these size variations were statistically non-significant (Table 1). The size of the tubular genitalia varied during different stages of the estrous cycle has also been reported in cattle (Zemjanis, 1970). The increased size at estrus might be due to increased vascular development and edema as a result of high estradiol concentration (Garverick et al., 1971; Roberts, 1971). The size of ovaries did not vary significantly during different stages of estrous cycle as measured by both palpation per rectum and ultrasonography (Table 1). The observed sizes of the ovaries measured by palpation per rectum or by ultrasonography agreed with the findings of Sane et al. (1965), Dobson and Kamonpatana (1986), Parkale and Hukeri (1989) in slaughterhouse genitalia of buffaloes. Non-significant variations in the size of left and right ovaries were in confirmation with observation of Parkale and Hukeri (1989). Minor variations observed in the size of the ovaries might be due to presence of different structures i.e. follicle or CL during different stages of estrous cycle (Roberts, 1971; Agarwal and Tomer, 1998).

### Ultrasonography of genitalia

The ultrasonographic characteristics of tubular genitalia during different stages of estrous cycle were similar to those observed in cow uterus by Pierson and Ginther (1987). The echotexture of the follicle and CL during different stages of estrous cycle was similar as observed by Pierson and Ginther (1984, 1988), Pieterse et al. (1990) and Ribadu et al. (1994) in cattle. Rectal palpation is a convenient and economic method in spite of the fact that it over measures the size of the reproductive organs. Contrarily, ultrasonography records exact size and echotexture of the genitalia, which, helps in better perception of the changes occurring during the estrous cycle and thus has a wider scope for diagnostic and research purposes in buffaloes.

### REFERENCES

- Agarwal, S. K. and O. S. Tomer. 1998. Reproductive Techniques in Buffalo. Bytes and Bytes, Barielly, India. pp. 6-24.
- Baruselli, P. S., R. G. Mucciolo, J. A. Visintin, W. G. Viana, R. P. Arruda, E. H. Madureira and J. R. Oliveira Molero Filho. 1997. Ovarian follicular dynamics during estrous cycle in buffalo (*Bubalus bubalis*). *Theriogenology* 47:1531-1547.
- Battocchio, M., G. Gabai, A. Mollo, M. C. Veronesi, F. Soldano, G. Bono and F. Cairolì. 1999. Agreement between ultrasonographic classification of the corpus luteum and plasma progesterone concentration in dairy cows. *Theriogenology* 51:1059-1069.
- Bhalla, R. C., D. P. S. Sengar and G. C. Jain. 1964. Biometry of genital tract of buffalo cows. *Indian J. Vet. Sci.* 41:327-331.
- Dobson, H. and M. Kamonpatana. 1986. A review of female cattle reproduction with special reference to a comparison between buffaloes, cows and Zebu. *J. Reprod. Fertil.* 77:1-36.
- Douthwaite, R. and H. Dobson. 2000. Comparison of different methods of diagnosis of cystic ovarian disease in cattle and an assessment of its treatment with a progesterone releasing intravaginal device. *Vet. Rec.* 147:355-357.
- Garverick, H. A., R. E. Erb and G. D. Niswinder. 1971. Reproductive steroids in the bovine. III. Changes during the estrous cycle. *J. Anim. Sci.* 32:946-956.
- Gupta, S. P. 2000. Statistical methods. Sultan chand and sons, New Delhi, India.
- Hafez, E. S. E. and B. Hafez. 2000. Reproduction in farm animals. Lippincott Williams and Wilkins, Baltimore, USA. pp. 158-171.
- Hanzen, C. H., M. Pieterse, O. Scenczi and M. Drost. 2000. Relative accuracy of the identification of ovarian structures in the cow by ultrasonography and palpation per rectum. *The Vet. J.* 159:161-170.
- Kahn, W. and W. Leidl. 1986. Diagnosis of ovarian function in the cow by sonography. *Tierärztliche Umschau* 41:3-12.
- Kitiyanant, Y., C. Tocharus, M. Areekijseree and K. Pavasuthipaisit. 1995. Swamp buffalo oocytes from transvaginal ultrasound guided aspiration fertilized and co-cultured *in vitro* with bovine oviductal epithelial cells. *Theriogenology* 43:250.
- Luknuk, S. N. and S. P. Rao. 1962. Studies on biometry of the reproductive tract of the buffalo-cow. *Indian J. Vet. Sci.* 32:106-111.
- Makek, Z., M. Herak, M. Cergoli, G. I. Barac and D. Rudan. 1996. A comparison of rectal palpation and ultrasonography for the evaluation of superovulatory response in beef heifers. *Acta. Vet. Hung.* 44:467-476.
- Manik, R. S., S. K. Singla, P. Palta and M. L. Madan. 1998. Real time ultrasound evaluation of changes in follicular populations during estrous cycle in buffalo. *Indian J. Anim. Sci.* 68:1157-1159.
- Ott, R. S., K. N. Bretzlaff and J. E. Hixon. 1986. Comparison of palpable corpora lutea with serum progesterone concentrations in cows. *J. Am. Vet. Med. Assoc.* 188:1417-1419.
- Palmer, E. and M. A. Driscourt. 1980. Use of ultrasonic echography in equine gynaecology. *Theriogenology* 13:203-216.
- Parkale, D. D. and V. B. Hukeri. 1989. Study of biometry of buffalo (*Bos bubalis*) ovaries. *Indian J. Anim. Reprod.* 10:17-19.
- Pathiraja, N., E. O. Oyedipe, A. A. Vohjr and P. M. Dawuda. 1986. Accuracy of rectal palpation in the diagnosis of corpora lutea in Zebu cows. *Br. Vet. J.* 142:467.
- Pawsche, C. H., K. B. C. Appa Rao and S. M. Totey. 1994. Ultrasonographic imaging to monitor early pregnancy and embryonic development in buffaloes (*Bubalus bubalis*). *Theriogenology* 41:697-709.
- Pierson, R. A. and O. J. Ginther. 1984. Ultrasonography of the bovine ovary. *Theriogenology* 21:495-504.
- Pierson, R. A. and O. J. Ginther. 1987. Ultrasonographic appearance of the bovine uterus during the estrous cycle. *J. Am. Vet. Med. Assoc.* 190:995-1001.
- Pierson, R. A. and O. J. Ginther. 1988. Ultrasonic imaging of the ovaries and uterus in cattle. *Theriogenology* 29:21-37.
- Pieterse, M. C., M. A. M. Taverne, Th. A. M. Kruip and A. H. Willemse. 1990. Detection of corpora lutea and follicles in cows: A comparison of transvaginal ultrasonography and rectal palpation. *Vet. Rec.* 126:552-554.
- Reeves, J. J., N. W. Rantanen and M. Hauser. 1984. Transrectal real time ultrasound scanning of the cow reproductive tract. *Theriogenology* 21:485-494.
- Ribadu, A. Y., W. R. Ward and H. Dobson. 1994. Comparative evaluation of ovarian structures in cattle by palpation per rectum, ultrasonography and plasma progesterone concentration. *Vet. Rec.* 135:452-457.
- Roberts, S. J. 1971. Veterinary Obstetrics and Genital Diseases. Edwards Bros, Inc. Ann. Arbor., Mich. pp. 343-390.
- Sane, C. R., A. S. Kaikini, B. R. Deshpande, G. S. Koranne and V. G. Desai. 1964. Study of biometry of genitalia of the Murrah buffalo cows (*Bos bubalis*). *Indian Vet. J.* 41:653-663.
- Sane, C. R., A. S. Kaikini, B. R. Deshpande, G. S. Koranne and V. G. Desai. 1965. Study of biometry of genitalia of Jaffri buffalo cows (*Bos bubalis*). *Indian Vet. J.* 42:591-596.
- Settergren, I. 1980. Physical examination of the bovine female reproductive system. In: Current therapy in theriogenology. Morrow D.A., (Ed. W. B. Saunders) Company, Philadelphia.
- Singh, S., M. L. Bansal, T. P. Singh and R. Kumar. 1991. Statistical method for research workers. Kalyani publishers,

- Ludhiana, India.
- Tailor, S. P., L. S. Jain, H. K. Gupta, J. S. Bhatia and B. K. Tiwari. 1990. Oestrus and conception rates in buffaloes under village conditions. *Indian J. Anim. Sci.* 60:956-957.
- Takkar, O. P., F. S. Chauhan, M. S. Tiwana and M. Singh. 1979. Breeding behaviour of buffalo cows. *Indian Vet. J.* 56:168-172.
- Zemjanis, R. 1970. *Diagnostic and Therapeutic Techniques in Animal Reproduction*. Williams and Wilkins, Baltimore, USA. pp. 15-20.