

## 개에서 Haemodialysate Solcoseryl®이 전층피부창상의 제2기 유합 치유에 미치는 영향

권영삼 · 장광호\*

경북대학교 수의과대학  
(게재승인: 2003년 11월 20일)

## The Effects of the haemodialysate Solcoseryl® on second-intention full-thickness skin wound healing in dogs

Young-sam Kwon and Kwang-ho Jang\*

College of Veterinary Medicine, Kyungpook National University, Daegu 702-701, Korea  
(Accepted: November 20, 2003)

**Abstract :** The purpose of this study was to investigate the effects of a protein-free, standardized dialysate/ultrafiltrate (HD) derivatives from calf blood (Solcoseryl®) for second-intention full-thickness skin wound healing in dogs. Three 2×2 cm area-matched full-thickness skin wounds were created bilaterally on the dorsolateral aspect of the trunk of nine dogs. In each dog, two wounds were treated with HD, *Centella asiatica* extract (Centrasol®) and normal saline, respectively. For six weeks, the wounds were evaluated grossly for contraction, epithelialization and healing and were examined histopathologically. In the first week of the wound healing period, HD stimulated wound contraction and healing more significantly than centasol and normal saline ( $p < 0.05$ ). Neutrophils were more increased in the HD-treated wounds than those in centasol or normal saline treated wounds. In the second week, HD stimulated epithelialization more significantly than centasol or normal saline ( $p < 0.05$ ), and neovascularization and granulation more increased in the HD-treated wounds than those in centasol and normal saline treated wounds. In conclusion, HD was the most effective on early wound contraction, epithelialization and healings among three experimental drugs in full-thickness skin wound.

**Key words :** Solcoseryl®, wound healing, wound contraction, epithelialization, dog

### Introduction

Wound healing types are primary, secondary and tertiary (delayed primary) intention healings. Traumatic wounds in dogs, because many full-thickness skin wounds are large, have extensive tissue damage, and are contaminated or infected, they often induce second-intention healing and which allowed to heal completely progressive formation of granulation tissue followed by contraction and epithelialization [25]. Moreover, dehiscence often occurs after primary closure. But, wound healing by second-intention healing is prone to complication

such as ugly scars [26]. Therefore, there is a great demand in dog practice for products such as bacitracin-neomycin-polymyxin compound, trypsin-balsam of Peru castar oil and *Centella asiatica* that speed up second-intention wound healing [25].

Solcoseryl®, referred to as haemodialysate(HD) in this article, improves second-intention wound healing in several species by interacting with different steps of the wound healing cascade. HD stimulates the healing of ulcers and burns in humans [12, 16, 21, 22] and also the healing of experimental wounds in other species, such as rats [9, 10] and guinea pigs [13]. In vitro HD

This research was supported by Kyungpook National University Research Fund, 2001.

\*Corresponding author: Kwang-ho Jang

College of Veterinary Medicine, Kyungpook National University, Daegu 702-701, Korea  
[Tel: 82-53-950-5965, Fax: 82-53-950-5955, E-mail: khojang@knu.ac.kr]

stimulates cell metabolism, growth and migration [5, 7, 8, 18, 19, 20, 23, 24]. Centasol is commonly used in dermatitis [3, 6], infectious trauma, burn or surgical trauma [1] and ulcer [2].

Although HD has been shown to improve the healing of wounds in horses [17] and human [23], and estimated its effect on traumatic wounds deeper than full-thickness skin wounds, it is not commonly used in veterinary practice except in horses and ponies [26]. Moreover, little is known about its mechanism of action.

For that reason, the purpose of this study was to investigate the effects of HD on second-intention full-thickness skin wound healing in dogs. To evaluate the effects of HD compared with those of other drugs, changes in wound contraction, epithelialization and wound healing were grossly observed and wounds were examined histopathologically.

## Materials and Methods

### Dogs and experimental set-up

Nine healthy dogs (mean body weight  $3.50 \pm 0.5$  kg, over 1 year old) were used. Six dogs were assigned for gross observation and three were for histopathological observation. Under general anesthesia with xylazine (1mg/kg, IM, Rompun<sup>®</sup>, Bayer Korea Co.) and ketamine (5 mg/kg, IM, Ketamine<sup>®</sup>, Yuhan Co. Korea), three 2×2 cm area-matched full-thickness skin wounds were created bilaterally on the dorsolateral aspects of the trunk of each dog. In each dog, HD, centasol and normal saline were treated with two wounds, respectively. HD (Solcoseryl<sup>®</sup>, Solco Balse Ltd, Birsfelden, Switzerland) is a protein-free, low molecular weight fraction derived from haemolysed calf blood by dialysis/ultrafiltration. Centasol (Seong-Jin Co Ltd, Korea) is the ointment extracted from the swamp plant *Centella asiatica*. Wound managements were the same for all wounds. All were covered with non-pressure bandages for the first 2 weeks. The bandages were changed everyday for the first week and every other day for the second week, and at the same time, a thin (1 mm) layer of HD, centasol and normal saline were applied to the HD-, centasol- and normal saline-treated wounds. Thereafter, the wounds were left uncovered, and a thin (1 mm) layer of experimental drugs was applied every third day for the third week and every seventh day from the fourth week to the sixth week. Throughout the study, all dogs had a good appetite, nor did they show

signs of discomfort.

### Gross wound evaluation

The wounds were evaluated over a six-week period. For this study the results were given only for the first 4 weeks because all wounds were healed after this period. On day 0, 7, 14, 21, 28 and 35 after wound creating, all wounds were constructed by OHP film (PC 82-T1<sup>®</sup>, SKC) and were analyzed with a Color Image Analyzer (Q520 Meta Morph, Cambridge Instrument, UK).

Wound contraction, epithelialization, and healing were calculated. They were expressed as a percentage of the wound area on Day  $W_0$ , defined as the day of the maximal wound size. Also the area of newly formed epithelium was calculated. Percentage of wound contraction, epithelialization and healing were calculated using the following formulae;

$$\text{Percentage of wound contraction} = 100 \times [(W_0 - W_i) / W_0]$$

$$\text{Percentage of epithelialization} = 100 \times [(W_i - U_i) / W_0]$$

$$\text{Percentage of wound healing} = 100 \times [W_0 - U_i] / W_0]$$

$W_0$  : Wound area on day 0 after wound creating

$W_i$  : Wound area on day  $i$  after wound creating

$U_i$  : Non-epithelialization area on day  $i$  after wound creating

Wound healing was considered complete when epithelialization was 100% and area of granulation tissue was zero.

### Histopathological wound evaluation

On day 1, 4, 7, 14, 21, 28 and 35 after wound creating, surgical biopsies were taken under general anesthesia from HD-, centasol-, and normal saline-treated wound of one dog. Tissue sample was excised from the wound margin to the center of the wound over the full-thickness skin. The biopsies were fixed with 10% phosphate-buffered formalin (pH 7.2) and embedded in paraffin wax and 5  $\mu$ m sections were cut. They were stained with haematoxylin and eosin (H&E), to observe degree of neutrophil and fibroblast infiltration, neovascularization and epithelialization.

### Statistical analysis

Data were expressed as mean standard deviation (SD) and the statistical significance of the difference

among HD, centasol and normal saline were analysed using the student *t*-test. P values less than 0.05 were considered statistically significant.

## Results

### Gross aspects of wound contraction

Significant differences of wound contraction, epithelialization, and healing were not observed in all treated-wounds on day 1 and day 4 after wound creating. Differences were first detected on day 7 after wound creating

Wound contraction was stimulated in HD-treated wounds ( $21.35 \pm 1.15\%$ ) compared with those in centasol-treated ( $15.28 \pm 2.95\%$ ) and normal saline-treated wounds ( $12.36 \pm 4.67\%$ ) on day 7 after wound creating. Significant differences, however, wasn't observed in all wounds thereafter (Fig. 1).

Epithelialization was stimulated in HD-treated wounds ( $28.25 \pm 4.55\%$ ) compared with those in centasol-treated ( $17.15 \pm 7.85\%$ ) and normal saline-treated wounds

( $13.97 \pm 5.25\%$ ) on day 14 after wound creating. Though decreased in HD-treated wounds thereafter, mean percentages of epithelialization increased in other groups from day 14 to day 21 (Fig. 2).

Wound healing was more stimulated in HD-treated wounds ( $51.25 \pm 3.06\%$ ) compared with those in centasol-treated ( $38.25 \pm 5.78$ ) and normal saline-treated wounds ( $28.38 \pm 6.67\%$ ). Significant differences, however, didn't observed in all wounds thereafter (Fig 3).

### Histological aspects of wound contraction

The number of infiltrated neutrophils increased in all wounds. But, they were much more infiltrated in HD-treated wounds compared with those in other groups. Although their numbers decreased slowly on and after day 7 after wound creating in all experimental wounds, decrease rate in HD-treated wounds was more rapid than those in other wounds (Fig. 4).

HD stimulates neovascularization and fibroblast infiltration. Degree of neovascularization and number of infiltrated fibroblasts in HD-treated wounds more

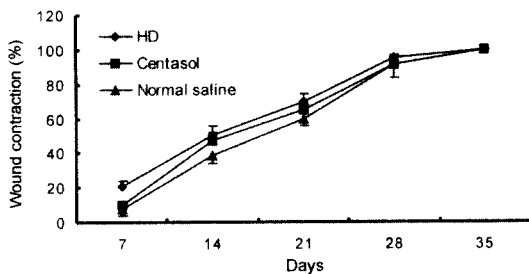


Fig. 1. Mean percentage of wound contraction in each experimental group.

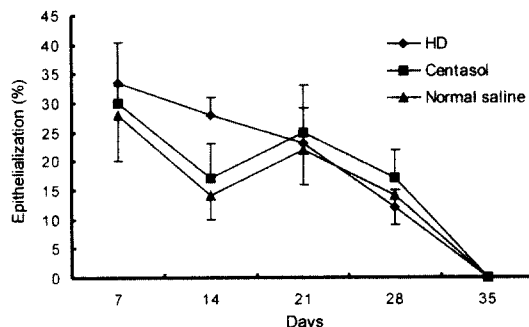


Fig. 2. Mean percentage of epithelialization in each treatment group.

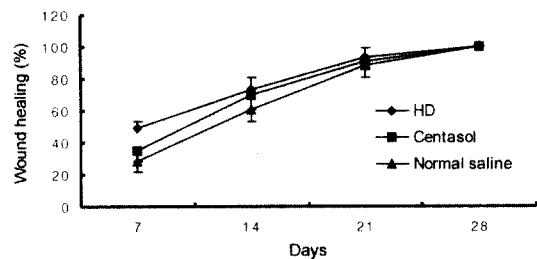


Fig. 3. Mean percentage of wound healing in each treatment group.

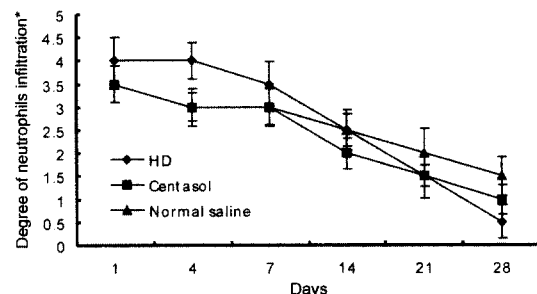
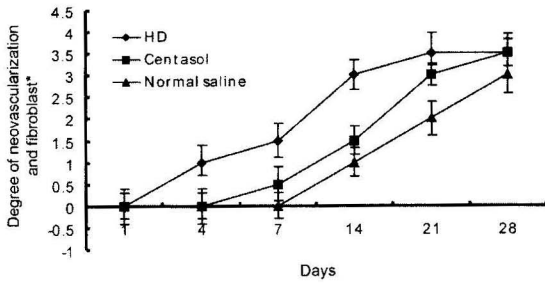


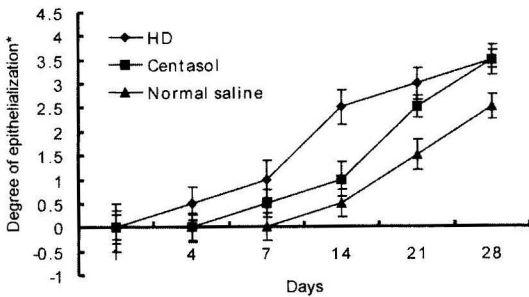
Fig. 4. Mean percentage of neutrophils infiltration in each treatment group.

\*Degree of neutrophil infiltration: 0, None; 0~1, None to slight; 1~2, Slight; 2~3, Moderate; 3~4, Severe.



**Fig. 5.** Mean degree of neovascularization and fibroblast distribution in each treatment group.

\*Degree of neovascularization and fibroblast: 0, None; 0~1, None to little; 1~2, Little; 2~3, Middle.



**Fig. 6.** Mean degree of epithelialization in each treatment group.

\*Degree of epithelialization: 0, None; 0~1, None to low; 1~2, Low; 2~3, Middle; 3~4, High.

increased than those in other wounds on day 7 after wound creating (Fig. 5).

Though significantly stimulated in HD-treated wounds compared with that in other wounds on day 14 after wound creating, epithelialization in HD-treated wounds was delayed thereafter (Fig. 6). Any significant differences, however, were not observed in all wounds.

## Discussion

Wound healing is divided into four stages: Inflammation, debridement, repair, and maturation. The wound healing process is continuous with overlapping of the various stages [25]. Various inflammatory cells such as polymorphonuclear (PMN) cells and macrophages infiltrate the injured area in inflammation and debridement stage. Fibroblast proliferation and capillary infiltration that manifest themselves in the form of granulation tissue in the wound, and major function of this tissue

is wound contraction in repair stage. And then, epithelial proliferation and migration provide the hairless thin covering over the granulation tissue. During maturation, collagen fibers remodeled.

HD had been shown to stimulate wound healing in many species [9, 10, 12, 13, 16, 21, 22]. Centasol has been used in skin wound healing and its effects have been known to promote fibroblast proliferation and to stimulate collagen synthesis.

In this study, a significant effect of HD treatment on the pattern of wound healing existed in the HD-treated wounds, and consisted of stimulated healing during the first two weeks. Significant differences, however, were not observed thereafter. This effect can be explained grossly by stimulation of wound contraction, epithelialization and healing, histologically by inflammation (neutrophils), granulation tissue formation (fibroblast, neovascularization), and epithelial tissue remodeling. These processes are essential in the early phase of wound healing.

In the first week of wound healing period in this study, HD more stimulated wound contraction and healing, and more increased neutrophils than Centasol and normal saline. In horse, the increased inflammatory response enhanced the demarcation of nonviable tissue and subsequently the migration and proliferation of fibroblasts was stimulated, including their differentiation into myofibroblasts, thus promoting wound contraction. In this study, similar results were showed [26].

Though initial inflammatory response is essential for adequate wound healing, chronic inflammation with persistent involvement of PMN cells may lead to cell destruction and an altered composition of the extracellular matrix, with the subsequent failure of epithelialization [4, 11]. But, in this study, all wounds were healed completely on day 35 after wound creating, and this may due to too small wound size. The stimulation of the inflammatory response by HD treatment was pronounced in the metatarsal wounds of the horses and resulted in faster healing of the treated wounds [14, 26]. This study that investigated the effects of HD on full-thickness skin wound healing showed the similar results with previous reports [14]. In the second weeks of wound healing period in this study, HD not only stimulated wound contraction and healing, but increased the number of the neutrophils more than centasol and normal saline. In other studies, the increased proliferation and migration of fibroblasts were seen *in vivo* and *in vitro*. In this study, HD stimulated mitotic activity of fibroblasts on

day 14 after wound creating. Although such activity initially enhances healing, when wound has to be filled up by granulation tissue, it will ultimately lead to an excess of granulation tissue and therefore to inhibition of epithelial mitosis. This study showed that wound contraction, epithelialization and healing decreased in later phase.

In conclusion, HD has more effects on wound contraction, epithelialization and wound healing than centasol in early wound phase. So, HD can be used in the early phase of second-intention wound healing in the dogs, but is contraindicated in the later phases when epithelialization become predominant. In addition, to find out pathogenetic pathways and cytokines and growth factors involved to elucidate the exact wound healing mechanisms more studying and research need to be done.

## References

1. **Brinkhaus, B., Lindner, M., Schuppan, D. and Hahn, E. G.** Chemical, pharmacological and clinical profile of the East Asian medical plant *Centella asiatica*. *Phytomedicine*. 2000, **7**, 427-428.
2. **Chatterjee, T. K., Chakraborty, A., Pathak, M. and Sengupta, G. C.** Effects of plant extract *Centella asiatica* on cold restraint stress ulcer in rats. *Indian J. Exp. Biol.* 1992, **30**, 889-891.
3. **Chen, Y. J., Dai, Y. S., Chen, B. F., Chang, A., Chen, H. C., Lin, Y. C., Chang, K. H., Lai, Y. L., Chung, C. H. and Lai, Y. J.** The effect of tetrandrine and extracts of *Centella asiatica* on acute radiation dermatitis in rats. *Biol. Pharm. Bull.* 1999, **22**, 703-706.
4. **Schoen, F. J.** Robins pathologic basis of disease. pp. 35-92. 5th ed. Saunders, Philadelphia. 1994.
5. **Dri, P., Cramer, R., Mittenzwei, H. and Patriarca, P.** Dual effect of a protein-free hemodialysate on the oxygen uptake of phagocytosing human polymorphonuclear leucocytes. *Drug. Res.* 1989, **39**, 1565-1567.
6. **Eun, H. C. and Lee, A. Y.** Contact dermatitis due to madecassol. *Contact Dermatitis*. 1985, **13**, 310-313.
7. **Fabbro, D., Imber, R., Huggel, K. and Baschong, W.** Growth-promoting effect of a protein-free hemodialysate used in situation of hypoxia and for tissue repair as measured via stimulation of S6-kinase. *Drug Res.* 1992, **42**, 917-920.
8. **Fraefel, W., Tschannen, R. and Ellergy, A. W.** Isolation and partial characterization of a proliferation-enhancing fraction of Solcoseryl. *Excerpta Medica*. 1985, **45**, 293-311.
9. **Isler, H., Bauen, A. and Baschong, W.** Topical treatment of standardized burns with a protein-free haemodialysate. *Burns*. 1991, **17**, 93-98.
10. **Isler, H., Bauen, A., Hubler, M. and Oberholzer, M.** Morphometric assessment of wound healing in rats treated with a protein-free haemodialysate. *Burns*. **17**, 99-103.
11. **Knottþbelt, D. C.** Equine wound management: are there significant differences in healing at different sites on the body? *Vet. Dermatol.* 1997, **8**, 273-290.
12. **Knudsen, L., Solvhøj, L. and Christensen, B.** The use of a haemodialysate in the treatment of decubital ulcer: a double-blind randomized clinical study. *Curr. Ther. Res.* 1982, **32**, 498-504.
13. **Laaf, H.** Lokalbehandlung tiefer Brandwunden mit einem proteinfreien Hamodialysat im Tier-Experiment. *Vasomed.* **8**, 3-10.
14. **Liebich, H. G., Hamm, D. and Jöchle, W.** Histological evaluation of wound healing in horses treated with the protein-free hemodialysate Solcoseryl and its hexosylceramide fraction. *J. Vet. Med.* 1988, **35**, 84-95.
15. **Maquart, F. X., Bellon, G., Gillery, P., Wegrowski, Y. and Borel, J. P.** Stimulation of collagen synthesis in fibroblast cultures by a triterpene extracted from *Centella asiatica*. *Connect. Tissue Res.* 1990, **24**, 107-120.
16. **Marichy, J. and Eyraud, J.** The wound healing effect of Solcoseryl ointment in the treatment of children with burns. *Acta. Ther.* 1984, **10**, 107-117.
17. **May, S. R. and Dogo, G.** Care of the burn wound. pp. 84-89. Karger, Basal. 1983.
18. **Miltenburger, H. G., Baschong, W., Horner, V. and Marx, G.** Cooperative effects in vitro on fibroblast and keratinocyte functions related to wound healing by transforming growth factor  $\beta$  and a low molecular weight fraction from hemolyzed blood. *Drug Res.* 1994, **44**, 872-876.
19. **Niinikoski, J. and Renvall, S.** Effect of a deproteinized blood extract on experimental granulation tissue. *Acta. Scand.* 1979, **145**, 187-291.
20. **Riede, U. N., Kaden, P. and Mittermayer, C.** Action of solcoseryl on cell growth. *Med. Welt.* 1975, **26**, 122-127.
21. **Rossano, S., Weiner, M. and Haigis, E.** Clinical, blood gas, and lactate changes in the course of the treatment

- of peripheral vascular disease with a hemodialysate. *Drug Res.* 1990, **40**, 1195-1200.
22. **Rossano, S., Weiner, M. and Haigis, E.** Oxygen transport in peripheral arterial occlusive disease; effects of calf blood dialysate. *Angiology.* 1993, **44**, 471-476.
  23. **Schreier, T., Degen, E. and Baschong, W.** Fibroblast migration and proliferation during *in vitro* wound healing. *Res. Exp. Med.* 1993, **193**, 195-205.
  24. **Spessotto, P., Dri, P., Baschong, W., Mittenzwei, H. and Patriarca, P.** Effect of a protein-free dialysate from calf blood on human monocyte differentiation *in vitro*. *Drug Res.* 1993, **43**, 747-751.
  25. **Swaim, S. F. and Henderson, R. A.** Small animal wound management. pp. 1-12. 2nd ed. Lippincott/Williams and Wilkins, Baltimore. 1997.
  26. **Wilmink, J. M., Stolk, P. W. T., van Weeren, P. R. and Barneveld, A.** The effectiveness of the haemodialysate Solcoseryl<sup>®</sup> for second-intention wound healing in horses and ponies. *J. Vet. Med.* 2000, **47**, 311-320.
  27. **Wilmink, J. M., van Weeren, P. R., Stolk, P. W. T., van Mil, F. N. and Barneveld, A.** Differences in second-intention wound healing between horses and ponies: histological aspects. *Equine. Vet. J.* 1999, **31**, 61-67.