

## A human case of *Echinostoma hortense* (Trematoda: Echinostomatidae) infection diagnosed by gastroduodenal endoscopy in Korea

Chang-Min CHO<sup>1)</sup>, Won-Young TAK<sup>1)</sup>, Young-Oh KWEON<sup>1)</sup>, Sung-Kook KIM<sup>1)</sup>,  
Yong-Hwan CHOI<sup>1)</sup>, Hyun-Hee KONG<sup>2)</sup> and Dong-Il CHUNG<sup>2)\*</sup>

<sup>1)</sup>Department of Internal Medicine, <sup>2)</sup>Department of Parasitology, Kyungpook National University School of Medicine, Daegu 700-422, Korea

**Abstract:** A human *Echinostoma hortense* infection was diagnosed by gastroduodenoscopy. An 81-year-old Korean male, living in Yeongcheon-shi, Gyeongsangbuk-do and with epigastric discomfort of several days duration, was subjected to upper gastrointestinal endoscopy. He was in the habit of eating fresh water fish. Two live worms were found in the duodenal bulb area and were removed using an endoscopic forcep. Based on their morphological characteristics, the worms were identified as *E. hortense*. The patient was treated with praziquantel 10 mg/kg as a single dose. The source of the infection in this case remains unclear, but the fresh water fish consumed, including the loach, may have been the source. This is the second case of *E. hortense* infection diagnosed by endoscopy in Korea.

**Key words:** Echinostomiasis, gastrointestinal endoscopy

Members of the family Echinostomatidae are zoonotic flukes, which infect birds and mammals including humans. Human infections by the echinostomatid flukes, i.e. *Echinostoma hortense*, *E. cinetorchis*, *Echinochasmus japonicus*, and *Acanthoparyphium tyosenense*, have been reported in Korea (Seo et al., 1983; Ryang et al., 1986; Ahn and Ryang, 1986). Of the four species, *E. hortense* is the most frequently reported to be a causative fluke (Chai and Lee, 2002). Endemic foci of *E. hortense* have been previously reported in Umsong-gun, Chungchongbuk-do (We, 1987) and Chongsong-gun, Kyongsangbuk-do (Lee et al., 1988).

An 81-year-old Korean male, living in Yeongcheon-

shi, Gyeongsangbuk-do, was admitted to the outpatient's department of Internal Medicine, Kyungpook National University Hospital. The patient complained of epigastric discomfort of several days duration. No significant abnormality was detected by laboratory findings. He was in the habit of eating raw fresh water fish. Gastroduodenal endoscopy revealed two live worms in the duodenal bulb area; the mucosa of which showed mild erosion (Fig. 1). The worms were picked out with an endoscopic biopsy forcep and transported to the Department of Parasitology, Kyungpook National University School of Medicine, where they were fixed in 70% ethanol and stained with Semichon's acetocarmine. They were very slender (7.92 × 1.33 mm), and had a characteristic head crown equipped with 27 collar spines around the subterminal oral sucker (Fig. 2A and B). The

• Received 16 January 2003, accepted after revision 25 February 2003.

\*Corresponding author (e-mail: dichung@knu.ac.kr)

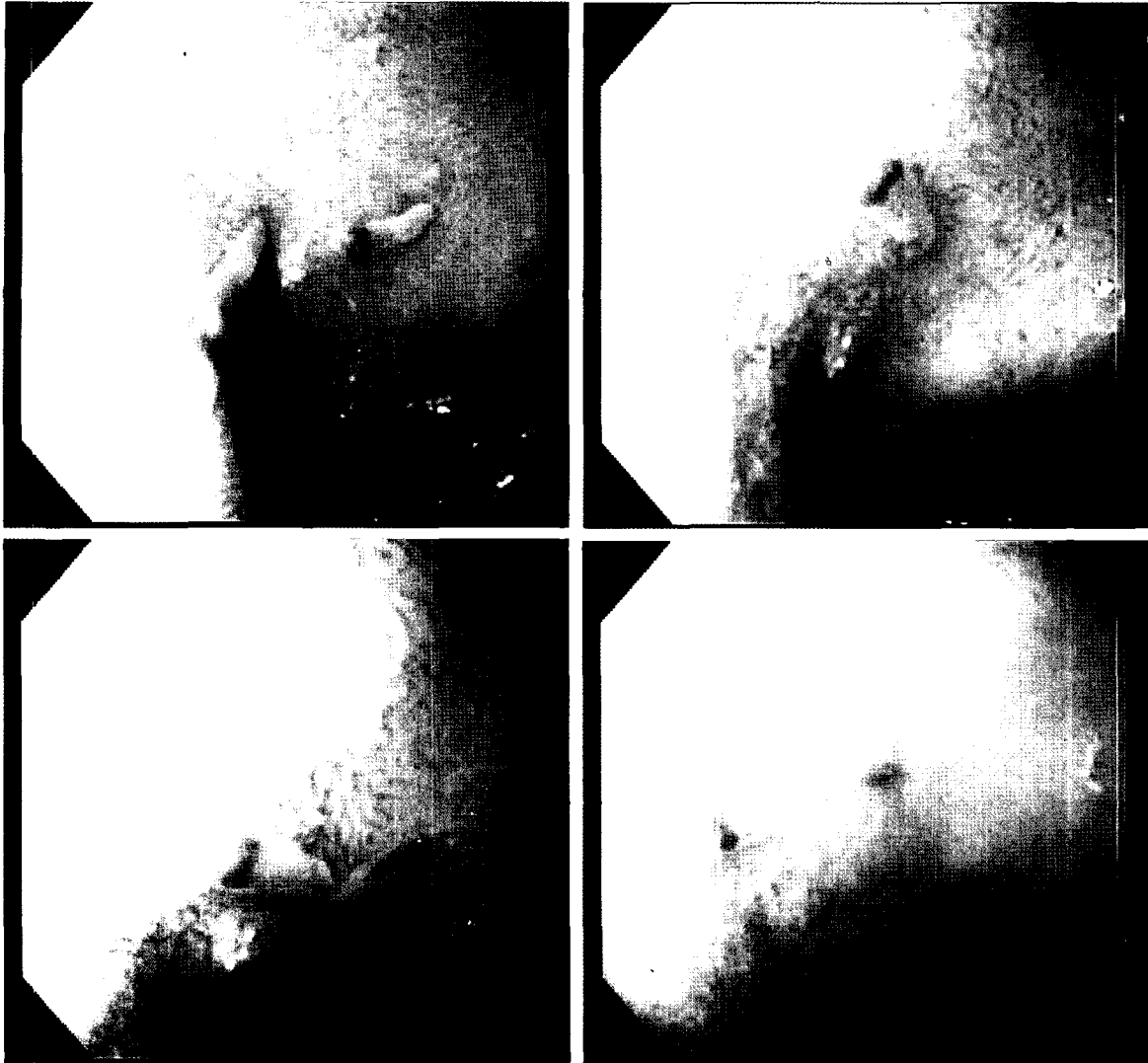


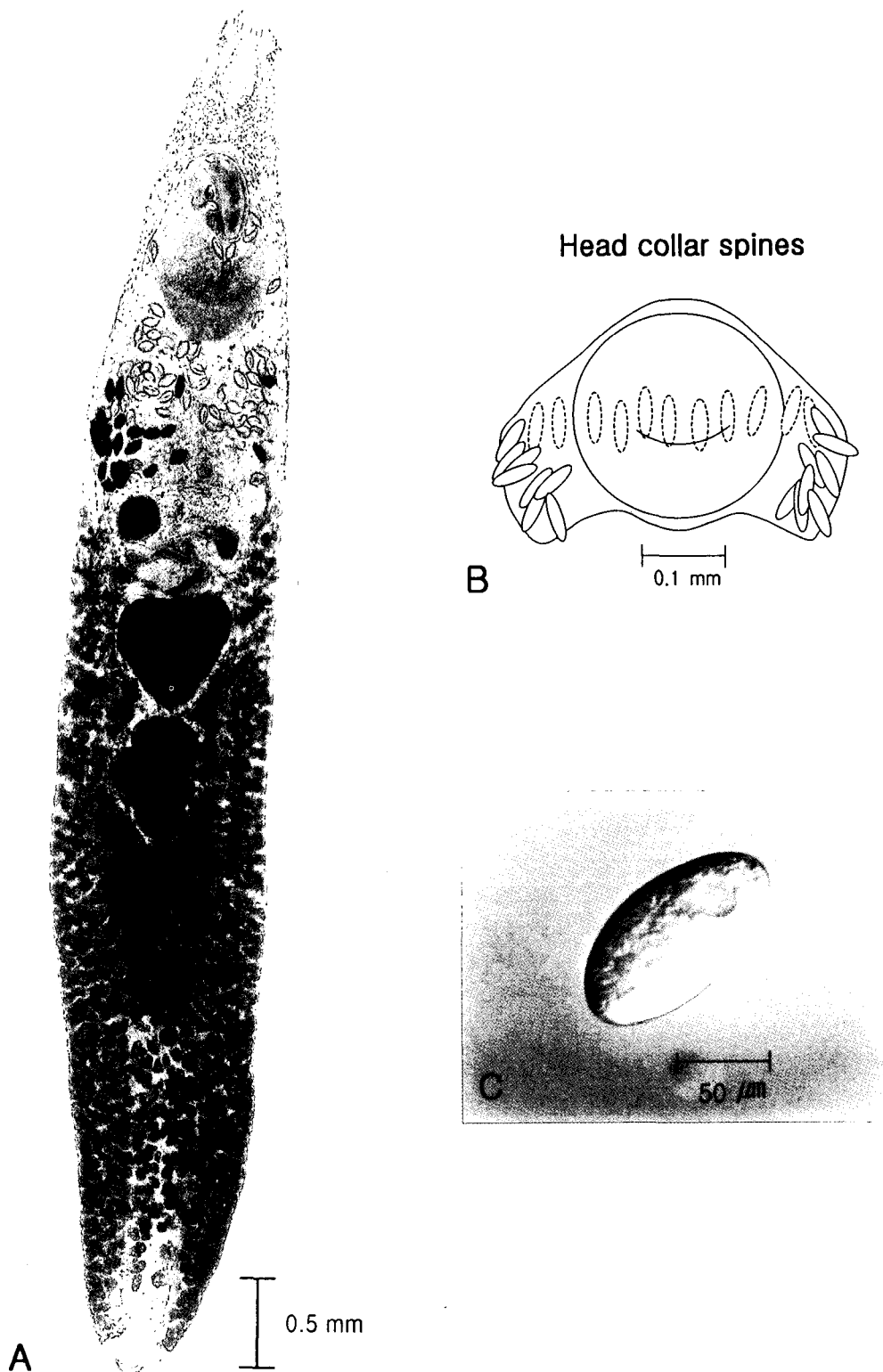
Fig. 1. Endoscopic images of two live parasitic worms in the patient's duodenal bulb.

ventral sucker ( $0.68 \times 0.77$  mm) was positioned at the anterior 1/3 of the body and was much larger than the oral sucker ( $0.25 \times 0.26$  mm). The uterus was distended and contained thin-shelled elliptical eggs. A spontaneously discharged egg ( $124.3 \times 68.6$   $\mu\text{m}$ ) had an operculum at the narrower end and a well-defined germ ball (Fig. 2C). Two testes were distinct, slightly lobulated, and located in tandem at the equatorial portion. The worms were identified as *E. hortense* by morphological characteristics and measurements.

The symptoms of echinostomiasis vary from none to abdominal pain, although a case in Korea showed duodenal ulceration (Chai et al., 1994). Because of high incidence of stomach cancer and ulcer in Korea, many senior citizens with gastrointestinal symptoms

are subjected to endoscopic examinations. *Echinostoma hortense* can be easily demonstrated by gastroduodenoscopy due to its habitat in the upper small intestine and its relatively large size. The present case is the second Korean case of *E. hortense* infection, which was diagnosed by gastroduodenoscopy (Chai et al., 1994). Four cases diagnosed by endoscopy have been reported in Japan (Hamamoto et al., 1997).

The source of the infection in this case is unclear. Many senior residents of inland areas of Gyeongsangbuk-do eat raw fresh water fish, including loaches, a known source of human infection. An epizootiological survey in the Yeongcheon area should be performed to determine the sources of human infection. The residence of this



**Fig. 2.** Ventral view of an adult *Echinostoma hortense* stained with Semichon's acetocarmine (A), drawing of the head collar spines (B), and an egg (C).

patient was Yeongcheon-shi neighboring Cheongsong-gun, which has been reported to be one of the

endemic foci of *E. hortense*. Yeongcheon-shi and Cheongsong-gun are inlands of Gyeongsangbuk-do

and contain upper reaches of the Nakdong-gang (river). The geographic characteristics of both localities coincide well with the indications of Chai and Lee (2002), namely, that *E. hortense* is distributed inland along the upper reaches of large rivers. Therefore, to confirm Yeongcheon-shi as an endemic area of *E. hortense*, an epidemiological survey of this fluke should be undertaken.

### REFERENCES

- Ahn YK, Ryang YS (1986) Experimental and epidemiological studies on the life cycle of *Echinostoma hortense* Asada, 1926 (Trematoda: Echinostomatidae). *Korean J Parasitol* **24**: 121-136.
- Chai JY, Lee SH (2002) Food-borne intestinal trematode infections in the Republic of Korea. *Parasitol Int* **51**: 129-154.
- Chai JY, Hong ST, Lee SH, Lee GC, Min YI (1994) A case of echinostomiasis with ulcerative lesions in the duodenum. *Korean J Parasitol* **32**: 201-204.
- Hamamoto T, Kawasaki H, Maejima J, Hirai K (1997) A case of *Echinostoma hortense* infection diagnosed by the upper gastrointestinal endoscopy. *Nippon Shokakibyo Gakkai Zasshi* **94**: 487-491.
- Lee SK, Chung NS, Ko IH, et al. (1988) An epidemiological survey of *Echinostoma hortense* infectin in Chongsong-gun, Kyongbuk Province. *Korean J Parasitol* **26**: 199-206.
- Ryang YS, Ahn YK, Kim WT, Shin KC, Lee KW, Kim TS (1986) Two cases of human infection by *Echinostoma cinetorchis*. *Korean J Parasitol* **24**: 71-76.
- Seo BS, Hong ST, Chai JY, Lee SH (1983) Studies on intestinal trematodes in Korea VIII. A human case of *Echinostoma hortense* infection. *Korean J Parasitol* **21**: 219-223.
- We JS (1987) Prevalence of intestinal helminthiasies in some residents at Umsong-gun, Chungchongbuk-do, and detection of metacercariae from fresh water fish. Dissertation for Master of Science (MSc) in Medicine, Seoul National University.