

## 구개의 섬유종 : 증례보고

김영재 · 장기택 · 한세현 · 김종철 · 이상훈 · 김정욱

서울대학교 치과대학 소아치과학교실 및 치학연구소

### 국문초록

섬유종은 구강 내에서 가장 흔히 발견되는 양성 연조직 종양이다. 대개 외상과 관련된 병력이 있으며 10대와 20대에서 호 발하며 외과적 절제 후 재발은 드문 것으로 보고되었다.

14세 여아가 구개에 생긴 연조직 병소의 진단과 처치를 위해 서울대학교병원 소아치과로 의뢰되었다. 병소는 지난 6개월 간 점차 크기가 증가하였으며 외상병력과 구강 내 악습관은 없는 것으로 조사되었다.

임상 검사 결과 직경 3cm의 무증상인 점막의 경상 융기가 관찰되었고, 생검(biopsy) 결과 섬유종으로 진단하였다. 외과적 제거 후 4년간 재발의 징후는 보이지 않았다. 섬유종에 대한 병리학적 고찰과 감별진단, 증례의 진단과 처치에 대해 보고하는 바이다.

**주요어** : 섬유종, 연조직 병소

### I. Introduction

The fibroma is the most common benign soft-tissue tumor found in the oral cavity. It is characteristically a dome-shaped lesion with a sessile base and a smooth surface that is usually the color of the surrounding mucosa. It may vary from firm to flaccid in texture, and most commonly occurs in sites predisposed to irritation or trauma, such as the buccal mucosa, lip, tongue, gingiva, and hard palate<sup>1)</sup>. Projecting above the surface, the tumor sometimes becomes irritated and inflated and may even show superficial ulceration. It is nearly always a well defined, slowly growing lesion that occurs infrequently in the first and second decade of life. It is generally considered to be caused by chronic irritation<sup>2)</sup>.

Histologically, the fibroma consists of bundles of interlacing collagenous fibers interspread with varying numbers of fibroblasts or fibrocytes and small blood vessels. The surface of the lesion is covered by a layer of stratified squamous epithelium, which frequently appears stretched, and shows shortening and flattening of the rete pegs. If trauma to the tissue has occurred, vasodi-

latation, edema and inflammatory cell infiltration are variably present<sup>3)</sup>.

Fibroma treatment is conservative surgical excision. Seldom does the lesion recur<sup>2)</sup>.

### II. Case history

A healthy, 14 year-old girl was referred for evaluation and management of soft mass of the palate. The patient had first detected the mass about 6 months previously, however, she had expected that it would regress spontaneously. Recently, she had begun to feel that the size of the mass was increasing and went to the family dentist.

Clinical examination revealed an asymptomatic, soft, pedunculated elevation of mucosa in the middle of the palate, measuring 3cm diameter(Fig. 1). A history of trauma or irritable habits was denied. The lesion was painless and non-blanching to palpation.

No pathologic bony change was detected on occlusal view of intraoral X-ray. Based on the clinical and X-ray findings, a decision was made to perform an excisional biopsy by electrosurgical unit under local anesthesia(Fig.

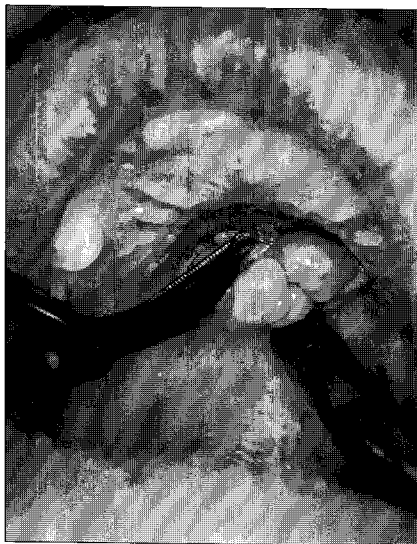

**Fig. 1.** A fibroma growing on the palate

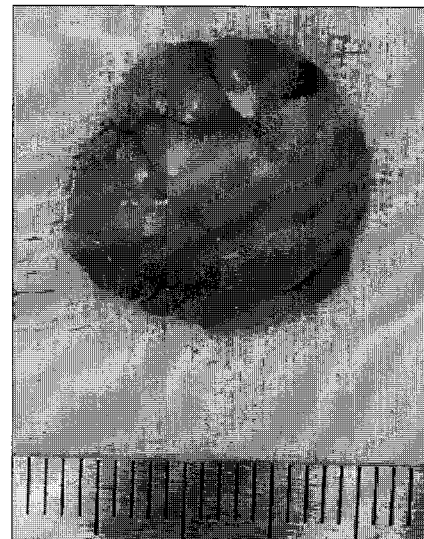2A-B). The histopathologic findings included dense collagen with areas of hyalinization and a paucity of blood vessels and the covering of the entire lesion by stratified squamous epithelium(Fig. 3).

A diagnosis of fibroma was made based on these microscopic findings. After surgery, optimal antibiotics and analgesic agents were prescribed and chlorhexidine solution gargling was directed.

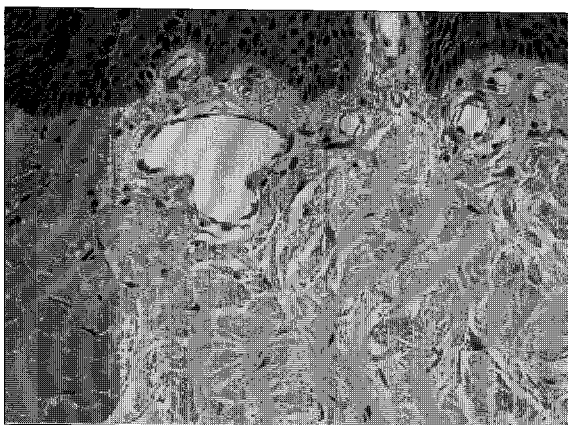
A state of good healing was evident at the follow up of 2 weeks(Fig. 4) and no recurred lesion has been detected for 4 years.



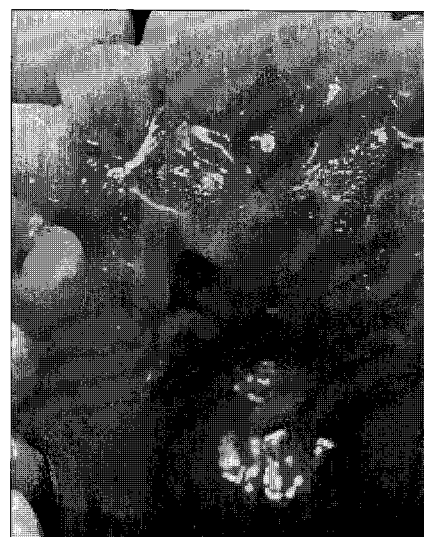**Fig. 2A.** Excisional biopsy being performed by electrocautery unit



**Fig. 2B.** Removed mass sized 3cm in diameter



**Fig. 3.** Photomicrograph demonstrating the lining of the fibroma by stratified squamous epithelium



**Fig. 4.** Two weeks following surgery

### III. Differential Diagnosis

The fibroma may be confused with benign tumors such as minor salivary gland neoplasm, neurofibroma, neurilemmoma, rhabdomyoma, leiomyoma, and giant cell fibroma<sup>4)</sup>. Giant cell fibroma is reported to be a small, firm, papular or polypoid lesion of not more than 1 cm in diameter that occurs on the gingival, tongue, buccal mucosa, and palate. These lesions are said to be characterized histologically by large, multinucleated, active fibroblasts<sup>5)</sup>. Some clinicians prefer not to classify them as separate from inflammatory or fibrous hyperplasia lesions, and they should be included in the differential diagnosis of fibroma<sup>6)</sup>.

For diagnosis however, the fibroma is ranked above any of these lesions, because of its relatively high incidence in the oral cavity.

### IV. Discussion

The fibroma is the most common non-odontogenic tumor in children and adolescents and is primarily found on gingival, buccal mucosa, lip and tongue<sup>7)</sup>. Nevertheless, fibroma on the palate, the true neoplasm of connective tissue, has seldom been reported. The palatal mass such as in this case can impose a difficult diagnostic dilemma for the clinician. Differential diagnosis of the palatal mass includes palatal abscesses, benign and malignant tumors, benign neural tumors, and traumatic or irritation fibromas. Furthermore, it could be microscopically similar to the condition known as inflammatory hyperplasia (also called traumatic fibroma), where the mass may appear clinically more obscure and indistinguishable. However in the present case, the lack of any history of trauma or irritation was the key to defining the final diagnosis as true fibroma. In few situations is the distinction between the two general processes, hyperplasia and true neoplasia, as poorly defined as it was here in the present case. Hyperplastic tissue sometimes, but not inevitably, regresses after removal of the stimulus or irritant. In this case, no such regression was found as in neoplastic tissue, and the patient reported that the lesion had been growing for several months. Although the distinction between hyperplasia and neoplasia is not clear, and although cases occur intraorally in which there is focal or diffuse proliferation of tissue obviously due to irritation which does not regress after

removal of the irritant, we had to depend on the acquired history to determine how to manage the lesion. It is commonly believed, however, that a great number of the lesions of the oral cavity diagnosed as fibromas are, in reality, simply examples of focal or localized hyperplasia, resulting from inflammation, and that the true fibroma is much rarer than is presently reported<sup>8)</sup>.

The treatment is surgical intervention whether the lesion is true neoplasm or not. We decided to perform an excisional biopsy to avoid the possibility of secondary surgery.

Ultimately, a biopsy of the palatal mass was necessary to render a definite diagnosis and determine the optimal treatment and management of the patient. Emphasis is placed on the importance of obtaining a thorough, comprehensive medical and dental history from the patient.

### V. Summary

1. The fibroma is the most common benign soft-tissue tumor found in the oral cavity. It is characteristically a dome-shaped lesion with a sessile base and a smooth surface that is usually the color of the surrounding mucosa and most commonly occurs in sites predisposed to irritation or trauma, such as the buccal mucosa, lip, tongue, gingiva, and hard palate.
2. Clinical examination revealed an asymptomatic, soft, pedunculated elevation of mucosa in the middle of the palate, measuring 3cm diameter in the present case. A history of trauma was denied. The lesion was painless and no pathologic bony change was detected. Based on the clinical and X-ray findings, a decision was made to perform an excisional biopsy by electro-surgical unit under local anesthesia.
3. A state of good healing was evident at the follow up of 2 weeks and no recurred lesion has been detected for 4 years.

### References

1. McDonald RE, Avery DR : Dentistry for the child and adolescent, 7th Ed. Mosby Inc., St. Louis, 152-153, 2000.
2. Shafer WG, Hine MK, Levy BM : A textbook of Oral Pathology, 4th Ed. W.B. Saunders Company, Philadelphia, 139-140, 1983.
3. Bhaskar SN : Synopsis of oral pathology, Mosby Inc., St. Louis, 34, 1977.

4. Wood NK, Goaz PW : Differential Diagnosis of Oral and Maxillofacial Lesions, 5th Ed. Mosby-Year Book Inc., St. Louis, 138, 1997.
5. Priddy RW : Inflammatory hyperplasias of oral mucosa, J Can Dent Assoc, 58: 311-321, 1992.
6. Weathers DR : Callihan M.D.: Giant cell fibroma, Oral Surg, 36:374-384, 1974.
7. Maaita JK : Oral tumors in children:a review, J Clin Pediatr Dent, 24(2): 134-137, 2000.

---

**Reprint requests to:**

**Ki-Taeg Jang**, D.D.S., M.S.D., Ph.D.  
Department of Pediatric Dentistry, Seoul National University Hospital,  
28 Yeongun-dong, Jongno-ku, Seoul, KOREA  
E-mail: jangkt@snu.ac.kr

**Abstract**

**FIBROMA ON THE PALATE : A CASE REPORT**

Young-Jae Kim, D.D.S., M.S., Ph.D., Ki-Taeg Jang, D.D.S., M.S., Ph.D.,  
Se-Hyun Hahn, D.D.S., M.S., Ph.D., Chong-Chul Kim, D.D.S., M.S., Ph.D.,  
Sang-Hoon Lee, D.D.S., M.S., Ph.D., Jung-Wook Kim, D.D.S., M.S., Ph.D.

*Department of Pediatric Dentistry and Dental Research Institute, College of Dentistry,  
Seoul National University, Seoul, KOREA*

The fibroma is the most common benign soft-tissue tumor found in the oral cavity and most commonly occurs in sites predisposed to irritation or trauma. Treatment is conservative surgical excision. Seldom does the lesion recur.

A 14-year old girl was referred to the Department of Pediatric Dentistry for evaluation and management of a mass on the palate. The patient's parents reported the slow growth of this soft tissue lesion over a 6-month period. A history of trauma or irritable habits was denied.

Clinical examination revealed an asymptomatic, soft, pedunculated elevation of mucosa, measuring 3cm in diameter. Excisional biopsy of the lesion supported a diagnosis of fibroma. There have been no signs of recurrence during follow up of 4 years after surgical intervention. The clinical picture, pathology and management of the case are described, and the differential diagnosis and treatment are discussed.

**Key words** : Fibroma, Soft tissue lesion