

1

= Abstract =

A Case of Tuberculous Otitis Media in Children

Eun Ah Kim, M.D., Se Chang Ham, M.D., Young Kyoun Kim, M.D.
Yong Won Park, M.D. and Yun Kyung Kang, M.D.*

Department of Pediatrics and Pathology, College of Medicine,
Inje University, Seoul Paik Hospital, Seoul, Korea*

Tuberculous otitis media is a very rare disease in extrapulmonary tuberculosis and in chronic otitis media nowadays. The characteristic signs seem to have altered from the past ones. And the suspicion index is very low that there is often a considerable delay prior to diagnosis. This might result in irreversible complications such as hearing loss, facial nerve paralysis and labyrinthitis.

It is difficult to be defined by culture, so many patients with tuberculous otitis media are subjected to have surgery without a correct etiologic diagnosis. Therefore bacteriologic study of secretion and pathologic examinations of biopsied tissue are mandatory.

We report one year and 11 months old boy with tuberculous otitis media having painful otorrhea and perforated tympanic membrane diagnosed by histologic finding and polymerase chain reaction(PCR). And we would like to emphasize the fact that tuberculous otitis media must be considered in the differential diagnosis of persistent suppurative otitis media despite appropriate antibiotic therapy considering the increasing tendency in incidence of Tuberculosis in Korea these days.

Key Words : Tuberculous otitis media, Chronic otitis media, Child

1% 1. 2) 1 11
0.04 5% 3, 4) 가 1)
5) 6), 7)

g/dL, 34%, 10,600/mm³ (40.3%, 50.6%, 6.4%, 2.6%, 0.1%), 354,000/mm³, 22 mm/hr, C 3.5 mg/dL . 가
 1 4 1 5 9 ,
 Candida albicans가

: , 1 11 ,
 :
 : 3
 , 2
 가 , methicillin-resistant *Staphylococcus aureus*가 teicoplanin 가 (Fig. 1),
 6

가 : BCG 4
 , 가 가
 : 37.5
 , 30 / , 120 / 100/50
 mmHg , 13.5 kg(75),
 96 cm(>97) .

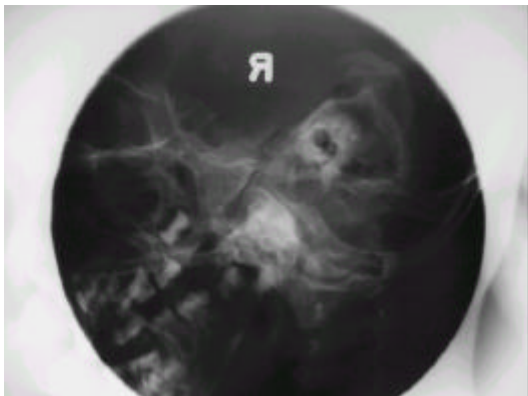

Fig. 1. Right mastoid X-ray shows relatively well preserved mastoid pneumatization, but with suspicious hazy increased density.

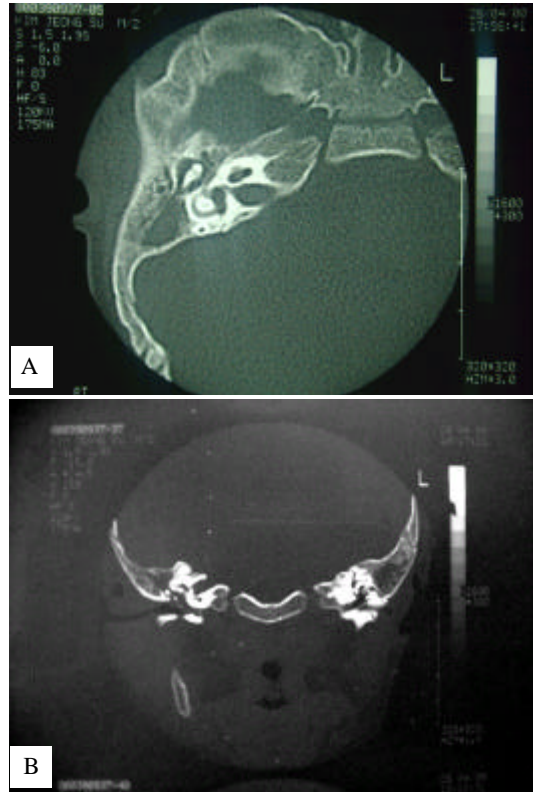


Fig. 2. Axial temporal bone CT (A) reveals soft tissue density in right ear cavity, mastoid antrum and peripheral air cells. The ossicles are intact without destruction. Coronal CT (B) also shows soft tissue density in right middle ear cavity and soft tissue thickening of superior wall of right external auditory canal.

(Fig. 2A and 2B).

jugulodigastric, internal jugular, spinal accessory, submandibular chain (Fig. 3).

가 B 5 Pseudo- monas aeruginosa가 , AFB

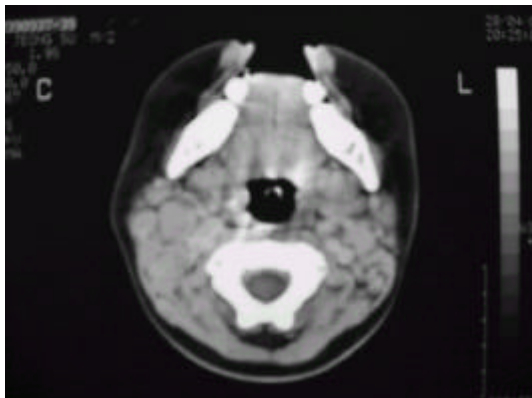


Fig. 3. Contrast-enhanced neck CT shows multiple lymph nodes with relatively homogeneous density at bilateral jugulodigastric, internal jugular, spinal accessory, and submandibular chain(suggesting reactive hyperplasia rather than tuberculous lymphadenitis).

가

(Fig. 4),

(polymerase chain reac-

tion, PCR)

18 x 18 mm Tb PCR 11 isoniazid(INH) 10 mg/kg, rifampin(RFP) 10 mg/kg pyrazinamide (PZA) 20 mg/kg 2 INH RFP 10 3

(Fig.

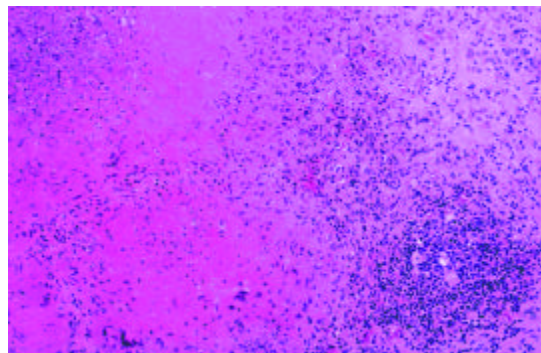


Fig. 4. Histopathology of biopsy specimen shows exuberant caseous necroses, conglomerated palisading epithelioid granulomas with Langhans' type multinucleated giant cell(H-E stain, x 200).

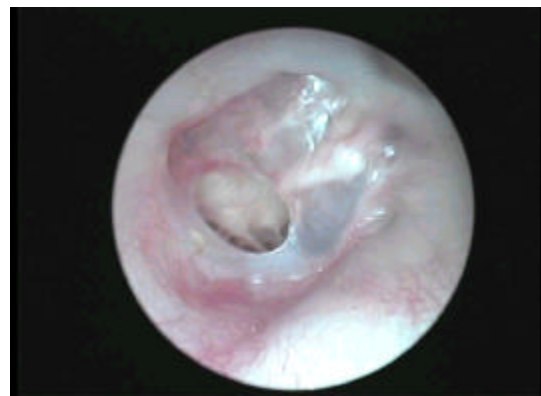

Fig. 5. Otoscopic finding shows central perforation of right tympanic membrane.

5), 9 가 , 1, 5) .
 . 10 23) ,
 가 24) .
 , AFB PZA 가 가 19, 21) ,
 2 3 INH, RFP 가 7, 19, 23, 24) .
 2 23) .
 ,
 ,
 1882 Koch 14, 15, 24) .
 BCG 7) .
 8) .
 , AIDS 가 9) , 3, 19) ,
 14, 15, 23) .
 가, 20 30 Skolnik 6) 1953
 가 가 10) .
 가 , 14, 19, 24 28) .
 0.04 5% 1, 3, 4) ,
 Kim 11) 1.5%가 , , ,
 ,
 1, 4, 12 15) .
 16 20) , ,
 28) .
 Mantoux test 94%가
 1 14) , 가
 가 14% 93%
 50%
 6, 13) 13, 14) .
 15, 23 25) .
 가 1, 24, 25) .
 CT

가 ²²⁾, CT PCR , , ,
²¹⁾, MRI ,
가 DTPA ^{29, 30)} 2 PZA
^{20, 21)} 가 INH RFP 12 18 가
^{1, 2, 19)} 가
, , .
3 가 9
가 ^{4, 6, 7, 14, 24)} 가 , PZA 2
(neomycin, gentamicin) 가 INH RFP .
¹⁵⁾ , PCR ¹⁾,
, , ,
PCR ²⁾,
, ³⁾.
가 가 .
^{1, 5, 12)} 가
, ,
¹⁵⁾ , ⁵⁾,
AFB ¹²⁾.
, , , ,
가 , ^{3, 24, 28)}.
, Wegener's granulomatosis,
eosinophilic granuloma, sarcoid
^{1, 13, 25)} 가
가
, , , ,
, , , ,
²⁰⁾ .

- 1) Lucente FE, Tobias GW, Parisier SC, Som PM. Tuberculous otitis media. *Laryngoscope* 1978;88:1107-16.
- 2) Mumtaz MA, Schwartz RH, Grundfast KM, Baumgartner RC. Tuberculosis of the middle ear and mastoid. *Pediatr Infect Dis* 1983;2:234-6.
- 3) Jeang MK, Fletcher EC. Tuberculous otitis media. *JAMA* 1983;249:2231-2.
- 4) Ramages LJ, Gertler R. Aural tuberculosis : a series of 25 patients. *J Laryngol Otol* 1985;99:1073-80.
- 5) Wallner LJ. Tuberculous otitis media. *Laryngoscope* 1953;63:1058-77.
- 6) Skolnik PR, Nadol JB Jr, Baker AS. Tuberculosis of the middle ear : review of the literature with an instructive case report. *Rev Infect Dis* 1986;8:403-10.
- 7) Yaniv E, Traub P, Conradie R. Middle ear tuberculosis-a series of 24 patients. *Int J Pediatr Otorhinolaryngol* 1986;12:59-63.
- 8) Vernick DM, Kell SB. Weekly clinicopathological exercises : case 13-1999 : a 20-year-old woman with chronic otitis media. *N Engl J Med* 1999;340:1349-54.
- 9) Al-Serhani AM. Mycobacterial infection of the head and neck : presentation and diagnosis. *Laryngoscope* 2001;111:2012-6.
- 10) The present state of tuberculosis in Korea. *Communicable Diseases Monthly Report* 2001; 12:147-53.
- 11) Kim Hyung Jong, Kim Chong Sun, Noh Kwon Taik. Tuberculous otitis media. *Korean J Otolaryngol Head Neck Surg* 1984;27:525-32.
- 12) MacAdam AM, Rubio T. Tuberculous otomastoiditis in children. *Am J Dis Child* 1977;131:152-6.
- 13) Kirsch CM, Wehner JH, Jensen WA, Kagawa FT, Campagna AC. Tuberculous otitis media. *South Med J* 1995;88:363-6.
- 14) Yaniv E. Tuberculous otitis : an underdiagnosed disease. *Am J Otolaryngol* 1987;8:356-60.
- 15) Odetoynbo O. Early diagnosis of tuberculous otitis media. *J Laryngol Otol* 1988;102:133-5
- 16) Cho Chin Kyu, Kang Jae Kyun, Chung Hong Kyung. A case of so called primary tuberculosis of the middle ear. *Korean J Otolaryngol* 1968;11:15-8.
- 17) Kim Chong Sun, Chang Sun O, Noh Kwon Taik, Paik Man Kee. Tuberculous otitis media. *Korean J Otolaryngol* 1980;23:286-9.
- 18) Lee Soo Bong, Kim Jin Tack, Lee Joon Sung, Lee Kyung Su, Lee Whang. A case of disseminated tuberculosis with tuberculous otitis media. *J Korean Pediatr Soc* 1994;37:135-40.
- 19) Park Byung Weon, Cho Woo Ryeong, Seok San Ryeol, Kim Seu Gyu, Kim Myung Gu, Kwon O Jun, et al. A clinical, radiologic study of tuberculous otitis media. *Korean J Otolaryngol* 1999;42:973-80.
- 20) Na Ae Sun, Han Ouk Sun, Kim Haeng Jae, Cho Yong Bum. A case of primary tuberculous otitis media with lateral sinus thrombosis and subperiosteal abscess. *Korean J Otolaryngol* 1999;42:1583-6.
- 21) Oh Jin Hwan, Jung Ki Joon, Kim Myung Soon, Kwon Taek sang, Yoon Byoung Moon. Three cases of tuberculous otitis media. *J Korean Radiol Soc* 1998;39:51-4.
- 22) Chang Jeong A, Rho Myung Ho, Kim Young Min, Lee Ho Seung, Choi Phil Yeob, Jung Keon Sik, Jung Keon Sik, et al. Temporal bone CT findings of tuberculous otitis media : comparison with chronic otitis media. *J Korean Radiol Soc* 1999;40:1063-9.
- 23) Plester D, Pusalkar A, Steinbach E. Middle ear tuberculosis. *J Laryngol Otol* 1980;94:1415-21.
- 24) Windle-Taylor PC, Bailey CM. Tuberculous otitis media : a series of 22 patients. *Laryngoscope* 1980;90:1039-44.
- 25) Ma KH, Tang PS, Chan KW. Aural tuberculosis. *Am J Otol* 1990;11:174-7.

- 26) Mjoen S, Grontved A, Holth V, Mair IW. Tuberculous otomastoiditis. *J Otorhinolaryngol* 1992;54:57-9.
- 27) Farrugia EJ, Raza SA, Phillipps JJ. Tuberculous otitis media - a case report. *J Laryngol Otol* 1997;111:58-9.
- 28) Bhalla RK, Jones TM, Rothburn MM, Swift AC. Tuberculous otitis media - a diagnostic dilemma. *Auris Nasus Larynx* 2001;28:241-3.
- 29) Chang AB, Grimwood K, Hutson JM, Jones CL. Renal tuberculosis in an Australian-born child. *J Paediatr Child Health* 1998;34:293-5.
- 30) Lenk S, Schroeder J. Genitourinary tuberculosis. *Curr Opin Urol* 2001;11:93-8.
-