

= Abstract =

A Case of Ecthyma Gangrenosum Associated with Liver Abscess and Renal Abscess

Ji Yeong Seo, M.D., Shin Young Kim, M.D.
Man Yong Han, M.D. and Kyu Hyung Lee, M.D.

Department of Pediatrics, College of Medicine, Pochon CHA University, Sunnam, Korea

Ecthyma gangrenosum is usually seen in immunocompromised patients, particularly in those with underlying malignant disease. Ecthyma gangrenosum is rapidly progressing skin infection characterized by edema, hemorrhage, bullae and necrosis. We experienced the case of a 13-month-old male who had Ecthyma gangrenosum associated with liver abscess and renal abscess. The patient initially presented with skin lesions of multiple well defined central necrotic black colored large erythematous bullae. The multiple liver abscess with hepatomegaly and multifocal pyelonephritis with focal renal abscess revealed by abdominal ultrasonogram and computed tomogram. In the bacterial cultures of skin, urine and liver aspiration fluid, Pseudomonas aeruginosa was grown. The patient had no immune deficiency disease. We report this case with a review of related literatures.

Key Words : Ecthyma gangrenosum, Liver abscess, Renal abscess

1)

,

*

2001 51

: , 13 ,
: 1
가 :
15
: 1 , 3

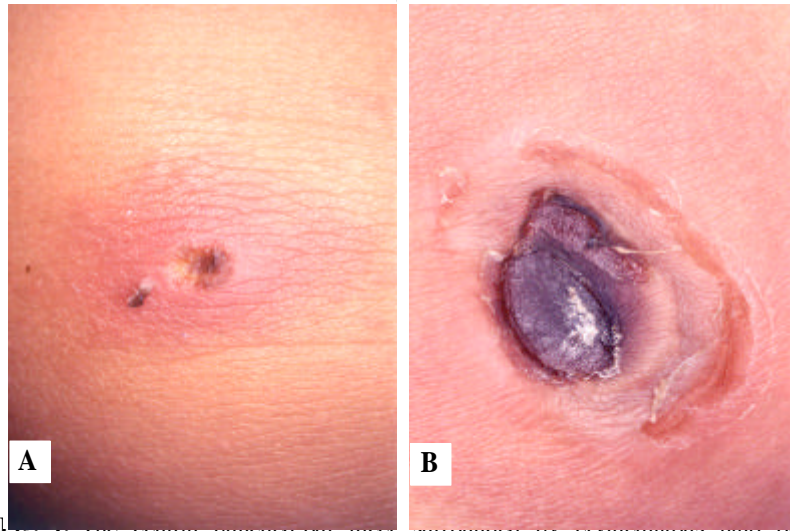


Fig. 1. The central punched-out ulcer on left knee(A), the violaceous to black necrotic eschar and surrounding erythematous induration on left thigh(B).

39 , 142
 / , 44 /
 가
 (Fig. 1).
 2 3 cm
 :
 33,300/mm³(67%, 14%,
 19%), 110 g/dL, 31.9
 %, 101,000/mm³ ,
 55 mm/hr, CRP 18.71 mm/hr 가
 . AST/ALT 31/53 U/L, Total bilirubin 0.29
 mg/dL , 5.2 g/dL,
 2.8 g/dL

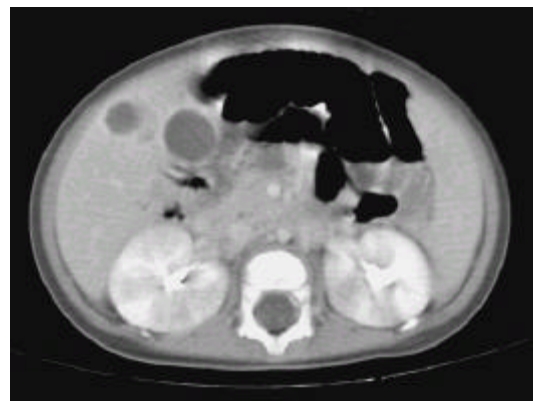


Fig. 2A. Abdominal CT showing about three focal abscess with enhancing walls in the right lobe of the liver, measuring 2.2 x 1.6 cm in segment 5 and focal small low attenuated lesion indicating renal abscess(Hospitalization day 7).

*Pseudomonas aeruginosa*가
 2 , 3
 8
*Pseudomonas aeruginosa*가

B T (CD4 45%, CD8
 29.4%, CD19 13.6%, CD56 10%)
 , IgG 675.89 mg/dL(Ig G₁ 15.8 g/L, Ig G₂ 1.92
 g/L, Ig G₃ 1.1 g/L, Ig G₄ 0.08 g/L), IgA 96.14
 mg/dL, IgM 119.95 mg/dL, IgD 0.55 mg/dL, IgE
 46.4 U/mL
 C3 61.16 mg/dL, C4 10.09
 mg/dL, CH50 30/mL
 DHR(dihydrorho-
 damine 123 fluorescence) flow cytometry

Peroxidase : 5

7

(leukocyte adhesion defect)

1.1×1.5 cm, 2.2×1.6 cm, 1.1×0.8 cm
가 가 가

(Fig. 2A). 31

(Fig. 2B).

: 5

가

(Fig. 3A, 3B).

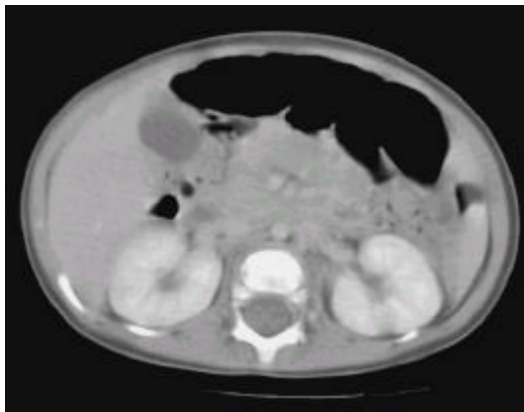


Fig. 2B. Abdominal CT shows that multiple low attenuated lesion with peripheral enhancement in the liver parenchyma and focal low attenuated small abscess pocket in inferior pole of left kidney has completely disappeared(Hospitalization day 31).

ceftriaxone amikacin
2 vancomycin metronidazol
가 5
amphotericin B 가

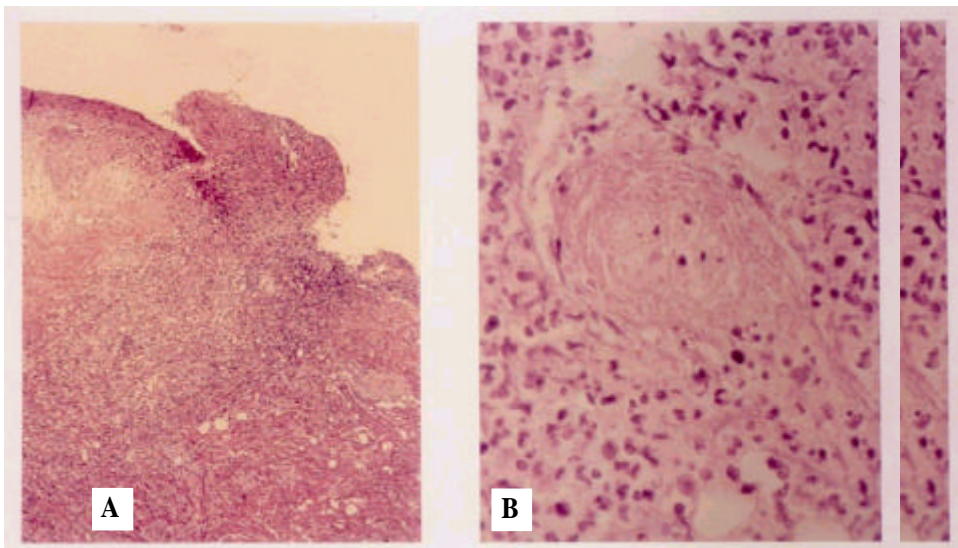


Fig. 3. Skin biopsy specimen from the border of ulceration shows epidermal necrosis and dermal edema and diffuse cellular infiltration throughout the dermis(A), necrotizing vasculitis and mixed cellular perivascular infiltration(B)(H&E stain, A ×40; B ×400).

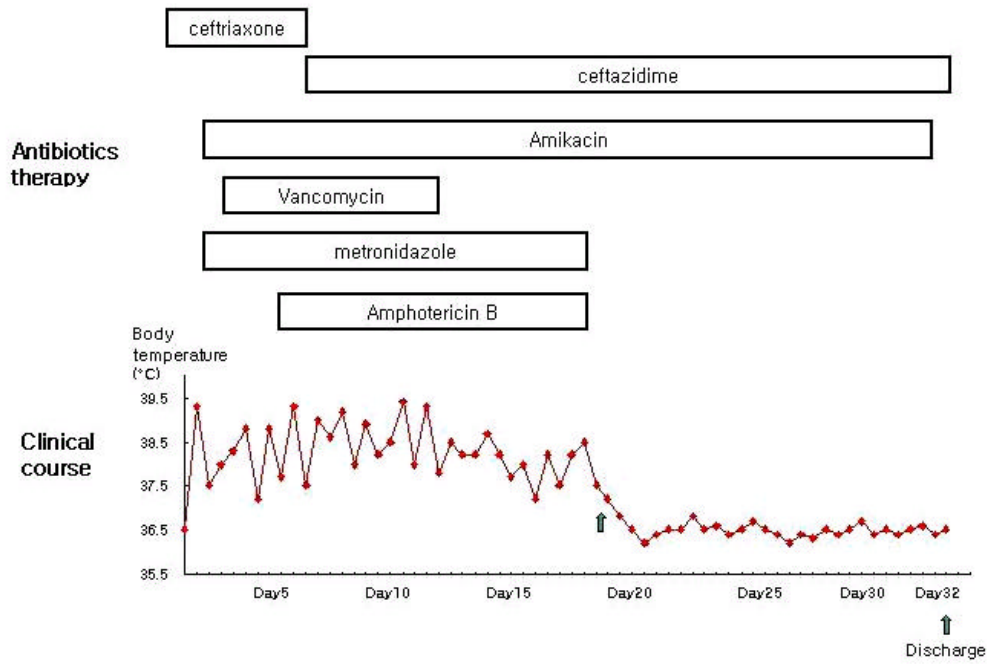


Fig. 4. Intravenous antibiotics therapy and clinical course - The patient was treated with combination therapy of intravenous ceftazidime and of intravenous amikacin for about 4 weeks. In the course of treating, his fever was subsided on the 19th day of hospitalizing and then the patient discharged on the 32th day of hospitalizing.

6 *Peu-* domonas aeruginosa가 ceftriaxone 6).
 ceftazidime . Vancomycin 11 ,
 metronidazole 17 , amphotericin B 14
 , 4 ceftazidime amikacin
 19 ,
 32 3).
 1897 Baker⁷⁾
 Hirschmann Kreibich가 “Ec-
 thyma gangrenosum” 1).
 6).
 1882 Gessard가 3, 4). Mull 8)
 10% Wong 9) 5)
 1 5)

가⁵⁾

30% *Pseudomonas aerugi-*
nosa ³⁾ 70% *Pseudomonas*
¹⁰⁾ *aeruginosa*가

가
gentamicin, tobramycin amikacin
ticarcillin, ceftazidime, piperacillin
¹⁾

가⁶⁾, Tep-
litz¹³⁾

5, 11, 12)

가
^{1, 14)}

¹³⁾

가
¹⁾ 1 6
amikacin ceftazidime

가
probenecid

(chloroma),
(erosive pyoderma associated with
inflammatory bowel disease), (peria-
anal abscess), (folliculitis),
(herpes simplex labialis)¹⁾

, 32

(erythema
multiforme), (panniculitis)

MacConkey , eosin methyl
blue(EMB) 1

가
가

- 1) Greene SL, Su WP, Muller SA. Ecthyma gangrenosum : report of clinical, histopathologic, and bacteriologic aspects of eight cases. *J Am Acad Dermatol* 1984;11:781-7.
- 2) Greene SL, Su WP, Muller SA. Pseudomonas aeruginosa infections of the skin. *Am Fam Physician* 1984;29:193-200.
- 3) Dorff GJ, Geimer NF, Rosenthal DR, Rytel MW. Pseudomonas septicemia : illustrated evolution of its skin lesion. *Arch Intern Med* 1971; 128:591-5.
- 4) Hall JH, Callway JL, Tindall JP, Smith JG Jr. Pseudomonas aeruginosa in dermatology. *Arch Dermatol* 1968;97:312-24.
- 5) , , , , .
1 .
1997;35:541-5.
- 6) Fast M, Woerner S, Bowman W, Christie K, Schroeder M, Albritton W. Ecthyma gangrenosum. *Can Med Assoc J* 1979;120:332-4.
- 7) Barker LF. The clinical symptoms, bacteriology findings and postmortem appearances in cases of infection of human beings with *Bacillus pyocyaneus*. *JAMA* 1897;29:213-6.
- 8) Mull CC, Scarfone RJ, Conway D. Ecthyma gangrenosum as a manifestation of pseudomonas sepsis in a previously healthy child. *Ann Emerg Med* 2000;36:383-7.
- 9) Wong SN, Tam AY, Yung RW, Kwan EY, Tsoi NN. Pseudomonas septicemia in apparently healthy children. *Acta Paediatr Scand* 1991;80: 515-20.
- 10) Hummer D, Igra YS, Morduchowicz G, Pitlik SD. Ecthyma gangrenosum without bacteremia : report of six cases and review of the literature. *Arch Intern Med* 1987;147:299-301.
- 11) Fergie JE, Patrick CC, Lott L. Pseudomonas aeruginosa cellulitis and ecthyma gangrenosum in immunocompromised children. *Pediatr Infect Dis J* 1991;10:496-500.
- 12) Song WK, Kim YC, Park HJ, Cinn YW. Ecthyma gangrenosum without bacteremia in a leukemic patient. *Clin Exp Dermatol* 2001;26: 395-7.
- 13) Teplitz C. Pathogenesis of pseudomonas vasculitis and septic lesions. *Arch Pathol* 1965;80: 297-307.
- 14) Kusne S, Eibling DE, Yu VL, Fitz D, Johnson JT, Kahl LE, et al. Gangrenous cellulitis associated with Gram-negative bacilli in pancytopenic patients : dilemma with respect to effective therapy. *Am J Med* 1988;85:490-4.