

랫드의 귀 연골염(Chondritis)

강 부 현

한국화학연구원 안전성평가연구소

본 질병의 다른 이름

Chodritis, external ear; inflammation, auricular cartilage

임상증상

Both pinnae are thickened, nodular, and droopy

본 질병의 개요 및 역학

The natural incidence of gross ear deformity in outbred SD rats which were obtained from Chales River Breeding Laboratories, Wilmington, Massachusettes, was reported to be 98 of 2733 (3.6%) males and 82 of 2148 (3.8%) females (Chiu and Lee 1984)

병리조직소견

Focal or multifocal, granulomatous inflammation; fibrovascular, fibrochondrous, chondrous, or chondroosseous tissue
나 or a mixture of these

원 인

Naturally, experimentally

진 단

Both pinnae are thickened, nodular, and droopy

병리기전

Inflammation → the cartilage plate is destroyed → formation of nodular masses of proliferative tissues followed by osseuos metaplasia

감별진단

Fibrochondroma, chondroma, chondrosarcoma

• 한국수의병리학회 홈페이지(<http://vetpathology.or.kr>)에서 동영상으로 설명을 들을 수 있습니다.

Auricular Chondritis

Case report

Case # : KRICT CASE 2002 1

Species: Rat (Sprague-Dawely), Male, 18-week-old, Control

Age: Terminal sacrificed


Organ: Ear

Gross finding: Both pinnae are thickened, nodular, and droopy

Stain: Hematoxylin & eosin

그림1, 2

Gross finding



resembling "cauliflower" and "wrestler" ears in man

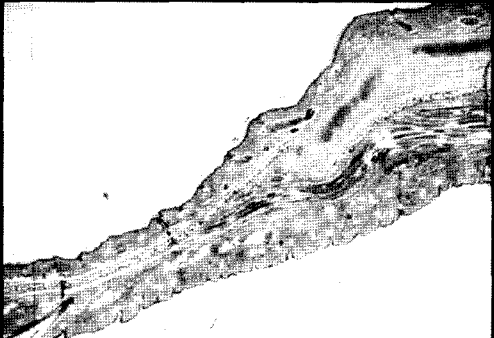


그림3, 4






그림5, 6






그림7, 8

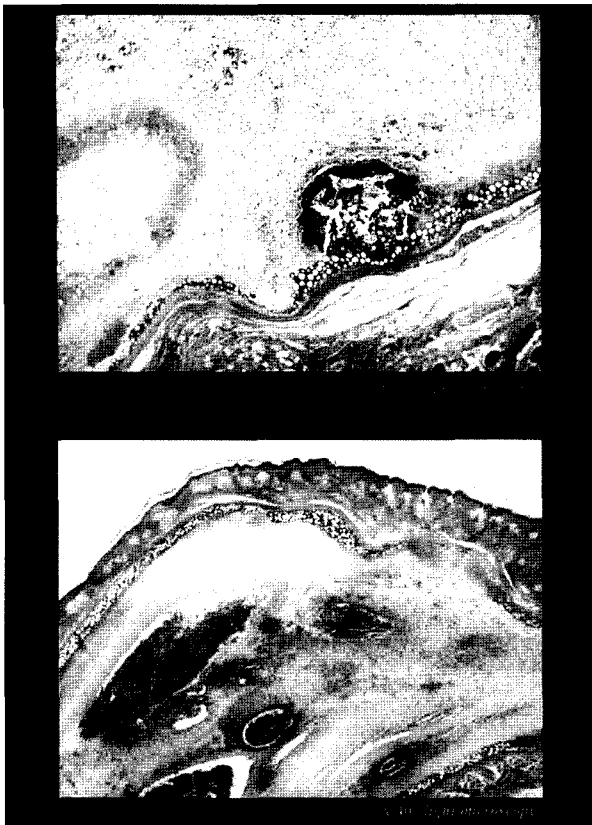


그림9, 10

Microscopic Features

- Granulomatous inflammation ; fibrovascular, fibrochondrous, chondrous, or chondroosseous tissue; or a mixture of these

Differential diagnosis

- Fibrochondroma
- Chondroma
- Chondrosarcoma

Auricular chondritis

- normal cartilage plate was once present
- focal mononuclear inflammatory infiltrates in the fibrovascular tissue

그림11, 12

Diagnosis

- SUBJECT : Chondritis, external ear
Inflammation, auricular cartilage
- Diagnosis : Spontaneous auricular chondritis

그림13