

Effects of *Opuntia ficus-indica* var. *Saboten* Stem on Gastric Damages in Rats

Eun Bang Lee¹, Jin Ee Hyun, Da Wei Li¹, and Yung In Moon²

¹Natural Products Research Institute, Seoul National University, Seoul 110-460 and ²Pukjeju Agricultural Development and Technology Extension Center, Jeju 695-907, Korea

(Received December 3, 2001)

The effects of the dried stem powder of *Opuntia ficus-indica* var. *saboten* (OF-s) were investigated on gastric lesion and ulcer models in rats. It showed significant inhibition in HCl-ethanol-induced gastric lesion at the doses of 200 and 600 mg/kg p.o. and in HCl-aspirin-induced gastric lesion at 600 mg/kg p.o. OF-s also showed significant inhibition in indomethacin-induced gastric lesion at the doses of 200 and 600 mg/kg, p.o. However, it did not affect both the aspirin-induced and Shay ulcers in rats. It also did not affect gastric juice secretion, acid output and pH. These data indicate that OF-s only possesses pronounced inhibitory action on gastric lesion without antiulcer activity in rats.

Key words: *Opuntia ficus-indica* stem, Cactaceae, Antigastric lesion

INTRODUCTION

Opuntia ficus-indica var. *saboten* Makino (Cactaceae) is a tropical or subtropical plant which has been widely used as folk medicine for burn, edema, cough, gastritis, diabetes, asthma, etc. (Ahn, 1998). It is described that the stem of *Opuntia* species are effective in gastric pain, bacterial diarrhea, insomnia, carbuncle, furuncle and clinically effective on congelation and mastitis (Jiansu New College of Medicine, 1977). It is reported that the stem of *O. ficus-indica* contains polysaccharides (mucus), mucilage, glucan, glucoprotein, and the fruit contains rutin, quercitrin, luteolin, kaempferol, peduletin, isorhamnetin glycoside, isobetain, betain (Yook, 1996). It is also reported that the stem of *Opuntia* species contains quercetin, kaempferol and isorhamnetin (Burret *et al.*, 1982). Recently, β -sitosterol was isolated as an anti-inflammatory principle of *O. ficus-indica* stem (Park *et al.*, 2001), and monoamine oxidase B inhibitors were also isolated from *O. ficus-indica* fruit (Han *et al.*, 2001). It is also reported that the ethanol extracts of the stem and fruit have inhibitory effects on carrageenan-induced paw edema and leukocyte migra-

tion in CMC pouch in rats (Park *et al.*, 1998). The hypoglycemic properties (Ibanez-Camacho *et al.*, 1979) and inhibition of DNA and RNA virus replication and inactivation of extracellular virus was also reported (Ahmad *et al.*, 1996). On the effects in stomach, the lyophilized inner part of the stem was found to have protective action against ethanol-induced ulcer (Galati *et al.*, 2001) and an ethanol extract of the stem had protective effect against HCl-ethanol-induced gastric lesion (Park *et al.*, 1998). The aim of this study is to investigate the effectiveness of *O. ficus-indica* stem on various gastric lesion and ulcer models in rats.

MATERIALS AND METHODS

Plant material and chemicals

O. ficus-indica stem cultivated in the Cheju island was used. The 1-year-old stem was cut in pieces without spines, lyophilized and grinded into powder. The powder (OF-s) for this study was prepared from Pukjeju Agricultural Development and Technology Extension Center. Total yield of OF-s used for the tests was corresponded to $10 \pm 0.5\%$ from the raw material. This substance OF-s was used as a test sample. Ranitidine (Union Quimico Farmaceutica S.A. Spain) and indomethacin (Sigma Chemical Co.) were used, and other drugs used were either pharmaceutical or reagent grade.

Correspondence to: Eun Bang Lee, Natural Products Research Institute, Seoul National University, Seoul 110-460, Korea
E-mail: eblee@snu.ac.kr

Animals

Male Sprague-Dawley rats were supplied from breeding facilities of Natural Products Research Institute, Seoul National University. Solid food (Samyang Yuji Co. Ltd.) and tap water were provided *ad libitum*. All animals were housed for 1 week in a controlled 12 h light-dark environment at $22 \pm 1^\circ\text{C}$. The substance was suspended in 0.5% CMC in distilled water and administered in a volume of 0.5 ml/100 g (b.w.). Control group received only 0.5% CMC solution.

HCl-ethanol-induced gastric lesion

The experiment was performed according to the method of Mizui and Dodeuchi (1983). Briefly, the rats (180-200 g) were fasted for 24 h with free access to water prior to experiment. HCl-ethanol (60% ethanol with 150 mM HCl) solution in a volume of 0.5 ml/100g was orally administered. One hour later, the animals were sacrificed under ether anesthesia, and each stomach was excised. Then, 12 ml of 2% formalin was infused into the stomach, and the stomach was soaked in 2% formalin for 10 min. The stomach was incised along the greater curvature and examined for the presence of gastric lesion in the glandular portion. The length (mm) of each lesion was measured under the dissecting microscope (10 \times), and total value was expressed as a lesion index. The substance was given orally 30 min prior to administration of HCl-ethanol solution.

HCl-aspirin-induced gastric lesion

According to the method of Guth *et al.* (1979), the rats (180-200g) fasted for 24 h with free access to water were given orally 150 mM HCl with aspirin 200 mg/kg suspended in 5% gum acacia in a volume of 0.5 ml/100 g. One hour later, the animals were sacrificed and each stomach was excised and fixed with formalin solution as described above and the lesion index was measured. The substance was given orally 30 min prior to administration of HCl-aspirin solution.

Indomethacin-induced gastric lesion

According to the method of Suzuki *et al.* (2000), the rats (180-200 g) fasted for 24 h were given orally with the substance, and 30 min later indomethacin 35 mg/kg suspended in 0.5% CMC was injected subcutaneously. The animals were sacrificed 7 h after indomethacin injection and the excised stomach was treated as described above and the area (mm²) of hemorrhagic lesion developed in the corpus mucosa was measured.

Aspirin-induced gastric ulcer

According to the method of Okabe *et al.* (1974), the

pylorus of the rat (200-220 g) fasted for 24 h was ligated under ether anesthesia, and the substance was given by intragastrically after pylorus-ligation. Ten minutes later, aspirin 150 mg/kg suspended in 0.5% CMC was administered orally in a volume of 0.5 ml/100g. Seven hours after aspirin treatment, the animals were sacrificed and each excised stomach was treated as described above and glandular portion was examined for evaluation of the ulcers.

Shay ulcer

According to the method of Shay *et al.* (1945), the pylorus of the rat (210-230 g) fasted for 36 h was ligated under ether anesthesia. The substance was given intraduodenally immediately after pylorus-ligation. Fifteen hours later, the animal was sacrificed and the excised stomach was treated as described above and examined for gastric ulcers in the forestomach. The area of each ulcer was measured and summed. The severity of ulcers was graded into degrees as following. The ulcer index was expressed according to the severity of ulcer, 1, no lesion; 2, bleeding or light; 3, moderate; 4, severe; 5, perforation.

Gastric secretion

Rats (220-240 g) fasted for 16 h were anesthetized with ether and the pylorus was ligated by the method of Shay *et al.* (1945). The substance was given intraduodenally immediately after pylorus-ligation. Four hours later, the animals were sacrificed and the stomach was excised. The contents of stomach were collected and centrifuged at 3000 rpm for 10 min. Total gastric juice volume and pH were measured, and acidity was determined by titration of the gastric juice with 0.05N NaOH using phenolphthalein as an indicator.

Statistical analysis

All data represent means \pm S.E. Statistical analyses of the data were performed using analysis of variance followed by Student's *t*-test. All data were evaluated at the $p < 0.05$ level of significance.

RESULTS

HCl-ethanol-induced gastric lesion

As shown in Fig. 1, the lesion index of control group is 98.2 and OF-s at the doses of 200 and 600 mg/kg p.o. showed significant inhibition by 62 and 61.7%, respectively. Ranitidine at a dose of 50 mg/kg showed inhibition by 78.5%.

HCl-aspirin-induced gastric lesion

As shown in Fig. 2, OF-s at a dose of 600 mg/kg p.o.

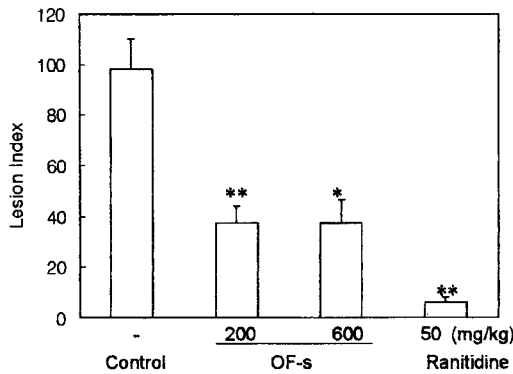


Fig. 1. Effect of OF-s on HCl ethanol-induced gastric lesion. * $p < 0.05$, ** $p < 0.01$; Significantly different from the control group. (n=8)

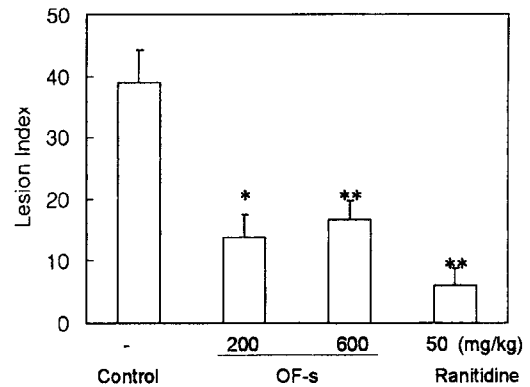


Fig. 3. Effect of OF-s on indomethacin-induced gastric lesion. * $p < 0.01$, ** $p < 0.001$; Significantly different from the control group. (n=8)

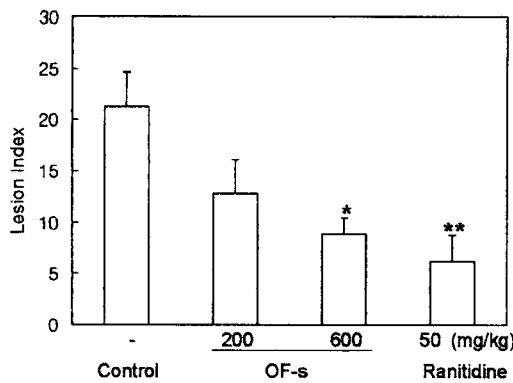


Fig. 2. Effect of OF-s on HCl aspirin-induced gastric lesion. * $p < 0.01$, ** $p < 0.001$; Significantly different from the control group. (n=8)

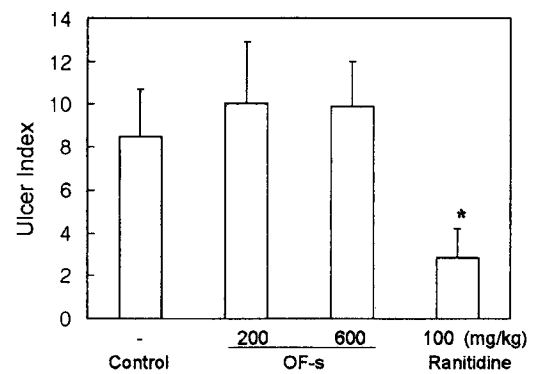


Fig. 4. Effect of OF-s on aspirin-induced gastric ulcer. * $p < 0.01$; Significantly different from the control group. (n=8)

showed significant inhibition by 58%. Ranitidine at 50 mg/kg showed inhibition by 71.1%.

Indomethacin-induced gastric lesion

The effect of OF-s on indomethacin-induced gastric lesion was represented in Fig. 3. It showed significant inhibition at the doses of 200 and 600 mg/kg p.o. by 64.5% and 57.5%, respectively. Ranitidine at 50mg/kg showed 86.4% inhibition.

Aspirin-induced gastric ulcer

As shown in Fig. 4, OF-s at the intragastric doses of 200 and 600 mg/kg did not show inhibition of the ulcer.

Shay ulcer

As shown in Fig. 5, OF-s at the intraduodenal doses of 200 and 600 mg/kg did not affect the ulcer.

Gastric secretion

The effect of OF-s on gastric secretion in rats is shown in Table I. OF-s at 200 and 600 mg/kg given intraduode-

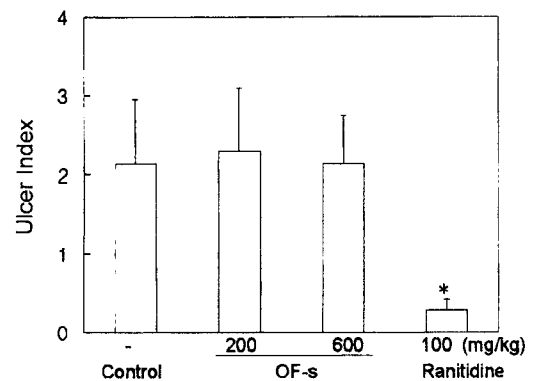


Fig. 5. Effect of OF-s Shay ulcer. * $p < 0.01$; Significantly different from the control group. (n=8)

nally did not affect the volume of gastric acid secretion, acid output and pH, while ranitidine at a dose of 50 mg/kg showed significant inhibition of acid secretion and acid output and increases in pH.

DISCUSSION

Effects of OF-s on the models of gastric lesion and two

Table 1. Effects of OF-s on gastric juice secretion

Treatment	Dose (mg/kg, i.d.)	No. of animals	Gastric juice volume (ml)	pH	Acidity ($\mu\text{g eq/ml}$)	Acid output ($\mu\text{g eq/ml/4h}$)
Control	-	8	4.86 \pm 0.9	1.2 \pm 0.1	116.1 \pm 5.5	589.6 \pm 122
OF-s	200	8	5.19 \pm 0.4	1.3 \pm 0.0	110.3 \pm 5.4	576.3 \pm 55
	600	8	4.47 \pm 0.8	1.3 \pm 0.1	106.1 \pm 13	523.6 \pm 132
Ranitidine	50	8	1.91 \pm 0.3*	5.7 \pm 0.9**	90.9 \pm 11*	198.9 \pm 22*

* $p < 0.05$, ** $p < 0.01$; Significantly different from the control group.

models of gastric ulcer in rats were investigated. OF-s showed significant inhibition on HCl-ethanol-, HCl-aspirin- and indomethacin-induced gastric lesions. The ethanol extract of *O. ficus-indica* stem was reported to have positive activity on HCl-ethanol-induced gastric lesion (Park *et al.*, 1998), and the lyophilized fraction of the fresh tissue deprived of glochis and epidermis was reported to have inhibitory effect on gastric lesion induced with 90% ethanol (Galati *et al.*, 2001). HCl-ethanol and HCl-aspirin-induced lesions are known to be produced by direct irritation of gastric mucosal barrier (Seiki *et al.*, 1990). Thus the effectiveness of OF-s on these gastric lesions might be related to direct protection of the irritation. OF-s also showed effect on indomethacin-induced gastric lesion. Takeuchi *et al.* (1986) reported that an increase of gastric motility in rats may play a role in the pathogenesis of lesion induced by indomethacin. However, its effectiveness is unknown at present except the cytoprotective effect. OF-s did not affect aspirin-induced and Shay ulcer, and also did not affect gastric juice secretion, acid output and pH. The negative anti-ulcer activity of OF-s might be related to no effects on gastric acid secretion. Thus, it is described that the mode of activity of OF-s is different from that of ranitidine, a proton pump inhibitor.

In conclusion, these results indicate that OF-s possesses pronounced inhibitory action on gastric lesion, but does not have anti-ulcer activity in rats.

REFERENCES

- Ahmad, A., Davides, J., Randall, S., and Skinner, G. R., Antiviral properties of extract of *Opuntia streptacantha*. *Antiviral Res.*, 30, 75 (1996).
- Ahn, D. K., Illustrated book of Korean medicinal herbs, Kyohaksa, Seoul, pp.497, 1998
- Burret, F., Lebreton, P. H., and Voirin, B., Les aglycones flavoniques de cactees: distribution, signification. *J. Nat. Pro.*, 45, 687-693 (1982).
- Guth, P. H., Aures, D., and Paulsen, G., Topical Aspirin Plus HCl Gastric Lesions in the Rat. *Gastroenterology*, 76, 88 (1979).
- Galati, E. M., Monforte, M. T., Tripodo, M. M., d'Aquino, A. and Mondello, M. R., Antiulcer activity of *Opuntia ficus-indica* (L.) Mill. (Cactaceae): ultrastructural study. *J. Ethnopharmacol.*, 76, 1-9 (2001).
- Han, Y. N., Choo, Y. S., Lee, Y. C., Moon, Y. I., Kim, S. D., and Choi, J. W., Monoamine oxidase B inhibitors from the fruits of *Opuntia ficus-indica* var. *saboten*. *Arch. Pharm. Res.*, 24, 51-54 (2001)
- Ibanez-Camacho, R. and Roman-Rarnos, R. Hypoglycemic effect of *Opuntia cactus*. *Arch. Invest. Med. (Mex)*, 10, 223 (1979).
- Jeong, S. J., Jun, K. Y., Kang, T. H., and Ko, E. B. *et al.*, Flavonoids from the fruits of *Opuntia ficus-indica* var. *saboten*. *Kor. J. Pharmacogn.*, 30, 84-86 (1999).
- Jiansu New College Medicine Eds. Encyclopedia of Chinese Herbs, Shanghai Science & Technology Publication, Shanghai, pp. 663 (1977).
- Lee, H. J., Korean flora, Moonkyobu Eds, Seoul, pp. 113, 1964.
- Mizui, T. and Dodeuchi, M., Effect of polyamines on acidified ethanol induced gastric lesion in rats. *Jpn. J. Pharmacol.*, 33, 939-945 (1983).
- Okabe, S., Takeuchi, K., Nakamura, K., and Takagi, K., Pathogenesis of gastric lesion induced by aspirin in the pylorus-ligated rat. *Jpn. J. Pharmacol.*, 24, 363 (1974).
- Park, E. H., Kahng, J. H., and Paek, E. A., Studies on the pharmacological actions of cactus: Identification of its anti-inflammatory effect. *Arch. Pharm. Res.*, 21, 30 (1998).
- Park, E. H., Kahng, J. H. Lee, S. H., and Shin, K. H., An anti-inflammatory principle from cactus. *Fitotherapy*, 72, 288-290 (2001).
- Seiki, M., Ueki, S., Tanaka, Y., and Soeda, M., Studies of anti-ulcer effects of a new compound, zinc L-carnosine (Z-103). *Folia Pharmacol. Japan*, 95, 257 (1990).
- Shay, H., Komarov, S. A., Fels, S. S., and Meranze, D., A simple method for the uniform production of gastric ulceration in the rat. *Gastroenterology*, 4, 43-61 (1945).
- Suzuki, K., Araki, H., Komoike, Y., and Takeuchi, K., Permissive role of neutrophils in pathogenesis of indomethacin-induced gastric lesion in rats. *Med. Sci. Monit.*, 6, 908-914 (2000).
- Takagi, K., Takeuchi, K., Nakamura, K., Morita, A., and Okabe, S., Effects of an antiulcer agent, N-acetyl-L-glutamine aluminum complex (KW-110) on the duodenal and gastric ulcer models in the rat. *Jpn. J. Pharmacol.*, 24, 357-361 (1974).
- Takeuch, K. and Ueki, S., Importance of gastric motility in the pathogenesis indomethacin- induced gastric lesion in rats. *Dig. Dis. Sci.*, 31, 1114 (1986).
- Yook, C. S., Saengyak Dogam, Gyoungwon Publ. Co., Seoul, pp. 351, 1996.