

# 골다공증성 척추 압박골절 환자의 경피적 척추성형술에서 Polymethylmethacrylate의 경막 외 유출\*

가

오윤규 · 류경식 · 박춘근 · 강준기

= Abstract =

## Epidural Leakage of Polymethylmethacrylate Following Percutaneous Vertebroplasty in the Patients with Osteoporotic Vertebral Compression Fractures

Yoon-Kyu Oh, M.D., Kyeong-Sik Ryu, M.D.,  
Chun-Kun Park, M.D., Joon-Ki Kang, M.D.

*Department of Neurosurgery, Kang Nam St. Mary's Hospital, College of Medicine,  
The Catholic University of Korea, Seoul, Korea*

**Objectives** : The percutaneous vertebroplasty provides a good result in the treatment of osteoporotic vertebral compression fractures. But, the epidural leakage of polymethylmetacrylate(PMMA) after vertebroplasty may decrease the therapeutic effects because of the compression of thecal sac and/or nerve roots. The authors carried out a prospective study to evaluate the causative factors of epidural leakage of PMMA and to assess the influence on the outcome.

**Methods** : This study involved 347 vertebral levels of compression fractures in 159 patients. Among these, the epidural leakages were identified in 92 vertebral levels(26.5%) in 64 patients(40.3%) on post - operative CT scan.

**Results** : The incidence of epidural leakage of PMMA was significantly higher in the level above T7( $p=0.001$ ). The large amount of the injected PMMA and the use of an injector also increased the incidence( $p=0.03$  and  $p=0.045$ , respectively). The position of the needle tip in the vertebral body and the pattern of venous drainage did not influence. The immediate post - operative visual analogue scale(VAS) scores and facial scales(FS) were higher in the patients with epidural leakage( $p=0.009$ ). But there were no significant differences between the two groups after three months of operation( $p=0.541$ ).

**Conclusions** : The incidence of epidural leakage of PMMA after percutaneous vertebroplasty appears to have relationship with the amount of PMMA and the levels injected. The epidural leakage of PMMA reduced the immediate therapeutic effects of vertebroplasty, but did not influence the late outcome. However, the epidural leakage should be avoided because of its potential neurological complications.

**KEY WORDS** : Epidural leakage · Vertebroplasty · Polymethylmetacrylate(PMMA) · Osteoporosis · Vertebral compression fractures.

---

서 론

---

2000

가

가

(PMMA)

polymethylmethacrylate

대상 및 방법

가

1)2)4)7 - 12)14)15)17 - 19)

1999 7

2000 2

1)2)4)8 - 10)13)14)17)

75~90%

PMMA  
CT

159

CT PMMA

64 (40.3%)

(Fig. 1).

17 PMMA

bowl 10cc PMMA 가

가

2cc

가

PMMA

가

10cc 1

injector( )

2)9)12)16)

PMMA

가

PMMA

PMMA

159  
PMMA

(cc)

2cc

, 2

3.9cc, 4

PMMA  
5.9cc

64

6cc

PMMA

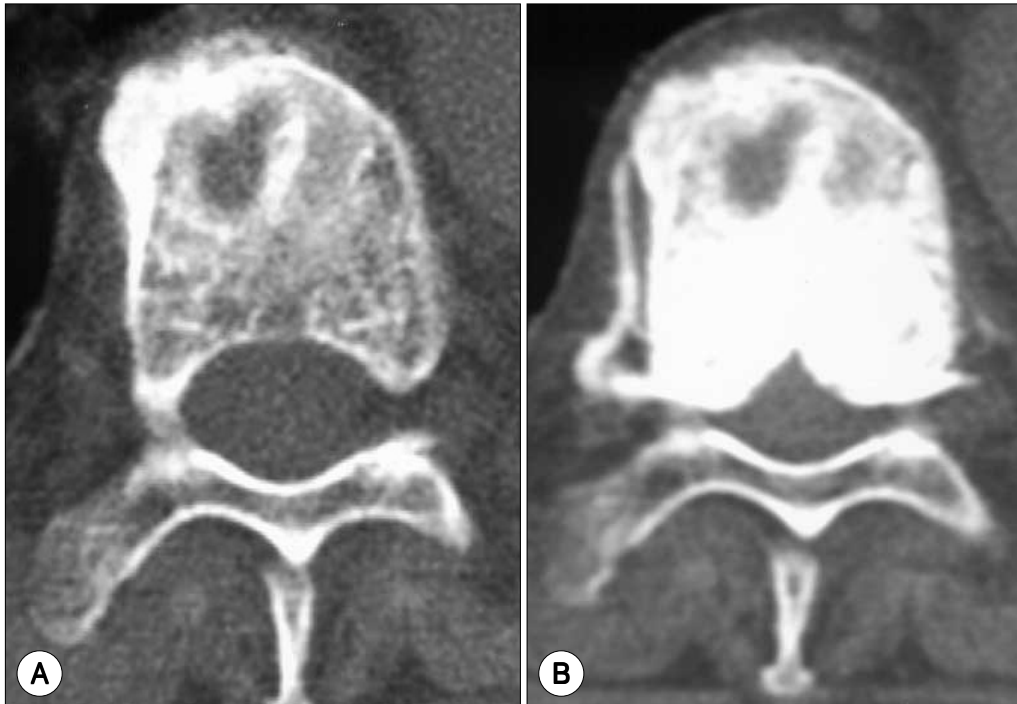


Fig. 1. A : Axial CT scan showing wedge compression fracture of vertebral body with double-contoured margin of the body. B : Postoperative CT scan at the same level showing epidural leak of PMMA through the basivertebral foramina into the intervertebral foramen as well as the spinal canal

가 PMMA 3 1/3 (venogram) PMMA Isovist 가 1999 9 PMMA injector PMMA 가

46.7% 가 37 (22.8%) T7 7 6, 86% (Table 1). PMMA PMMA 7 PMMA 가 가 (Table 2). PMMA 가 (Table 3), (Table 4). Injector PMMA 가 가 (Table 5).

VAS (visual analogue scale) (0~10) facial scale(FS) VAS FS가 “no change”, “improved”, 가 “aggravated” 1 3 17). PMMA SAS for window 6.12 p<0.05

**Table 1.** Distribution of vertebral levels treated with vertebroplasty

Vertebral level	Number		%
	Total cases	Epidural leakage	
Above T7	7	6	85.7
T8 - T10	32	7	21.9
T11 - L1	146	42	28.8
Below L2	162	37	22.8
Total	347	92	26.5

The leakage rate between levels was significantly different (p=0.002) especially, leakage rate above T7 and T11-L1 was significantly higher than that of other levels(p=0.001, p=0.005 respectively)

**Table 2.** Distribution of the amount of injected PMMA\* for vertebroplasty according to vertebral levels

Vertebral levels	Amount of injected PMMA			
	Below 2cc	2 - 3.9cc	4 - 5.9cc	Above 6cc
Above T7	0	4(3)**	2( 1)	2( 2)
T8 - T10	3(1)	14(1)	7( 2)	8( 3)
T11 - L1	3(1)	37(9)	44(10)	62(22)
Below L2	1(0)	36(4)	61(13)	63(20)

There was significant association between injection dose and leakage rate after adjusted for level(p=0.03)

\*PMMA ; polymethylmetacrylate

\*\*The number in parenthesis represents the number of the cases of epidural leakage

**결 과**  
159 CT PMMA 64 40.3% 347 92, 26.5% 162 2



tebral foramen basiver-  
PMMA가 (anterior in-  
ternal venous plexus)

2)9)12)  
PMMA  
Cotten 6)  
40 15 ,  
37.5% PMMA가  
basivertebral foramina

1  
159 40.3% 46 , 347  
26.5% 92 PMMA

가 CT  
PMMA  
basivertebral foramina

PMMA  
PMMA  
가 가

PMMA가  
가  
PMMA  
PMMA

PMMA  
PMMA 20)  
PMMA  
가 ,  
가 , PMMA

PMMA injector  
가 가 가  
가

가

1/2 . PMMA  
가 가 , injector

가  
가 가 PMMA  
injector 가

PMMA  
PMMA (liquid consistency)  
PMMA 5)

가 가 ,  
PMMA 가  
PMMA

PMMA  
PMMA  
PMMA 가

1  
Chiras 3) 67  
258

가  
가

가  
결 론  
PMMA

가  
PMMA

가 가  
 .  
 injector 가  
 가  
 PMMA  
 PMMA  
 PMMA  
 .  
 PMMA  
 가  
 .  
 • : 2000 7 13  
 • : 2000 12 1  
 • :  
 137 - 040 505  
 가  
 : (02) 590 - 2569, : (02) 594 - 4248  
 E - mail : nsdoc35@cmc.cuk.ac.kr

References

1) Barr JD, Barr MS, Lemley TJ, McCann RM : *Percutaneous vertebroplasty for pain relief and spinal stabilization. Spine 15 ; 25 (8) : 923-928, 2000*  
 2) Bostrom MP, Lane JM : *Future directions. Augmentation of osteoporotic vertebral bodies. Spine 15 ; 22 (24 Suppl) : 38S-42S, 1997*  
 3) Chiras J, Dermond H : *Complications des vertebroplasties, in Saillant G, Laville C (eds) : Echecs et complications de la chirurgie du rachis : chirurgie de reprise. Paris, France : Sauramps Medical 1995, pp49-153*  
 4) Cortet B, Cotten A, Boutry N, Flipo RM, Duquesnoy B, Chastanet P, et al : *Percutaneous vertebroplasty in the treatment of osteoporotic vertebral compression fractures : An open prospective study. J Rheumatol 26 (10) : 222-228, 1999*  
 5) Cotten A, Boutry N, Cortet B, Assakar R, Demondion X, Leblond D, et al : *Percutaneous vertebroplasty : State of the art. Radiographics 18 : 311-320, 1998*  
 6) Cotten A, Dewatre F, Cortet B, Assakar R, Leblond D, Duquesnoy B, et al : *Percutaneous vertebroplasty for osteolytic metastases and myeloma : Effects of the percentage of lesion filling and the leakage of methyl methacrylate at clinical follow-up. Radiology 200 : 525-530, 1996*  
 7) Cotten A, Duquesnoy B : *Vertebroplasty : current data and*

*future potential. Rev Rhum Engl Ed 64 (11) : 645-649, 1997*  
 8) Cyteval C, Sarrabere MP, Roux JO, Thomas E, Jorgensen C, Blotman F, et al : *Acute osteoporotic vertebral collapse : open study on percutaneous injection of acrylic surgical cement in 20 patients. AJR Am J Roentgenol 173 (6) : 1685-1690, 1999*  
 9) Deramond H, Depriester C, Galibert P, Le Gars D : *Percutaneous vertebroplasty with polymethylmethacrylate. Technique, indications, and results. Radiol Clin North Am 36 (3) : 533-46, 1998*  
 10) Dunnagan SA, Knox MF, Deaton CW : *Osteoporotic compression fracture with persistent pain. Treatment with percutaneous vertebroplasty. J Ark Med Soc 96 (7) : 258-259, 1999*  
 11) Gangi A, Dietemann JL, Mortazavi R, Pflieger D, Kauff C, Roy C : *CT-guided interventional procedures for pain management in the lumbosacral spine. Radiographics 18 (3) : 621-633, 1998*  
 12) Jensen ME, Evans AJ, Mathis JM, Kallmes DF, Cloft HJ, Dion JE : *Percutaneous polymethylmethacrylate vertebroplasty in the treatment of osteoporotic vertebral body compression fractures : technical aspects. AJNR Am J Neuroradiol 18 (10) : 1897-1904, 1997*  
 13) Lee JU, Ryu KS, Park CK, Choi YG, Park CK, Chi C, et al : *Percutaneous polymethylmethacrylate vertebroplasty with in the treatment of osteoporotic thoracic and lumbar vertebral body compression fractures : outcome of 159 patients. J Korean Neurosurg Soc 2000 (submitted)*  
 14) Martin JB, Jean B, Sugi K, San Millan Ruiz D, Piotin M, Murphy K, et al : *Vertebroplasty : clinical experience and follow up results. Bone 25 (2 Suppl) : 11S-15S, 1999.*  
 15) Mathis JM, Petri M, Naff N : *Percutaneous vertebroplasty treatment of steroid-induced osteoporotic compression fractures. Arthritis Rheum 41 (1) : 171-175, 1998*  
 16) Padovani B, Kasriel O, Brunner P, Peretti-Viton P : *Pulmonary embolism caused by acrylic cement : A rare complication of percutaneous vertebroplasty. AJNR Am J Neuroradiol 20 (3) : 375-377, 1999*  
 17) Park CK, Lee KS, Choi YG, Ryu KS, Park CK, Cho KS, et al : *Percutaneous vertebroplasty with polymethylmethacrylate in the treatment of osteoporotic vertebral body compression fractures : priliminary report. J Korean Neurosurg Soc 29 : 365-371, 2000*  
 18) Rapado A : *General management of vertebral fractures. Bone 18 (3 Suppl) : 191S-196S, 1996*  
 19) Tamayo-Orozco J, Arzac-Palumbo P, Peon-Vidales H, Mota-Bolfeta R, Fuentes F : *Vertebral fractures associated with osteoporosis : patient management. Am J Med 18 ; 103 (2A) : 44S-48S ; discussion 48S-50S, 1997*  
 20) Tohmeh AG, Mathis JM, Fenton DC, Levine AM, Belkoff SM : *Biochemical efficacy of unipedicular versus bepedicular vertebroplasty for the management of osteoporotic compression fractures. Spine 24 : 1772-1776, 1999*