

# The Effects of Alendronate on healing of the extraction sockets in rats

Keung-Ky Moon, Jae-Mok Lee, Jo-Young Suh

Department of Periodontology, College of Dentistry, Kyunpook National University

## I. Introduction

Periodontium largely consists of gingiva, periodontal ligament and alveolar bone. Its role is attaching teeth to the basal bone, and maintaining masticatory mucosa in the oral cavity. Alveolar bone, a part of maxilla and mandible which surrounds the roots and supports teeth, has a significant role of scattering or absorption of compression to the teeth during mastication, speaking, and swallowing. All bony tissues, including alveolar bone, are constantly being remodeled by the processes of resorption and formation. But in case of bone destruction such as osteometabolic disease or tumoral disease, osteoporosis by hormonal change after menopause, there is a necessity for preventing the reduction of bone mass and controlling of bone formation.

The bisphosphonates, which inhibit bone resorption by osteoclasts, are chemically analogs of pyrophosphates. The P-C-P bond instead of P-O-P bond is stable to heat and most chemical reagents and completely resistant to enzymatic hydrolysis and has a strong affinity for hydroxyapatite. In particular, bisphosphonates are reported to deposit well at the site of new bone formation<sup>1-3)</sup>.

Until now, a great number of bisphosphonates have been synthesized and each of them possesses its own physicochemical and biological characteristics. This implies that it is not possible to extrapolate from the results of one compound to others with respect to their actions. Bisphosphonates can exert physicochemical effects very similar to those of polyphosphonates, binding to the surface of calcium phosphate crystals and inhibiting their formation and aggregation as well as their dissolution.

The pharmacokinetic characteristics of bisphosphonates are, in case of alendronate, that 30-40% of them are eliminated in the urine by 24 hours post-dose, and only a negligible amount of the drug ((0.2%) is detected in faeces. About 60-70% of them are sequestered in the bone over the short term, and alendronate is slowly released from the skeletal deposits, accounting for the prolonged multiple-phase elimination of this drug. It has been estimated that the half-life of alendronate is approximately 300 days in rats and at least 1000 days in dogs<sup>4)</sup>.

Although the action mechanism of the bisphosphonates on bone resorption is not completely elucidated, there is a general consensus that the bisphosphonates act on osteoclasts or osteoblasts. It is

reported that bisphosphonates have a direct effect on the activity of the osteoclasts<sup>5-7</sup>). Some authors reported that bisphosphonates reduced the life of osteoclasts by programmed cell death (apoptosis), thus have an effect on osteoclast recruitment directly or indirectly<sup>8</sup>). Others said that bisphosphonates have an influence on osteoblasts as well as osteoclasts, and control the differentiation or function of the osteoclasts. It is reported that bisphosphonates have an effect on osteoblasts, thus inhibit formation of osteoclasts<sup>9</sup>), and induce the osteoclast-mediated resorption inhibiting factors<sup>10</sup>).

Clinical application of bisphosphonates is very wide and various. In particular, it is known that bisphosphonate is used to inhibit bone resorption of patients who have bone destruction disease such as Paget's disease, tumoral bone disease, hypercalcemia of malignancy, postmenopausal osteoporosis, osteogenesis imperfecta, and so forth<sup>11-15</sup>).

In dentistry, though it is an elementary phase, much research has been accomplished. It is reported that, in monkey test, bisphosphonate retarded the progression of the experimentally induced periodontitis<sup>16</sup>). In rat test, bisphosphonate treated groups revealed reduction of alveolar resorption after mucoperiosteal flap surgery<sup>17,18</sup>), and an increase of the bone mass and mechanical strength of the rat<sup>19</sup>). Some authors reported that, in orthodontic therapy, bisphosphonate was available to inhibit movement of the teeth as anchorage and relapse<sup>20,21</sup>).

Bone resorption could occur horizontally or vertically after tooth extraction. This bone resorption would cause some disturbance in the periodontal treatment, prosthetic treatment and implant surgery. Now various therapeutic agents have been developed for inhibiting bone resorption and increasing esthetic and functional clinical outcomes, and bisphosphonates are a part of this development.

Therefore we investigated, in this study, the effects

of bisphosphonates on healing of the rat's extraction socket, which has a good experimental design to regeneration of tissue destruction, where periodontal ligaments remained and active granulation tissue formation occurred and progressed to bone formation.

We also investigated the effects of bisphosphonates, as inhibiting factors of osteoclastic activity .

## II. Materials and Methods

### 1. Animals and Drug treatment

A total of 18 Sprague-Dawley rats were used for experimental animals in this study. These animals were 2 months old. Alendronate (Yu Yu Pharm, Korea) treated and control groups contained 3 animals each, which were used to investigate the effect of alendronate on rat's extraction healing by a time course of 1, 2, 4 weeks.

To extract easily and minimize injury,  $\beta$ -Aminopropionitrile (APN) 0.28g/kg · day (Sigma, USA) soluted in mineral water was administrated for 5 days before extraction in both groups. Rompun (BayerKorea, Korea) 0.82cc, Ketamine hydrochloride (Youhan Pharm, Korea) 7cc, normal saline 2cc were mixed and injected intraperitoneally by 0.3cc/200g for general anesthesia. The rats were anesthetized inhalatively with ether. Thus maxillary first molars were extracted carefully. Extraction was completed with modified forcep with sufficient luxation.

Ampicillin 1.5ml/kg (Young Jin Pharm, Korea) was administrated intramuscularly for preventing infection after tooth extraction in both groups, and alendronate 1mg/kg on test group, vehicle (0.9% saline) on control were injected 3 times / week for 2 weeks. Three rats on each day were sacrificed on 1, 2, 4 weeks after extraction.

### 2. Histologic evaluation

All animals were sacrificed on 1, 2, 4 weeks by heart perfusion, and specimens were taken at the site of alveolar bone around the extraction areas.

Specimens from alendronate or control group were fixed with the mixture of 4% paraformaldehyde in 0.1M phosphate buffered saline (PBS). After demineralization with 10% EDTA, dehydrated with a graded series of ethanol, specimens were embedded in paraffin, sectioned at 5 $\mu$ m with microtome, and stained with hematoxylin and eosin (H&E). To evaluate osteoclastic activity, tartrate resistant acid phosphatase (TRAP) staining was done. TRAP activity was detected by incubation for 10 min with a mixture of 0.1mg/ml naphthol AS-MX phosphate (Sigma, USA), 0.5% N, N-dimethylformamide, 0.6 mg/ml fast red violet LB (Sigma, USA) in 0.1M acetate buffer solution (pH 5.0) at 37°C.

### 3. Hardness measurement

The hardnesses of specimens from test or control group were estimated by the hardness measurement instrument (FUTURE-TECH, FM-7, Matsuzawa 10, Japan), under the condition of load 50 g, loading time 10 sec. Each specimen was measured on 1, 2, 4 weeks after extraction 6 times per specimen, and the mean values were tested statistically with student-t test.

## III. Results

### 1. Histologic findings (by H&E staining)

#### 1) 1 week after extraction

There was a similar healing aspect between test and control groups. Blood clots disappeared in the center of extraction socket, and fibrous connective tissues were formed by fibroblasts. Formation of trabecular pattern in the marginal bone area was partially shown (Fig. 2a, 2b.).

#### 2) 2 weeks after extraction

There was a similar healing aspect between test and control groups. Extraction socket was healed by fibrous connective tissue, and significant decrease of inflammatory cells and active formation of trabecular pattern at the marginal bone area were shown, and gingival epithelium was almost healed (Fig 3a, 3b).

#### 3) 4 weeks after extraction

There was a similar healing aspect between test and control groups. New bone formation was shown in most of the extraction socket, and active osteoblasts were shown mostly in the alveolar crest area. Epithelium was well keratinized above the extraction socket. Osteocyte formation was also shown (Fig 4a, 4b).

## 2. Osteoclastic activity by TRAP staining

While there was a similar aspect between 1 week and 4 weeks groups, test groups showed more reduced osteoclastic activity than control group in 2 weeks groups (Fig 5a, 5b, 6a, 6b, 7a, 7b).

### 3. Hardness measurement (Table1, Fig1)

#### 1) 1 week after extraction

Hardness of the bone was  $13.07 \pm 2.64$  on control group, and  $23.27 \pm 3.88$  on test group.

There was a statistically significant difference between control and test group ( $p < 0.05$ ).

#### 2) 2 weeks after extraction

Hardness of the bone was  $11.53 \pm 2.68$  on control group, and  $24.60 \pm 1.74$  on test group.

There was a statistically significant difference between control and test group ( $p < 0.01$ ).

#### 3) 4 weeks after extraction

Hardness of the bone was  $34.83 \pm 4.88$  on control group, and  $62.93 \pm 6.53$  on test group.

There was a statistically significant difference between control and test group ( $p < 0.01$ ).

4) Hardness difference between 1 week and 2 weeks by time course

The result was  $-1.53 \pm 3.84$  on control group, and  $1.33 \pm 4.90$  on test group. There was not a statistically significant difference between control and test group ( $p > 0.05$ ).

5) Hardness difference between 1 week and 4 weeks by time course

The result was  $21.77 \pm 7.10$  on control group, and  $39.67 \pm 8.36$  on test group.

There was a statistically significant difference between control and test group ( $p < 0.05$ ).

#### IV. Discussion

The ultimate objective of periodontal therapy is complete reconstruction of previously destroyed periodontal tissue. As periodontitis is characterized by inflammation, classical nonsurgical treatment is scheduled to remove inflammation, while surgical treat-

ment is not only to remove inflammation, but also to remove and regenerate the injured area additively.

Regeneration implies a complete recomposition or rehabilitation of structure and function with vanished or injured periodontal tissue. Therefore regeneration of periodontal tissue includes the reformation of cementum, periodontal ligament, and alveolar bone. Bone formation occurs with three methods. They are endochondral bone formation, sutural bone formation, and intramembranous bone formation.

Endochondral bone formation is originated from pre-existing cartilage model, and this type includes the end of long-bone, ribs, mandibular condyle and cranial base. The mechanism is degeneration of primary ossification center in diaphysis, absorption of contiguous matrix, lacunae growth, calcium deposition, and infiltration of blood vessel via hole which is made by osteoclasts, and there osteogenitor cells intrude to differentiate into osteoblasts, then final formation of bone matrix. Bone development occurs as the result of the fusion of secondary ossification centers in the epiphysis.

Sutural bone formation, which is very important to development of skull and facial bone, is fibrous joint between bone and bone. This formation plays a role in keeping pace with developing organs as

Table 1. Knoop Hardness of Specimens between control and test groups by time course (kg/mm<sup>2</sup>)

Time(wks)	Groups	
	Control	Test
T1	$13.07 \pm 2.64$	$23.27 \pm 3.88$ *
T2	$11.53 \pm 2.68$	$24.60 \pm 1.74$ **
T4	$34.83 \pm 4.88$	$62.93 \pm 6.53$ **
D1(T2-T1)	$-1.53 \pm 3.84$	$1.33 \pm 4.95$
D2(T4-T1)	$21.77 \pm 7.10$	$39.67 \pm 8.36$

\*\* : Significant difference between two groups ( $p < 0.05$ ).

\*\* : Significant difference between two groups ( $p < 0.01$ ).

Each value represents mean and standard deviation.

T1, T2, T4 implies 1 week, 2 weeks, 4 weeks specimens.

D1(T2-T1) is time difference between 1 week and 2 weeks.

D2(T4-T1) is time difference between 1 week and 4 weeks.

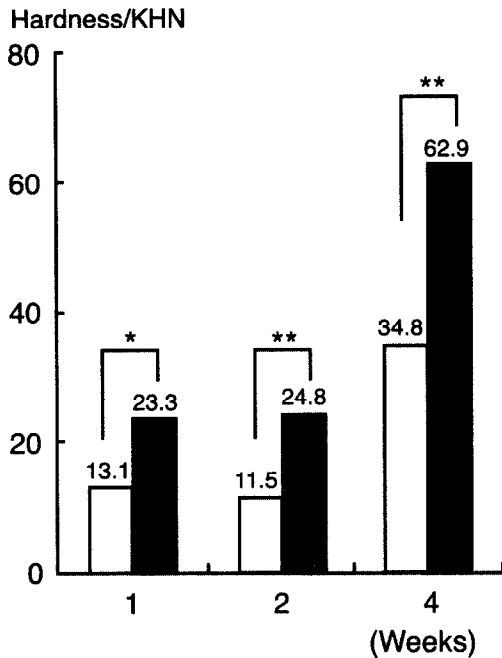


Figure 1a. Comparative study of knoop hardness between control and bisphosphonate treated groups.

KHN is Knoop Hardness Number (kg/mm<sup>2</sup>).

\* : Significant difference between two groups (p < 0.05).

\*\* : Significant difference between two groups (p < 0.01).

T1, T2, T4 implies 1 week, 2 weeks, 4 weeks specimens.

D1(T2-T1) is time difference between 1 week and 2 weeks.

D2(T4-T1) is time difference between 1 week and 4 weeks.

eyes, brain bones, by skull and facial bone.

Intramembranous bone formation originates from mesenchymal tissue, and this bone formation includes maxillary and mandibular bone developments. The mechanism is that several mesenchymal cells differentiate into osteoblasts, form osteoid, and mineralize to bony spicules. A greater number of bony spicules in the ossification center fuse to spongy structure at the same time. These ossification centers rapidly develop and fuse, then replace the original connective tissues. Extraction socket was a good model of intramembranous bone formation.

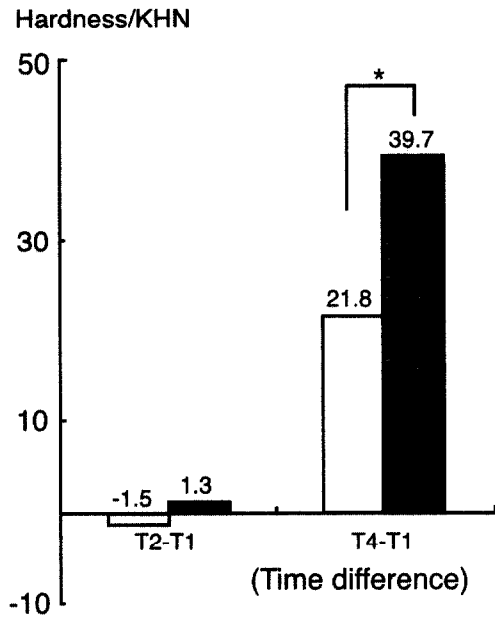


Figure 1b. Hardness Differences between test and control groups(1, 2, 4 weeks).

Extraction socket of rat is a good specimen of regeneration of destroyed tissue, where periodontal ligaments remain and vigorous granulation tissue formation take place and progress to bone formation<sup>23-24</sup>.

Some authors reported the healing process of extraction socket in rats<sup>23</sup>.

After extraction, socket was filled with blood coagulums and infiltration of fibroblasts to coagulations, fibroblasts form dense connective tissue and finally all extraction sockets were composed of nascent trabecular bones by various bone matrix and bone cells.

Bisphosphonates, inhibitors of bone resorption by osteoclasts, were introduced by Fleisch et al. in 1969<sup>1)</sup>, and have been used in the treatment of bone destruction disease such as Paget's disease, osteoporosis, tumoral bone disease, hypercalcemia of malignancy, osteogenesis imperfecta, and so on<sup>10~14)</sup>.

In the application of dentistry, though it is in an early stage, bisphosphonates are used for suppression of alveolar bone resorption by periodontitis, for decrease of alveolar bone resorption after mucoperiosteal flap surgery, for increase of bone formation rate and bone to implant contact in the regenerative treatment of periimplant defects, and for preventing the movement of anchorage tooth or relapse in the orthodontic treatment<sup>15~21)</sup>.

The action mechanism of bisphosphonates on bone resorption is not clearly elucidated, but many researches were reported that bisphosphonates inhibited the differentiation of osteoclasts<sup>1~8)</sup>. Murakami<sup>25, 26)</sup> et al. said that they inhibited the bone resorption by suppressing the action of the enzyme regulating the cytoskeletal-organization in osteoclasts (protein tyrosine phosphatase). Carano et al<sup>9)</sup>, reported that bisphosphonates had a direct effect on activity of the osteoclasts. Selander et al.<sup>27)</sup> and Hughes et al<sup>28)</sup>, said that bisphosphonates reduced the life of osteoclasts by programmed cell death (apoptosis). Luckman et al<sup>29)</sup>, and Beek et al.<sup>30, 31)</sup> said that nitrogen-containing bisphosphonates (ex. alendronate, olpadronate, residronate) inhibited the protein geranylgeranylation, which was important to osteoclast-mediated bone resorption, in mevalonate pathway of osteoclasts, and induced apoptosis or functional suppression of osteoclasts by inhibiting post-translational prenylation of GTP-binding protein. But non-nitrogen-containing bisphosphonates (ex. clodronate, etidronate) did not show the same effect as nitrogen-containing bisphosphonates. So we concluded that all bisphosphonate did not have

the same mechanism of inhibiting the osteoclastic activity, and they possess their own physicochemical and biological characteristics.

In addition to the fact that the bone resorption suppression of bisphosphonates is caused by direct effect on osteoclasts, there is a theory that bisphosphonate gives an indirect effect on osteoclasts by influencing osteoblasts.

Nishikawa et al<sup>8)</sup>, reported that bisphosphonates had an effect on osteoblasts by inhibiting the later stage of osteoclastogenesis. Vitte et al<sup>9)</sup>, said that bisphosphonates induced osteoclast-mediated resorption inhibiting factors.

We investigated, in this study, the effect of bisphosphonates on healing of the rat's extraction socket, and osteoclastic activity as the retardation factors in the living beings.

We used 1mg/kg concentration of Bisphosphonate. Many researchers had experimented with various concentrations of the drug and we concluded that 1mg/kg was an optimal concentration because that concentration was not toxic to the rat, and had negligible side effects. Thus we expected that various concentrations of bisphosphonates also should be necessary for broad and profound results.

We investigated the healing pattern of extraction sockets after extraction of maxillary first molars. In the 1 week groups after extraction, there was a similar aspect between control and test group, where blood clots disappeared from the center of extraction socket, and fibrous connective tissue was replaced by fibroblasts. Formation of trabecular pattern at the marginal bone area was partially shown. In the 2 week groups after extraction, extraction socket was healed by fibrous connective tissue, and significant decrease of inflammatory cells and prosperous formation of trabecular pattern at the marginal bone area were also shown in both groups. Gingival epithelium was almost healed.

In the 4 week groups, newly formed bone was seen in most of the extraction socket and active osteoblasts were shown mostly in the alveolar crest area. Osteocyte formation was also well observed. In the 4 week groups, there was no statistical significant difference between test and control group. It is suggested that the reason for these results was that the ossification had already progressed, so the influence of osteoclasts was negligible, thus the activity of osteoclasts by bisphosphonates did not decrease.

There was no significant difference, in the histologic study, between control and test groups during the 4 week-research period. The reason, we thought, was the difficulty of discriminating the differences in healing patterns in a short period with a small sample number. The healing potency of the rat was more excellent than other animals and human beings, and there might be individual variations in the control and test groups.

We thought, to solve this problem, longer term follow up test including many samples and more sufficient time with various histometric systems would be necessary.

In the TRAP findings, there was a similar aspect on the overall groups. But in the 2 week group, test group showed more reduced osteoclastic activity than control group. This phenomenon, we thought, was related to the fact that the influence of the bisphosphonates on osteoclasts was mainly expressed in 2 weeks.

On the other hand, there was a statistically significant result in measurement of hardness. We thought that histologic finding was a study confined to specific area and specific surface, while hardness study was related to overall healed extraction socket, and was a more broad area to estimate, so we could obtain more credible and satisfactory results. It was interesting to observe the change by time courses, there was no significant difference between control and test

groups in the 1 week and 2 weeks, but it was shown that there was significant difference between control and test groups in 1 week and 4 weeks. This result was, we thought, caused by the fact that the immature state of extraction sockets at 2 weeks, turned to ossification massively at 4 weeks. These findings are similar to those in the humerus of the rat with Motoie<sup>32)</sup>. But, in the 2 week groups, there was slight decrease of hardness, this is difficult to understand, so we considered that the sample size was too small and there might be individual variations.

We did not mention, in this study, the side effects of systemic application of bisphosphonates. Some authors<sup>33)</sup>, however, warned that there could be very harmful effects, if bisphosphonates were applied massively over a short term, especially in tooth structure, renal function, eyes, lung, liver, and etc. Therefore, it is dispensable to use optimal concentration of specimen, and to evolve a new method for the drug to locally apply at a specific area.

In conclusion, Bisphosphonates, were effective in promoting the healing process of rat's extraction socket, and increasing the hardness of cortical bone. It is necessary for us to research the effect of bisphosphonates in vivo and in vitro with sufficient samples and time, and also to investigate profoundly the side-effects of the systemic application of bisphosphonates.

We expect the precise mechanism of Bisphosphonates should be elucidated and new drug delivery methods, which would be optimal to human beings and confined to specific areas, should be developed for the future.

## V. Summary

The objective of this study was to evaluate the effect of bisphosphonates on the healing aspect of extraction sockets. Eighteen Sprague-Dawley rats

were used for this study, and  $\beta$ Aminopropionitrile (APN) 0.28g/kg · day soluted in mineral water was administrated for 5 days to extract easily and minimize injury.

To prevent infection, Ampicillin 1.5mg/kg was administrated after extraction in control and test groups. Bisphosphonate 1mg/kg was injected in the test groups and vehicle (0.9%saline) was injected in the control groups three times a week for 2 weeks subcutaneously. Three rats on each day were sacrificed at 1, 2, 4 weeks after extraction.

Histologic findings, and osteoclastic activity by tartrate resistant acid phosphatase (TRAP), and knoop hardness were observed.

The results were as follows :

1. The overall histologic healing pattern was similar with both the test and control group.
2. The activity of osteoclasts was similar with both test and control groups in 1, 4 weeks, but test group showed more reduced osteoclastic activity compared to control in 2 weeks group.
3. In the hardness test, there was significant difference in test groups than control groups in 1, 2, 4 weeks. Although, in the comparison of test and control groups, there was no significant difference between 1 week and 2 weeks groups, there was significant difference between 1 week and 4 weeks groups.

In conclusion, Bisphosphonate had an influence on the healing process of rat's extraction sockets, the activity of osteoclasts, and promoted the hardness of healed rat's extraciton sockets.

## VI. References

1. Fleisch H, Russel RGG, Bisaz S., Muhlbauer R C., Williams D A., : The inhibitory effect of phosphonates on the formation of calcium phosphonate crystals in vitro and aortic and kidney calcification in vivo. *Eur J Clin. Invest.* 1: 12-18; 1970
2. Fleisch H., : Bisphosphonates: Mechanisms of Action. *Endocrine Reviews* 19 : 80-100, 1998
3. Fleisch H., Vitte C., Guenther H. L.: Bisphosphonates induce osteoblasts to secrete an inhibitor of osteoclast-mediated resorption. *Endocrinology* 137 : 2324-2333, 1996
4. Porras A.G., Holland S.D., Gertz B.J. : Pharmacokinetics of Alendronate. *Clin,Pharmacokinet* 1999; 36; 315-328
5. Carano A., Teitelbaum S.L., John D. ,Konsek P. H, Blair H.C. : Bisphosphonates directly inhibit the bone resorption activity of isolated avian osteoclasts in vitro.: *J. Clin. Invest.* 1990 : 456-461
6. Hughes D. E., MacDonald B. R. ,Russel R,G,G., Gowen M. : Inhibition of osteoclast-like cell formation by bisphosphonates in long-term cultures of human bone marrow. *J. Clin. Invest.* 83. 1989, 1930-1935
7. Hughes D.E., Wright K.R., Harry L. U.Y, Sasaki A., Tonedá T., Rodman G. D., Mundy G.R., Boyce B.F. : Bisphosphonates promote Apoptosis in murine osteoclasts in vitro and in vivo. *J. Bone Miner Res* 1995; 10: 1478-1487
8. Selander K. S, Monkkonen J, Karhukorpi E. K, Harkonen P, Hannunimi R, Vananen H. K: Characteristics of clodronate-induced apoptosis in osceoclasts and macrophages , *Mol Pharmacol*, 50: 1227-1138, 1996
9. Nishikawa M. , Adatsu T., Katayama Y. , Yasutomo Y., Kado S.,Kugai N., Yamamoto M., Nagata N. : Bisphosphonates act on Osteoblastic cells and inhibit osteoclast formation in Mouse marroe cultures. *Bone* 18: 9-14; 1996
10. Vitte C., Fleisch H, Harald L., Guenther : Bisphosphonates induce osteoblasts to secrete



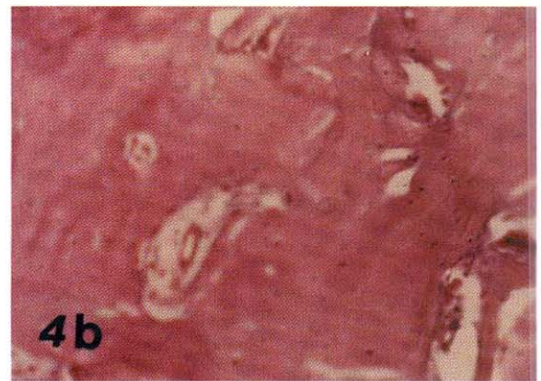
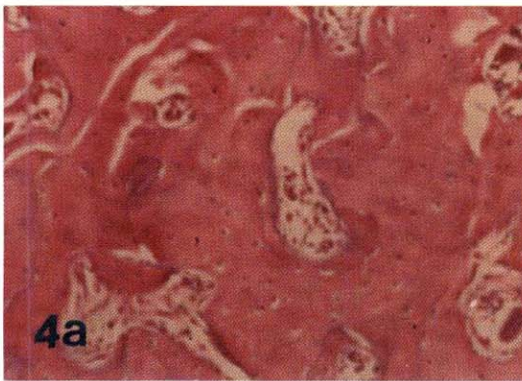
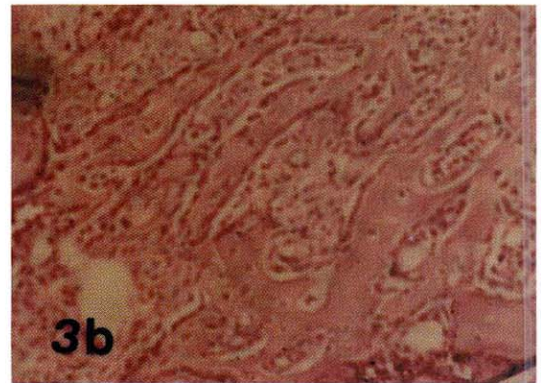
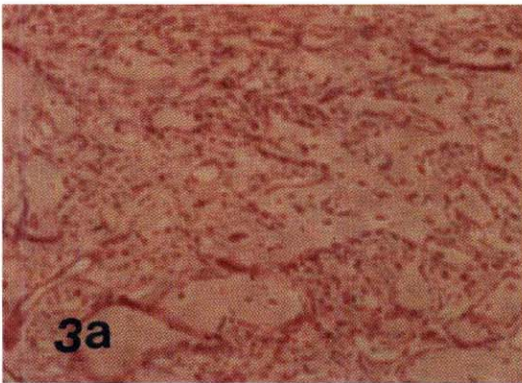
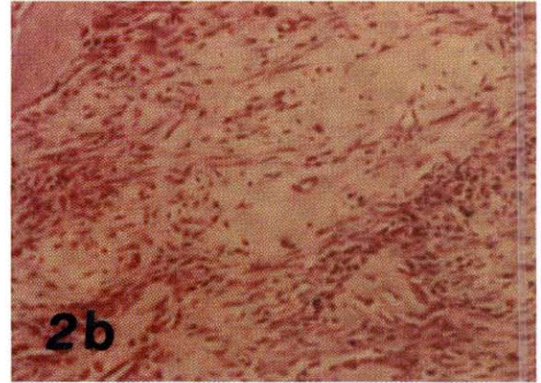
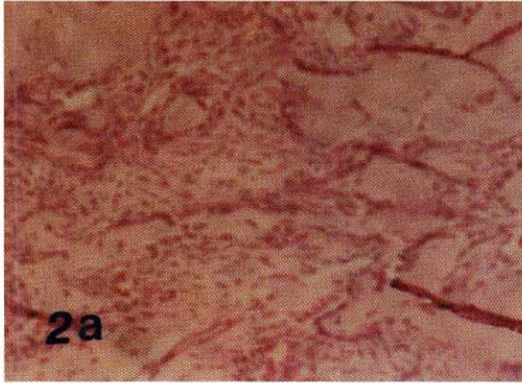
- an inhibitor of Osteoclast-mediated resorption. *Endocrinology* 137 : 2324-2333, 1996
11. Jeal W, Barradell LB, and McTavish D : Alendronate. A review of its pharmacological properties and therapeutic efficacy in postmenopausal osteoporosis. *Drugs* 1997 ; 53 :415-34
  12. Glorieux FH., Bishop NJ., Plotkin H., Chabot G., Lanoue G., Travers R. : Cyclic administration of pamidronate in children with severe osteogenesis imperfecta. *N Engl J Med* 1998;1: 339: 947-52
  13. Body J.J., Baril R., Burckhardt P., Delmas P.D., Diel I.J., Fleisch H., Kanis J.A., Mundy G.R., Paterson A.H., Rubens R.D., : Current use of bisphosphonates in oncology. *J. Clin. Oncol.* 1998; 16:3890-9
  14. Jung A. : Comparison of two parenteral diphosphonates in hypercalcemia of malignancy. *Am J Med* 72: 221-226, 1982
  15. Jiliang L.I., Satoshi M., Yoshio K., Tasuku M., Jun K., Hiromichi N., : Effect of bisphosphonate (incadronate) on fracture healing of long bones in rats. *J. Bone Miner Res* 1999; 14: 969-979
  16. Brunsvold M.A., Chaves E.S., Kornman K.M.S., Aufdemorte T. B., Wood R. : Effects of a bisphosphonate on experimental periodontitis in monkeys. *J. Periodontol.* 1992; 63: 825-830
  17. Yaffe A., Nachum F., Ido A., Iyzhak B., : The effect of bisphosphonate on alveolar bone resorption following mucoperiosteal flap surgery in the mandible of rats. *J. Periodontol.* 1995; 66: 999-1003
  18. Yaffe A., Iztzkovich M., Earon Y., I, Alt, R. Lilov, I. Binderman : Local delivery of an amino bisphosphonate prevents the resorptive phase of alveolar bone following mucoperiosteal flap surgery in rats. *J. Periodontol.* 1997; 68: 884-889
  19. Meraw S.J., Reeve C.M., Wollan P.C. . : Use of alendronate in peri-implant defect regeneration : *J. Periodontol.* 1999;70:151-158
  20. Adachi H., Igarashi K., Mitani H., Shinoda H., : Effects of topical administration of a bisphosphonate (risedronate) on orthodontic tooth movements in rats. *J Dent Res* 73: 1478-1484. 1994
  21. Kim T.W., Yoshida Y., Yokoya K., Sasaki T. : An ultrastructural study of the effects of bisphosphonate administration on osteoclastic bone resorption during relapse of experimentally moved rat molars. *Am J Orthod Dentofacial Orthop* 1999; 115: 645-53
  22. Tencate A. R. : *Oral histology : Development, Structure and Function* 4th edition 1994
  23. Guglielmotti M. B., Cabrini R. L. : Alveolar wound healing and ridge remodeling after tooth extraction in the rat. A histologic and radiographic and histometric study. *J Oral Maxillofac Surg* 43: 359-364, 1985
  24. Sahni M., Cuenther H. L., Fleisch H., Collin P., Martin T. J. : Bisphosphonates act on rat bone resorption through the mediation of osteoblasts. *J. Clin. Invest.* 1993; 91: 2004-2011
  25. Murakami H., Takahashi N., Tanaka S., Nakamura I., Udagawa N., Nakajo S., Nakaya K., Abe M., Yuda Y., Konno F., Barbier A., Suda T. : Tiludronate inhibits Protein Tyrosine Phosphatase activity in osteoclasts. *Bone* 20: 399-404; 1997.
  26. Murakami H, Hakahashi N., Sasaki T., Udagawa N., Tanaka S., Nakamura I., Zhang D., Barbier A., Soda T. : A possible mechanism of the specific action of bisphosphonates on osteoclasts : Tiludronate preferentially affects polarized osteoclasts having ruffled borders. *Bone* 17: 137-144; 1995.
  27. Selander K. S, Monkkonen J, Karhukorpi E. K, Harkonen P, Hannunimi R, Vananen H. K: Characteristics of clodronate-induced apoptosis in osteoclasts and macrophages , *Mol*

- Pharmacol, 50: 1227-1138, 1996.
28. Steven P. Luckman, David E. Hughes, Fraser P. Coxon, R. Graham G. Russell, Michael J. Rogers : Nitrogen-containing bisphosphonates inhibit the mevalonate pathway and prevent post-translational prenylation of GTP-binding proteins including ras. *J Bone Miner Res* 1998; 13: 581-589
  29. Steven P. Luckman, P. Coxon, Frank H. Ebetino, R. Graham G. Russell, Michael J. Rogers. : Heterocycle-containing bisphosphonates cause apoptosis and inhibit bone resorption by preventing protein prenylation: Evidence from structure-activity relationships in J774 Macrophages. *J Bone Miner Res* 1998; 13: 1668-1678.
  30. Beek E. V., Lowik C., Pluijm G. V. D., papapoulos S. : The role of geranylgeranylation in bone resorption and ints suppression by bisphosphonates in fetal bone explants in vitro : A clue to the mechanism of action of nitrogen-containing bisphosphonates. *J Bone Miner Res* 1999; 14: 722-729
  31. Beek E. V., Lowik C., Papapoulos S. E., : Effect of alendronate treatment on the osteoclastogenic potential of bone marrow cells in mice. *Bone* 20: 335-340. 1997
  32. Motoie H., Okazaki A, Kanoh H, Shikama H., Fujikura T. : Increase of bone mass and mechanical strength in rats after treatment with a novel bisphosphonate, YM175, for two years. *Pharmacology & Toxicology* 1997; 81. 42-47
  33. Adami S., Zamberlan N. : Adverse effects of bisphosphonates. A comparative review. *Drug Saf* 1996; 14: 158-70

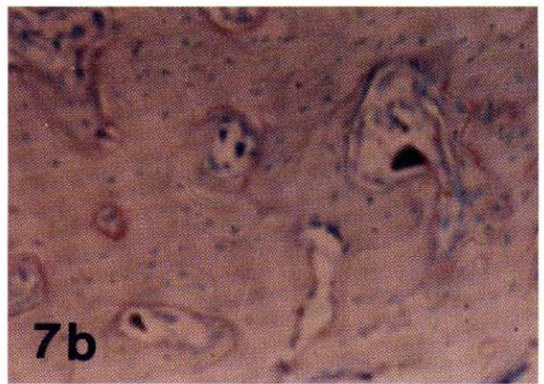
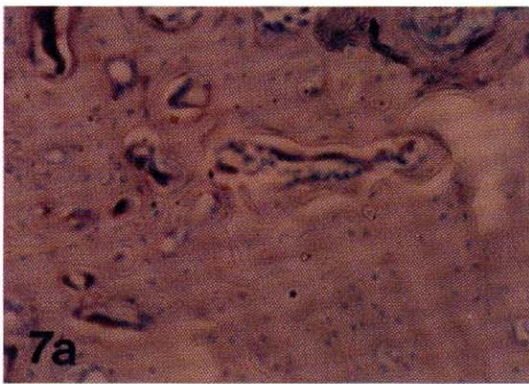
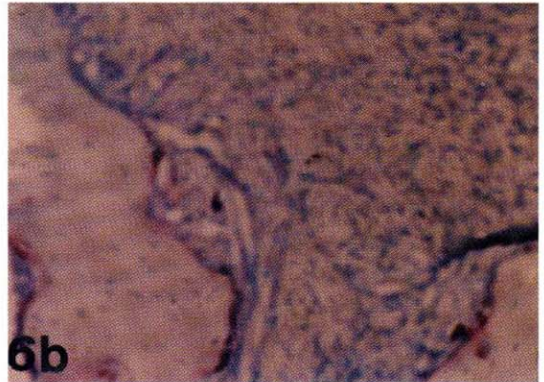
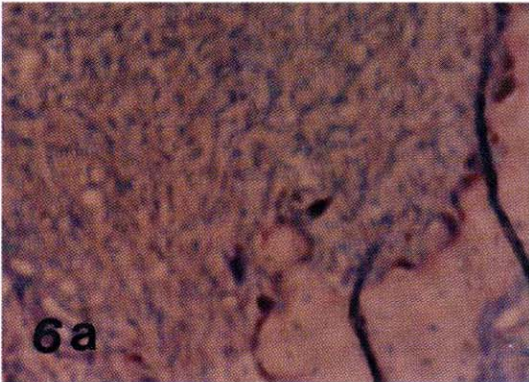
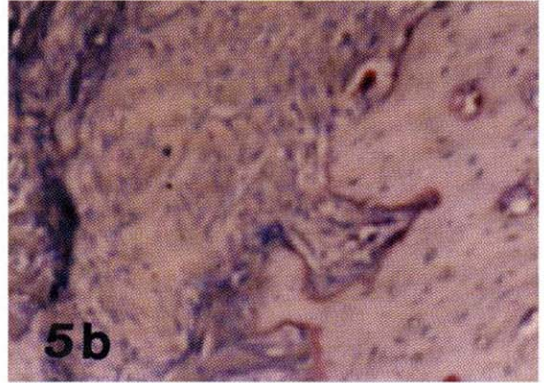
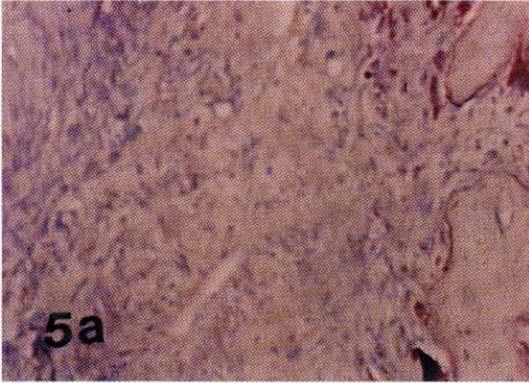
## 사진부도 설명

- Figure 2a, 2b Histologic findings (1 week after extraction)  
There was a similar healing aspect between test and control groups. Blood clots disappeared from the center of extraction socket, and fibrous connective tissues were replaced by fibroblasts. Formation of trabecular pattern in the marginal bone area was partially shown (H&E,  $\times 100$ ).
- Figure 3a, 3b Histologic findings (2 weeks after extraction)  
Extraction socket was healed by fibrous connective tissue, and significant decrease of inflammatory cells and active formation of trabecular pattern in the marginal bone area were shown, and gingival epithelium was almost healed (H&E,  $\times 100$ ).
- Figure 4a, 4b Histologic findings (4 weeks after extraction)  
New bone formation was shown in most of the extraction sockets. Active osteoblasts were shown mostly in the alveolar crest area. Epithelium was well keratinized above the extraction socket. Osteocyte formation was also well shown (H&E,  $\times 100$ ).
- Figure 5a, 5b Histologic findings (1 week after extraction)  
There was a similar osteoclastic activity aspect between control and test groups (TRAP,  $\times 100$ ).
- Figure 6a, 6b Histologic findings (2 weeks after extraction)  
In 2 weeks group, test group had reduced osteoclastic activity than control group (TRAP,  $\times 100$ ).
- Figure 7a, 7b Histologic findings (4 weeks after extraction)  
There was a similar osteoclastic activity aspect between control and test groups (TRAP,  $\times 100$ ).

사진부도 (I)



사진부도(II)



## 백서발치와의 치유과정에 Alendronate가 미치는 영향

문금기 · 이재목 · 서조영

경북대학교 치과대학 치주과학교실

Bisphosphonate가 백서 발치와의 치유과정에 미치는 영향에 대해 관찰하고자 생후 2개월 된 Sprague-Dawley계의 백서 18마리를 사용하여, 실험군과 대조군 모두 발치를 용이하게 하고 외상을 최소화 하기 위해 발치 전에 하루  $\beta$ -Aminopropionitrile(APN) 0.28g/kg 을 5일 간 투여한 후 발치하고, 감염방지를 위해 매일 1.5 mg/kg ampicillin을 3일 동안 근육주사 하였다.

실험군에서는 Bisphosphonate 1mg/kg을, 대조군에서는 vehicle(0.9%saline)을 1주에 3회씩 2주 동안 피하 주사하였으며, 각 군은 발치 후 1주, 2주, 4주 간격으로 3마리씩 희생시켜 H&E 염색에 의한 조직학적인 관찰, TRAP 염색에 의한 파골 세포의 활성화, 경도 측정기에 의한 경도 측정을 통해 다음과 같은 결과를 얻었다.

1. 각 주간의 전반적인 치유양상은 시간이 경과함에 따라 실험군과 대조군 공히 유사한 치조골 회복 양상을 보였다.
2. 파골 세포의 활성화는 1주, 4주 군에서는 실험군과 대조군에서 유사한 양상을 나타내었으나, 2주 군에서는 실험군에서 대조군에 비해 감소된 파골 세포 활성화 양상을 관찰 할 수 있었다.
3. 경도측정에서는 모든 군에서 대조군에 비해 실험군에서 유의성 있는 증가 양상을 보였으며, 시간경과에 따른 경도의 차이에서는 1주군과 4주군 간에서 대조군에 비해 실험군에서 통계학적으로 유의성 있는 증가 양상을 보였다.(p<0.05)

이상의 연구를 통해 Bisphosphonate가 백서 발치와의 치유과정과 파골 세포의 활성화에 영향을 미치며, 치유된 발치와의 경도를 증가시키는 것으로 나타났다.