

Role of Radiation Therapy for Stage III Thymoma

Ha Chung Chun, M.D. and Myung Za Lee, M.D.

Department of Therapeutic Radiology, Hanyang University College of Medicine

Purpose : To evaluate the effectiveness and tolerance of the postoperative radiation therapy for patients with Stage III thymoma and to define the optimal radiotherapeutic regimen

Materials and Methods : We retrospectively analyzed the records of 24 patients with Stage III thymoma who were referred for postoperative radiation therapy in our institution from June, 1987 to May, 1999. Surgical therapy consisted of total resection in one patient, subtotal resection in seventeen, and biopsy alone in six patients. Age of the patients was ranged from 20 to 62 years with mean age of 47 years. Male to female ratio was 14 to 10. Radiation therapy was delivered with linear accelerator producing either 6 MeV or 10 MeV photons. The irradiated volume included anterior mediastinum and known residual disease. The supraclavicular fossae were not irradiated. The delivered total dose was ranged from 30 to 56 Gy. One patient received 30 Gy and eighteen patients received minimum of 50 Gy. Follow up period was ranged from 12 months to 8 years with median follow up of 40 months.

Results : The overall local control rate for entire group of patients was 67% at 5 years. The cumulative local failure rates at one, three and five year were 18%, 28% and 33%, respectively. In patients treated with subtotal resection and biopsy alone, local control rate was 76% and 33%, respectively. The actuarial observed survival rate at 5 years was 57%, and actuarial adjusted survival at 5 years was 72%. The difference between 5 year survival rates for patients treated with subtotal resection and biopsy alone was not statistically significant (62% vs 30%).

Conclusion : We might conclude that postoperative radiation therapy was safe and effective treatment for patients with Stage III thymoma. Postoperative radiation therapy is recommended in cases where tumor margin is close or incomplete resection is accomplished.

Key Words : Thymoma, Radiation therapy

INTRODUCTION

Thymomas are rare anterior mediastinal tumors. The extent of intrathoracic disease at first presentation can range from well encapsulated tumors to extensive invasion of adjacent structures, with pleural and pericardial dissemination. When discussing prognosis, authors have divided thymomas into benign and malignant types. However, while some claim these types can be differentiated from each other by means of histologic criteria,¹⁾ others dispute this possibility.²⁾

Thus many authors have based the diagnosis of malignancy on the finding of macroscopic invasion of adjoining tissue at surgery, rather than on histologic findings.^{3, 4)}

Several reports avoid the terms benign and malignant altogether and differentiate instead between invasive and noninvasive thymomas.^{5, 6)} However, the group of invasive thymomas is still broad, ranging from limited pericapsular growth to disseminated pleural metastases, which suggests a need for further subdivision. In 1978, the first staging system for thymoma was introduced by Bergh et al who classified patients into three stages or groups according to extent of disease found at surgery and histologic examination of the surgical specimen.⁷⁾ This staging system has been recognized by others and is defined as follows: stage I, intact capsule or growth within the capsule; stage II, pericapsular growth into the mediastinal fat tissue; and stage III, invasive growth into the surrounding organs, intrathoracic metastases, or both.

The progress in the treatment of patients with Stage III thymoma has been slow. The conventional approach of surgery and postoperative radiotherapy has resulted in a 5-year survival rate of about 60% without a noticeable improvement

Submitted December 1, 2000 accepted February 14, 2001
Reprint requested to : Ha Chung Chun, M.D. Department of
Therapeutic Radiology, Hanyang University Hospital
Tel : 02)2290-8617, Fax : 02)2292-7735
E-mail : rthcchun@email.hanyang.ac.kr

over the past 20 years.⁸⁻¹¹⁾ Surgery alone for Stage I and surgery plus postoperative radiation therapy for Stage II disease have resulted in a 5-year survival rate of 95% and 80~85% respectively. However, approximately 45% of thymoma patients have tumor invading neighboring structures (pericardium, great vessels, or lung) or pleural or pericardial dissemination, making total surgical excision difficult or impossible.¹²⁾ Adjuvant radiation therapy has been advocated for these extensive tumors, although there is limited information in the literature about rates of local control and survival.¹³⁾

Therefore, a retrospective analysis of 24 patients was undertaken to ascertain the effectiveness of postoperative radiation therapy in the management of Stage III thymoma. Local control rate and actuarial 5-year survival rate are reported.

MATERIALS AND METHODS

We retrospectively analyzed the records of 26 patients with Stage III thymoma who were referred for postoperative radiation therapy in our institution from June, 1987 to May, 1999. In two patients, the diagnosis was subsequently reclassified, one as germ cell tumor and one as diffuse large cell lymphoma. The remaining 24 patients constitute our study population. Surgical therapy consisted of total resection in one patient (tumor invading pericardium), subtotal resection in seventeen, and biopsy alone in six patients. The cell types of tumors in the 24 patients was as follows: 10 lymphocytic, 6 epithelial, 4 mixed lymphoepithelial, and 4 spindle cell tumors, respectively. All patients had Stage III disease as defined by Bergh et al.

Age of the patients was ranged from 20 to 62 years with mean age of 47 years. Male to female ratio was 14 to 10. The tumor was detected on routine chest radiographs in 4 asymptomatic patients. As shown in Table 1, cough, chest

pain, dyspnea, hoarseness, myasthenia gravis, sore throat, weight loss and dysphagia were presenting symptoms in decreasing order in remaining 20 patients. All patients underwent chest radiography and computed tomography before surgery. As mentioned above, one patient underwent total resection, 17 patients did subtotal resection and remaining 6 patients did biopsy alone, respectively.

Radiation therapy was delivered with linear accelerator producing either 6 MeV or 10 MeV photons. Parallel opposed anteroposterior fields, single anterior and two posterior oblique fields, a pair of anterior wedge fields, or a combination of these techniques were used. The irradiated volume included anterior mediastinum and known residual disease. The supraclavicular fossae were not irradiated. Treatment was given once a day, five times a week. Daily fraction was 1.8 or 2.0 Gy. The delivered total dose was ranged from 30 to 56 Gy. Table 2. showed the distribution of patients according to delivered dose. One patient received 30 Gy and 18 patients received minimum of 50 Gy.

All of the patients were followed by us or their referring physicians. Follow up period was ranged from 12 months to 8 years with median follow up of 40 months. Survival was calculated from day one of radiotherapy. After radiation therapy, local control was assessed by means of chest radiographs at frequent intervals, with the use of computed tomography reserved for patients with clinical findings suggestive of recurrence and negative radiography result. Chi square test was used for statistical comparison.

RESULTS

1. Local control

The overall local control rate for entire group of patients was 67% at 5 years. Fig. 1. showed the cumulative local

Table 1. Presenting Symptoms at Diagnosis

Symptom	Number of Patients
Cough	8
Chest Pain or Discomfort	7
Dyspnea	4
Hoarseness	3
Myasthenia Gravis	2
Sore Throat	1
Weight Loss	1
Dysphagia	1

Table 2. Distribution of Patients according to Delivered Radiation Dose

Dose	Number of Patients
<30 Gy	1
30~35 Gy	0
35~40 Gy	1
40~45 Gy	1
45~50 Gy	3
50~55 Gy	16
>55 Gy	2
Total	24

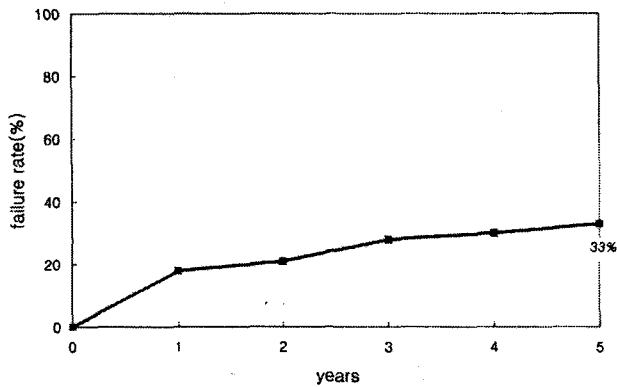


Fig. 1. Cumulative local failure rate for entire group of patients.

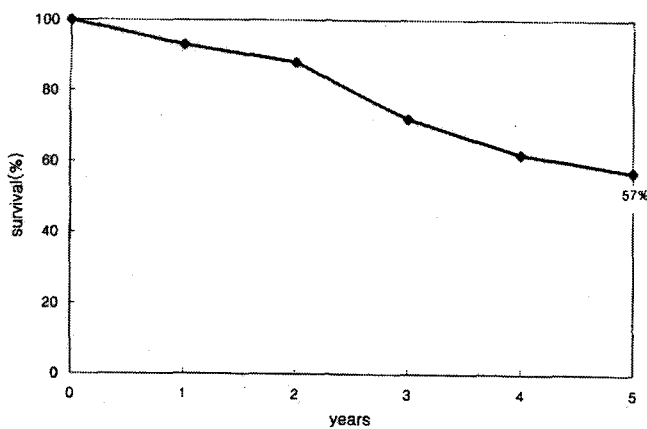


Fig. 2. Actuarial survival rate for entire group of patients.

failure rate for Stage III thymoma patients treated with post-operative radiotherapy. The cumulative local failure rates at one, three and five year were 18%, 28% and 33%, respectively. Local control was achieved in one patient treated with total resection. In patients treated with subtotal resection and biopsy alone, local control rate was 76% (13/17) and 33% (2/6), respectively.

2. Survival

The actuarial observed survival rate at 5 years was 57%, and actuarial adjusted survival at 5 years was 72%. The difference between observed and adjusted survival was resulted from 3 patients who died of intercurrent disease with no evidence of thymoma within 5 years after initiation of the radiation therapy. Fig. 2. showed actuarial survival rate for entire group of the patients. One patient treated with total resection is alive in 6 years following treatment without evidence of disease. The difference between 5-year actuarial

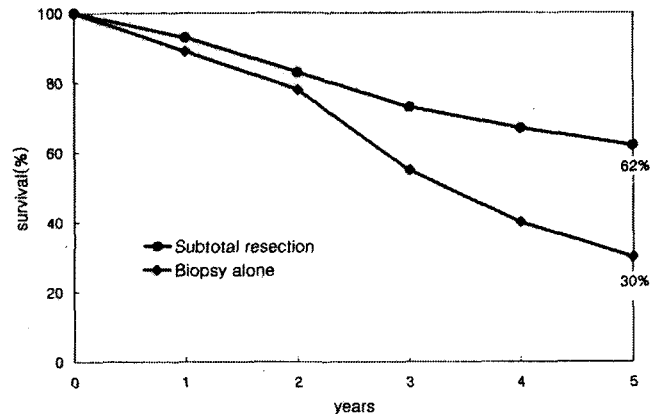


Fig. 3. Actuarial survival rates according to type of surgery.

survival rates for patients treated with subtotal resection and biopsy alone was not statistically significant (62% vs 30%, Fig. 3). This was probably due to small number of patients in each group. One patient developed distant lung metastasis 4 years after treatment and he is currently on combination chemotherapy and alive with disease.

3. Complications

During treatment, five patients developed esophagitis that resolved afterwards. Four had mild esophagitis, experienced as a lump in the throat upon swallowing. The fifth patient had dysphagia with solid foods, severe enough to require a 2-week cessation of treatment. No patient required placement of a nasogastric or gastroduodenal feeding tube. Possible long term sequelae such as pneumonitis, myelopathy, mediastinitis, pericarditis, or myocarditis did not develop in any patient.

DISCUSSION

The conventional approach for clinically suspected thymoma has been surgical exploration of the anterior mediastinum with an aim for a complete resection whenever feasible.^{8, 9, 14~16} However, a significant proportion of patients with clinically suspected Stage III thymoma have tumor invasion into the adjacent vital structures, and complete resection with clear margins may not be attainable.^{12, 13, 15~17} Blumberg et al reported that 44% of their patients with Stage III thymoma were found to be unresectable at initial presentation.^{9, 18} In that series, complete resection was not achieved in 40% of patients who were subjected to definitive surgery on the basis of clinical and radiographic studies.

Masaoka et al investigated the results of treatment in patients with thymoma who did not receive postoperative radiation therapy.¹⁹⁾ Of three patients who underwent subtotal resection and two who underwent biopsy alone, three died of thymoma less than 2 years after surgery, one had multiple lung metastases and the other was alive with persistent tumor. Clearly, the series of Masaoka et al indicates that patients with residual disease after surgery will do poorly without an effective postoperative treatment.

Several reports recommended radiation doses ranging from 40 to 60 Gy for postoperative radiotherapy.^{13, 17)} Our patients received doses between 30 and 56 Gy. One patient received 30 Gy and he was never free of disease. Eighteen of our patients received at least 50 Gy. Because all of the patients who received at least 50 Gy tolerated this dose without long-term sequelae and because local control was achieved in the majority despite extensive tumor, we recommend that 50 Gy delivered with conventional fractionation should be used in the postoperative treatment of thymoma. However, patients treated with biopsy alone and radiotherapy showed relatively poor result in our study. Thus we could try to escalate radiation dose for patients treated with biopsy alone although there is no firm data to support definite dose response correlation in thymoma management.

Thymoma spreads by direct extension from the anterior to the posterior mediastinum. All of our patients who did not achieve local control had recurrence in the anterior mediastinum. Therefore, we recommend that the initial treatment field encompass the anterior and posterior mediastinum and any residual more lateral tumor. Some authors have recommended treating both supraclavicular fossae to prevent dissemination to the lower neck.^{3, 20)} The supraclavicular fossae were not irradiated in any of our patients. One patient developed cervical node involvement, but this was concurrent with metastases to the liver. Therefore, we do not have any data to indicate that elective supraclavicular irradiation is warranted.

Local control rate was correlated with extent of surgical resection in our study. Local control was achieved in only 33% of the patients who underwent biopsy alone, compared with 76% and 100% treated with subtotal and total resection, respectively. These results suggest that patients with extensive disease whose tumor cannot be totally resected may get benefit from surgical debulking before radiation therapy.

Because none of patients in our study received chemo-

therapy during the postoperative period, we cannot draw any conclusion about the usefulness of chemotherapy. Others, however, report a role of chemotherapy in the treatment of patients with extensive disease. In review of the literature, Hu and Levine noted platinum based chemotherapy to be the most active agents in the treatment of thymoma.²¹⁾

Because of the rarity of thymoma, there is limited information about the results of postoperative radiation therapy in patients with extensive disease. Our findings of actuarial survival rate is comparable with previously reported series.^{17, 18, 22, 23)} Also our local control rate of 67% is similar to those of 55% and 60% reported by Nordstrom et al and Kersh et al, respectively.^{22, 23)} Because treatment failure more than 5 year after radiation therapy for thymoma is not uncommon and our minimum follow up is 12 months, we expect that the eventual local control rate in our series will be somewhat lower than 67%.

Based on our results, we might conclude that postoperative radiation therapy for Stage III thymoma is safe and effective treatment. Postoperative radiation therapy is recommended in cases where tumor margin is close or incomplete resection is accomplished

CONCLUSION

We conclude that postoperative radiation therapy is safe and effective treatment for Stage III thymoma. Postoperative radiation therapy is recommended in cases where tumor margin is close or incomplete resection is accomplished.

REFERENCES

1. Jain U, Frable WJ. Thymoma: analysis of benign and malignant criteria. *J Thorac Cardiovasc Surg* 1974;67:310-321
2. Lattes R. Thymoma and other tumors of the thymus: an analysis of 107 cases. *Cancer* 1962;15:1224-1260
3. Batata MA, Martini N, Huvos AG, et al. Thymomas: clinicopathologic features, therapy, and prognosis. *Cancer* 1974; 34:389-396
4. Gerein AN, Srivastava SP, Burgess J. Thymoma: a ten year review. *Am J Surg* 1978;136:49-52
5. Arriagada R, Bretel JJ, Caillaud J, et al. Invasive carcinoma of the thymus: a multicenter retrospective review of 56 cases. *Eur J Cancer Clin Oncol* 1984;20:69-74
6. Maggi G, Giaccone G, Donadio M, et al. Thymomas: a review of 169 cases with particular reference to results of surgical treatment. *Cancer* 1986;58:765-776

7. Bergh NP, Gatzinsky P, Larsson S, et al. Tumors of the thymus and thymic region. I. Clinicopathological studies on thymomas. Ann Thorac Surg 1978;25:91-98

8. Wilkins EW, Grillo HC, Scannell G, et al. Role of staging in prognosis and management of thymoma. Ann Thorac Surg 1991;51:888-892

9. Blumberg D, Port JL, Weksler B, et al. Thymoma: A multivariate analysis of factors predicting survival. Ann Thorac Surg 1995;60:908-914

10. Curran WJ, Kornstein MJ, Brooks JJ, et al. Invasive thymoma: The role of mediastinal irradiation following complete or incomplete surgical resection. J Clin Oncol 1988;6:1722-1727

11. Ciernik IF, Meier U, Lutolf UM. Prognostic factors and outcome of incompletely resected invasive thymoma following radiation therapy. J Clin Oncol 1994;2:484-490

12. Yagi K, Hirata T, Fukuse T, et al. Surgical treatment for invasive thymoma, especially when the superior vena cava is invaded. Ann Thorac Surg 1996;61:521-524

13. Nakahara K, Ohno K, Hashimoto J, et al. Thymoma: Results with complete resection and adjuvant postoperative irradiation in 141 consecutive patients. Thorac Cardiovasc Surg 1988;95:1041-1047

14. Okumura M, Miyoshi S, Takeuchi Y, et al. Results of surgical treatment of thymomas with special reference to the involved organs. J Thorac Cardiovasc Surg 1999;117:605-613

15. Shamji F, Pearson FG, Todd TRJ, et al. Results of surgical treatment for thymoma. J Thorac Cardiovasc Surg 1984;87:43-47

16. Cowen D, Richaud P, Mornex F, et al. Thymoma: Results of a multicenter retrospective series of 149 non-metastatic irradiated patients and review of the literature. Radiother Oncol 1995;34:9-16

17. Mornex F, Resbeut M, Richaud P, et al. Radiotherapy and chemotherapy for invasive thymomas: A multicenter retrospective review of 90 cases. Int J Radiat Oncol Biol Phys 1995;32:651-659

18. Urgesi A, Monetti U, Rossi G, et al. Role of radiation therapy in locally advanced thymoma. Radiother Oncol 1990;19:273-280

19. Masaoka A, Monden Y, Nakahara K, et al. Follow-up study of thymomas with special reference to their clinical stages. Cancer 1981;48:2485-2492

20. Arriagada R, Gerard-Marchant R, Tubiana M, et al. Radiation therapy in the management of malignant thymic tumors. Acta Radiol 1981;20:167-172

21. Hu E, Levine J. Chemotherapy of malignant thymoma: case report and review of the literature. Cancer 1986;57:1101-1104

국문 초록

제 3기 흉선종에서 방사선치료의 역할

한양대학교 의과대학 치료방사선과학교실

전 하 정 · 이 명 자

목적 : 제 3기 흉선종에서 수술후 방사선치료의 효과를 평가하고 최적의 방사선 치료 방법을 알아보고자 함이 본 연구의 목적이다.

대상 및 방법 : 1987년 6월부터 1999년 5월까지 본원에서 제 3기 흉선종으로 진단받고 수술후 방사선치료를 시행한 24명의 환자를 후향적으로 분석하였다. 1명은 완전 절제술을 시행받았고 17명은 불완전 절제술을 나머지 6명은 조직검사만을 시행받았다. 환자의 나이는 20세부터 62세의 분포를 나타내었고 평균연령은 47세였다. 남녀의 성비는 14 대 10였다. 6 또는 10 MeV 리니악을 이용하여 방사선치료를 시행하였고 증격동 및 알려진 잔여병변부위를 조사하였다. 쇄골하 림프절은 조사에 포함되지 않았다. 조사된 총 방사선 양은 30 내지 56 Gy였으며 한명만이 30 Gy를 조사 받았고 18명은 최소한 50 Gy이상을 조사 받았다. 추적기간은 12개월 내지 8년이었고 중앙값은 40개월였다.

결과 : 전체 환자에서 전반적인 국소제어율은 5년에 67%였다. 1년, 3년 및 5년 국소제어율은 각각 18%, 28% 및 33%였다. 불완전 절제술 및 조직검사만을 시행받은 환자에서 국소제어율은 각각 76% 및 33%였다. 5년 생존율은 관찰치가 57%, 조정치가 72%였다. 불완전 절제술을 시행받은 환자와 조직검사만을 시행받은 환자의 5년 생존율은 각각 62%와 30%였으나 통계적으로 유의하지는 않았다.

결론 : 제 3기 흉선종환자에서 수술 후 방사선치료는 안전하고 효과적인 치료방법이라 사료된다. 수술시 절제면제가깝거나 특히 불완전 절제를 시행받은 환자에서 수술 후 방사선치료가 도움을 주리라 생각된다

핵심용어 : 흉선종, 방사선치료