

Achilles

Abstract

One-Stage Achilles Tendon Reconstruction Using the Free Composite Dorsalis Pedis Flap in Complex Wound

**Sug Won Kim, M.D., Won Jai Lee, M.D., Dong Wan Seo, M.D.,
Yoon Kyu Chung, M.D., and Kwan Chul Tark, M.D.**

Department of Plastic and Reconstructive Surgery, Yonsei University Wonju College of Medicine

The soft tissue defects including the Achilles tendon are complex and very difficult to reconstruct. Recently, several free composite flaps including the tendon have been used to reconstruct large defects in this area in an one-stage effort. Our case presents a patient reconstructed with free composite dorsalis pedis flap along with the extensor digitorum longus and superficial peroneal nerve for extensive defects of the Achilles tendon and surrounding soft tissue. A 36-year-old-man sustained an open injury to the Achilles tendon. He was referred to our department with gross infection of the wound and complete rupture of the tendon associated with loss of skin following reduction of distal tibial bone fracture. After extensive debridement, 6 × 8cm of skin loss and 8cm of tendon defect was noted. Corresponding to the size of the defect, the composite dorsalis pedis flap was raised as a neurosensory unit including the extensor digitorum longus to provide tendon repair and sensate skin for an one-stage reconstruction. One tendon slip was sutured to the soleus musculotendinous portion, the other two were sutured to the gastrocnemius musculotendinous portion with 2-0 Prolene. The superficial peroneal nerve was then coaptated to the medial sural cutaneous nerve. The anterior tibial artery and vein were anastomosed to the posterior tibial artery and accompanying vein in an end to end fashion. After 12 months of follow-up, 5 degrees of dorsiflexion due to the checkrein deformity and 58 degrees of plantar flexion was achieved. The patient was able to walk without crutches. Two-point discrimination and moving two-point discrimination were more than 16mm at the transferred flap site. The donor site healed uneventfully. Of the various free composite flaps for the Achilles tendon reconstruction when skin coverage is also needed, we recommend the composite dorsalis pedis flap. The advantages such as to control infection, adequate restoration of ankle contour for normal foot wear, transfer of the long tendinous portion, and protective sensation makes this flap our first choice for reconstruction of soft tissue defect including the Achilles tendon.

Key Words : Achilles tendon reconstruction, Composite dorsalis pedis flap

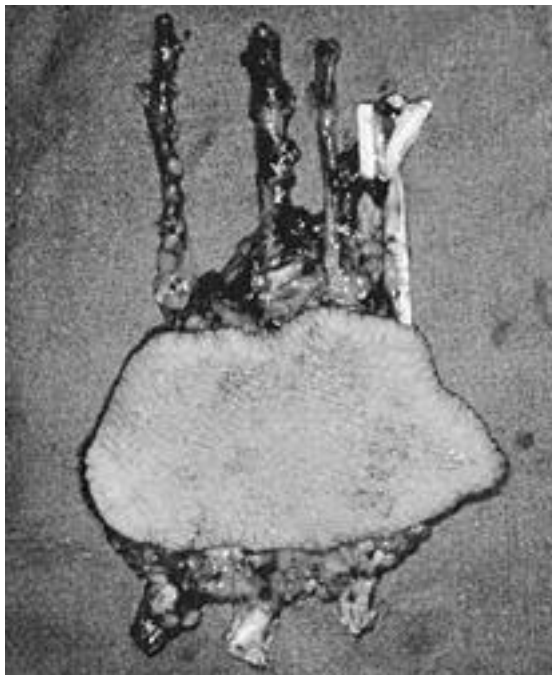


Fig. 3. Elevation of the free composite Dorsalis Pedis Flap.

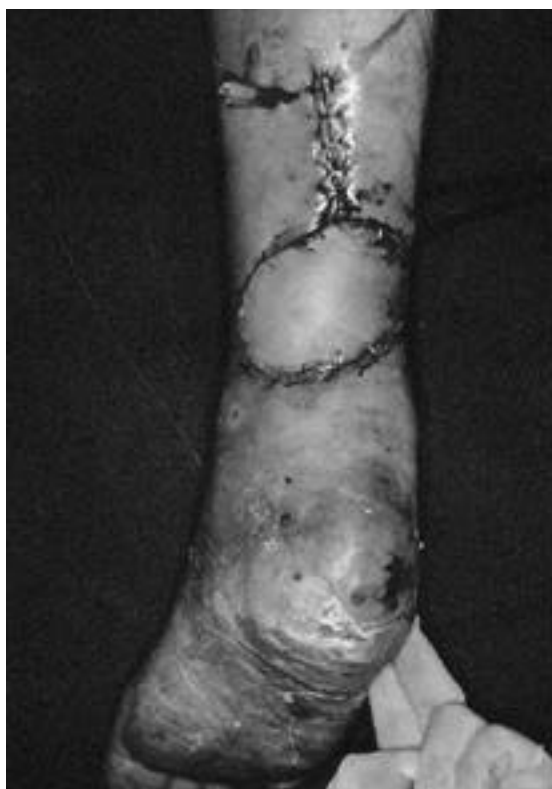

Fig. 4. Immediate postoperative view.

8cm , 6×8cm
 Achilles
 2,
 3, 4
 (Fig. 2, 3).
 가 (soleus
 muscle)
 (gastrocnemius muscle)
 prolene #2-0
 Achilles
 (saphenous nerve)
 #10-0 nylon
 (Fig. 4).

, 2 10
 , 30 anterior
 above knee splint
 , 4
 splint (immobi-
 lization) 6 , 8
 가 3
 1 가
 가
 (Fig. 5).

(plantar flexion) 55 (:0~58)
 (dorsiflexion) checklein deformity
 5
 (Fig. 6, 7).
 6 12 (high-
 resolution ultrasonography)
 Achilles
 (Fig. 8), two-point discrimination

moving two-point discrimination 16mm

Achilles

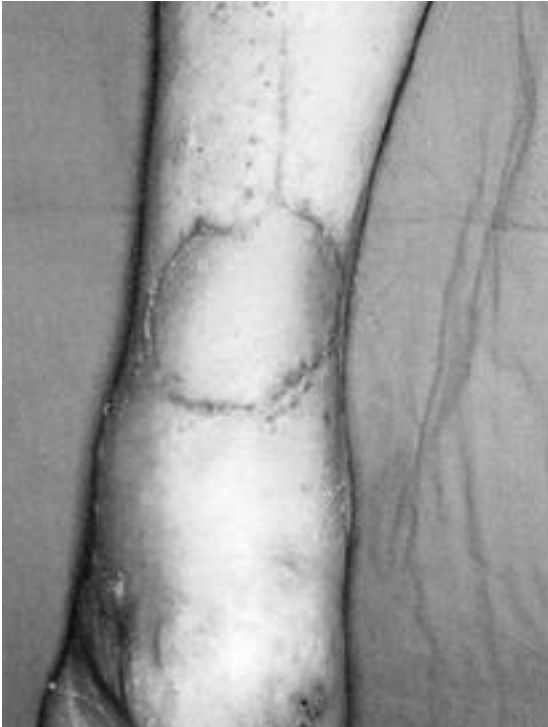

Fig. 5. Postoperative view after one year of surgery.

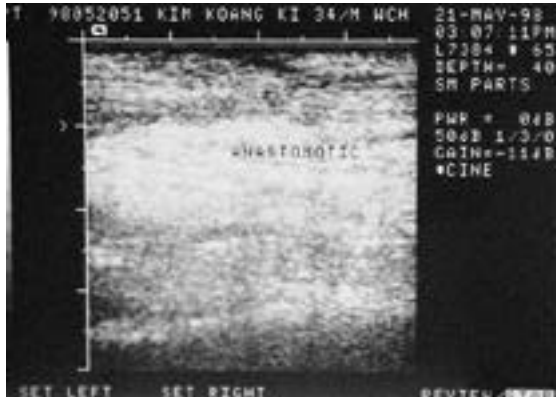


Fig. 8. High-resolution ultrasonography shows the continuity of Achilles tendon.

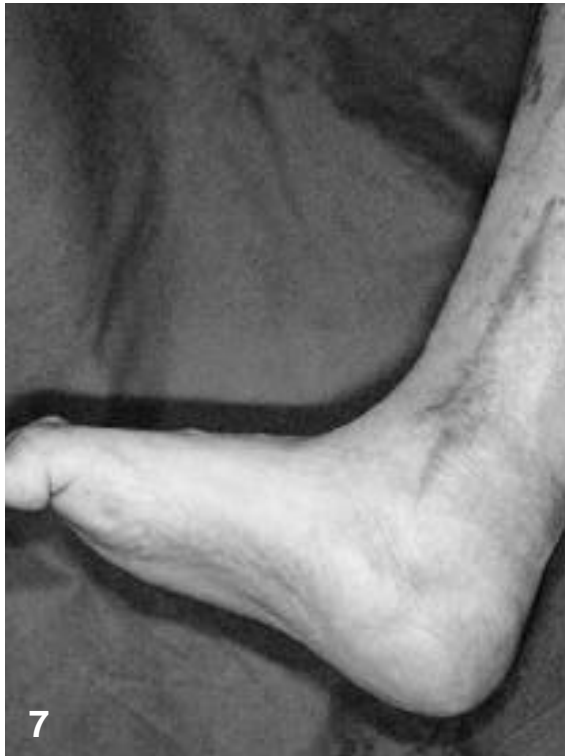
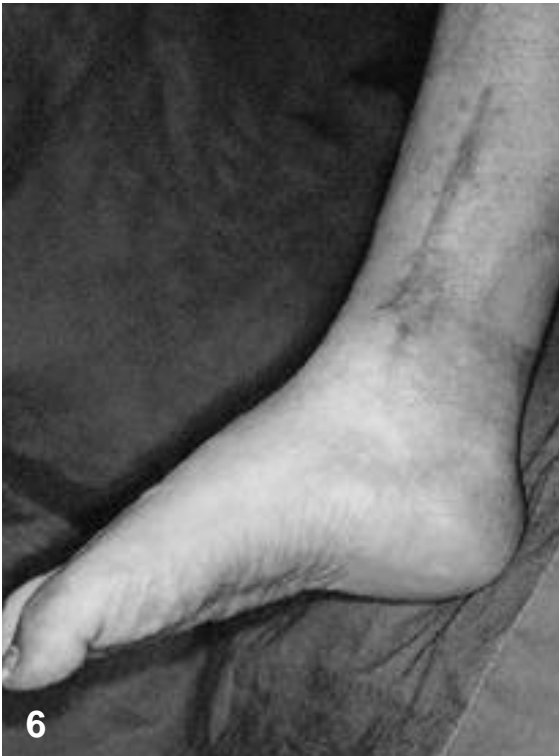
Fig. 6, 7. Dorsiflexion and plantar flexion was achieved.

Achilles

가

Fumarola¹⁾ O'Brien

tensor fascia lata 가

fascio-aponeurotic flap

turn-down

morbidity가

Achilles

Babu¹⁰⁾ 가

(lateral tarsal artery)

(extensor digitorum

2-7) 가

brevis)

(island flap)

6cm tunnel

Achilles 가

(one-stage) Wei (extensor

³⁾ external oblique fascia digitorum longus tendon)

Achilles

Achilles free iliac osteocutaneous flap 가

Inoue⁴⁾ vascularised fascia lata

free lateral thigh flap , Isenberg Fus⁵⁾

radial forearm-palmaris longus composite Achilles

free flap , Nelson Dobke⁶⁾

extended temporoparietal-galeal flap 3

two-point discrimination 1

16mm (protective

Berthe⁷⁾ sensation)

lateral arm flap

triceps tendon 가

Lee⁸⁾

가 Achilles

Achilles
가

가

Achilles

REFERENCES

- 1) Fumarola, A : *A one-stage reconstruction of a large defect of the tendo Achilles and the overlying skin. Br. J. Plast. Surg. 38: 403, 1985.*
- 2) Taylor, G. I., and Townsend, P : *Composite free flap and tendon transfer: an anatomical study and a clinical technique. Br. J. Plast. Surg. 32: 170, 1979.*
- 3) Wei, F., Chen, H., Chuang, C., and Noordhoff, M. S : *Reconstruction of Achilles tendon and calcaneus defects with skin-aponeurosis-bone composite free tissue from the groin region. Plast. Reconstr. Surg. 81: 579, 1988.*
- 4) Inoue, T., Tanaka, I., Imai, K., and Hatoko, M : *Reconstruction of Achilles tendon using vascularized fascia lata with free lateral thigh flap. Br. J. Plast. Surg. 43: 728, 1990.*
- 5) Isenberg, J. S., and Fusi, S : *Immediate tendon Achilles reconstruction with composite palmaris longus grafts. Ann. Plast. Surg. 34: 209, 1995.*
- 6) Nelson, J. M., and Dobke, M. K : *Achilles tendon reconstruction with the extended temporoparietal-galeal flap. Worldplast. 1: 129, 1995.*
- 7) Berthe, J. V., Toussaint, D., Coessens, B-C : *One-stage reconstruction of an infected skin and Achilles tendon defect with a composite distally planned lateral arm flap. Plast. Reconstr. Surg. 102: 1618, 1998.*
- 8) Lee, H-B., Lew, D-H., Oh, S-H., Tark, K-C., Kim, S-W., Chung, Y-K., and Lee, Y-H : *Simultaneous reconstruction of the Achilles tendon and soft-tissue defect using only a latissimus dorsi muscle free flap. Plast. Reconstr. Surg. 104: 111, 1999.*
- 9) O'Brien, B. M., and Shanmugam, M : *Experimental transfer of composite free flaps with microvascular anastomoses. Aust. N. Z. J. Surg. 43: 285, 1973.*
- 10) Babu, V., Chittaranjan, S., Abraham, G., and Korula, R.J : *Single-stage reconstruction of soft-tissue defects including the Achilles tendon using the dorsalis pedis arterialized flap along with the extensor digitorum brevis as bridge graft. Plast. Reconstr. Surg. 93: 1090, 1994.*