

# 중뇌종양에 의한 적핵진전에 대한 Vim 시상핵절제술\*

- 증례 보고 -

가  
손병철 · 김문찬 · 류경식 · 강준기

= Abstract =

## Vim Thalamotomy for Intractable Rubral Tremor Associated with Midbrain Tumor - Case Report -

Byung-Chul Son, M.D., Moon-Chan Kim, M.D.,  
Kyung-Sik Ryu, M.D., Joon-Ki Kang, M.D.

Department of Neurosurgery, Kangnam St. Mary's Hospital The Catholic University of Korea,  
Seoul, Korea

This 26-year-old man gradually developed a disabling midbrain tremor involving both distal and proximal part of left upper arm. On neurologic examination, oculomotor palsy, and ataxia of the left arm were noted. Radiologic examination revealed a mass lesion on midbrain tegmentum. He was tentatively diagnosed as brain tumor (presumably germinoma) without stereotactic biopsy. Conventional radiation therapy was given for this lesion. Although there was improvement in the radiologic imaging, his midbrain tremor worsened and became intolerable. The authors performed MR-guided stereotactic Vim-thalamotomy. With macroelectrode stimulation and radiofrequency lesioning, his resting, postural and action tremors were almost completely abolished in both distal and proximal part of left upper extremity. Authors consider that Vim thalamotomy is still an effective means of controlling midbrain tremor involving proximal upper limb.

**KEY WORDS :** Rubral tremor · Vim thalamotomy · Midbrain tremor.

서론 (cerebelloolvary tract), (nig-rostriatal tract)

(Rubral tremor) 2~5Hz (rest), (postural), (kinetic) (red nucleus)

(midbrain) Vim (ventral intermediate nucleus) (deep brain)

(cerebellothalamic tract), stimulation) (golbus pallidus interna)

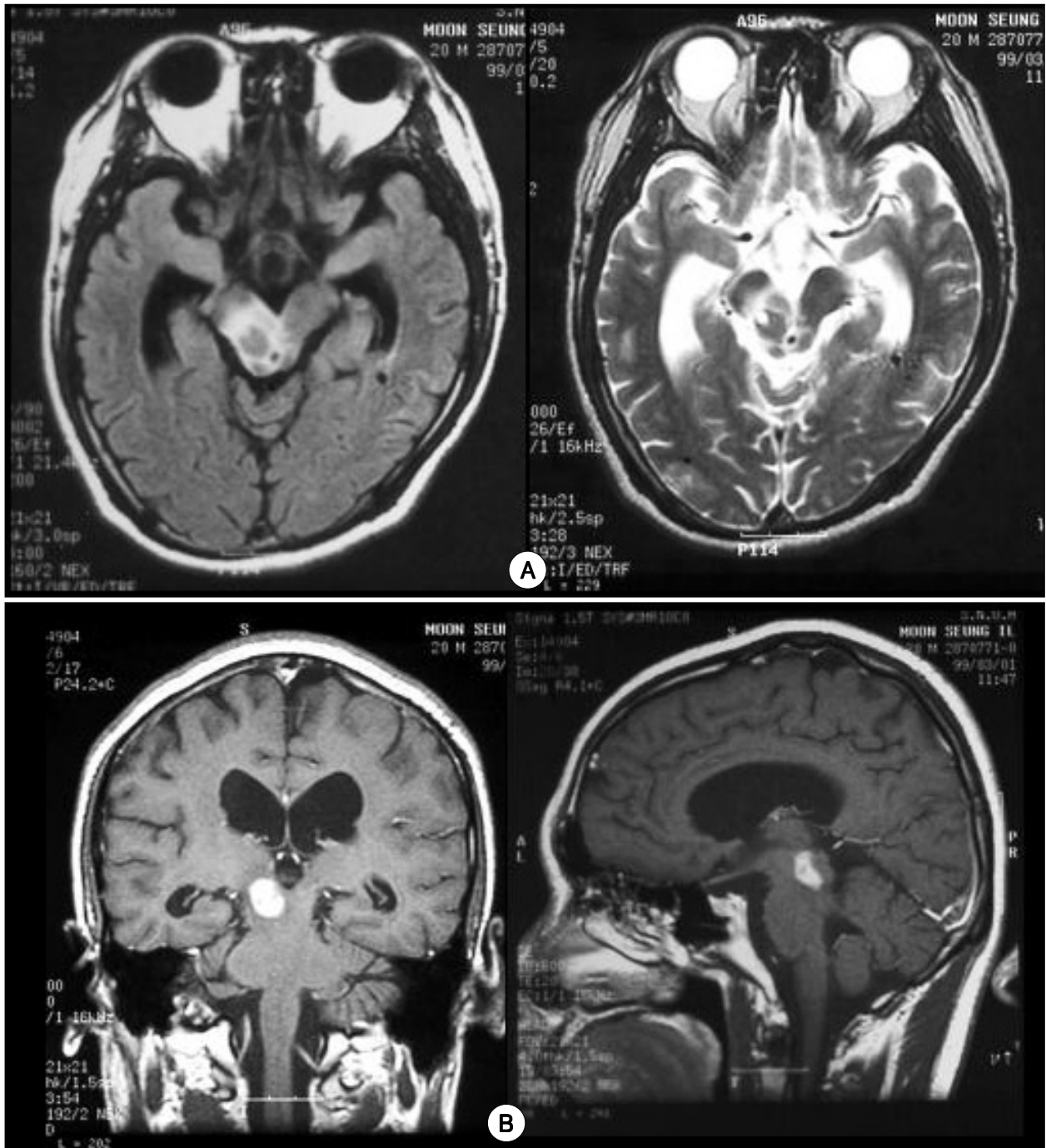
2000 6

Vim

, 26

:

(ataxia)



**Fig. 1.** Rubral tremor associated with midbrain tumor. A : A small mass on the right side of midbrain tegmentum is seen on the T1-weighted(left) and T2-weighted MR images. B : The mass shows enhancement on T1 coronal and sagittal images.

Vim

: 5mm, 3 15mm  
 1.1mm 1.3mm

: 6 가  
 8mm 2mm 4mm  
 2 2mm 가  
 2~5Hz (1.5 volt) 5Hz

, 50Hz 100Hz  
 가 40  
 70 , 80 60

(cerebellar peduncle) 가 (Fig. 1).

3000cGy  
 가 가

Vim 12 Vim  
 (Leksell Model G, Atlanta,  
 Georgia) MRI 가 (Fig. 2).  
 Vim

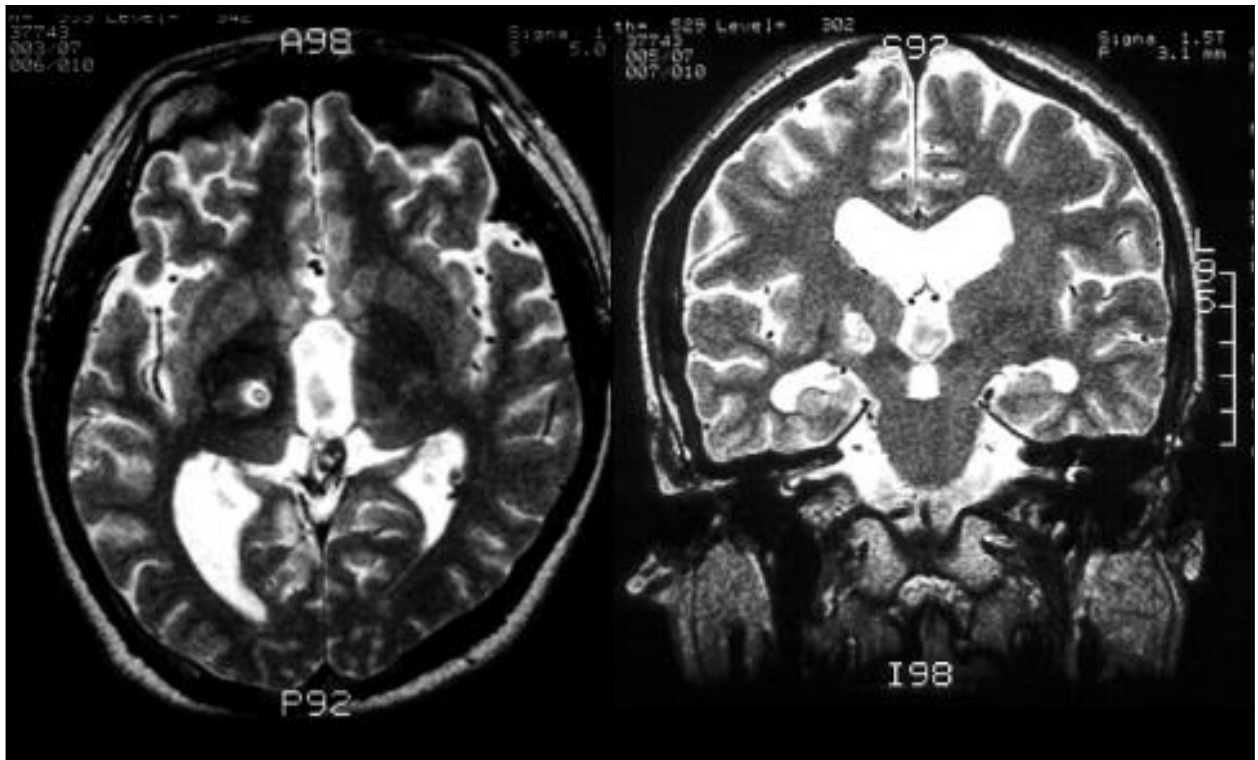


Fig. 2. Postoperative MRI(2 weeks post-lesioning) showing radiofrequency lesioning in the Vim nucleus.

고찰

가 (ruborspinal tract) 가 2). 가 1)6-8). 9). Vim Vim Vim 가 (midbrain tegmentum) Vim Vim (radiofrequency lesioning) 4-6)8). Vim Vim (serotonergic brain stem telencephalic fiber) 3). Vim Vim 6). 가 Vim 가 (somatotopy) 6). 2~5Hz 가 Vim 가 (somatotopy) 가 3). 가 4). 가 (internal capsule) 가 1)2)9). (midbrain tegmentum) (cerebellar peduncle) 4)6). 가 6). 가 (clonazepam) (tremor-synchronous cell) 10). Miyagi 6). (germinoma) (magnetic resonance spectroscopy) choline/creatinine ratio가 가 가 가

Vim

(pallidothalamic tract)  
llidoreticular tract)가

(pa -

Vim

가

### 결 론

Vim

- : 2000 4 12
- : 2000 10 16
- :  
137 - 040 505  
가  
: 02) 590 - 1448, : 02) 594 - 4248  
E - mail : mckim@cmc.cuk.ac.kr

### References

1) Andrew J, Fowler CJ, Harrison MJ : Tremor after head injury and its treatment by stereotactic surgery. *J Neurol Neurosurg Psychiatry* 45 : 815, 1982

2) Bala VM : Uncommon forms of tremor, in *Movement disorders, neurologic principles and practice* (Watts RL, Koller WC, eds) McGraw-Hill, New York, pp391-392, 1997

3) Carpenter MB : A study of the red nucleus in the rhesus monkey. *J Comp Neurol* 105 : 195, 1956

4) Hirai T, Miyazaki M, Nakayama H, Ohye C : The correlation between tremor characteristics and the predicted volume of effective lesions in stereotaxic nucleus ventralis-intermedius thalamotomy. *Brain* 106 : 1001-1018, 1983

5) Keller TM, Tchong TK, Burkhard PR, Richard H, Tamas LB : Stereotactically guided thalamotomy for treatment of parkinsonian tremor isolated to the lower extremity. *Case report. J Neurosurg* 89 : 314-316, 1998

6) Krauss JK, Mohadjer M, Nobbe F, Mundnger F : The treatment of posttraumatic tremor by stereotactic surgery : Symptomatic and functional outcome in a series of 35 patients. *J Neurosurg* 80 : 810-816, 1994

7) Miyagi Y, Shima F, Ishido K, Moriguchi M, Kamikaseda K : Posteroventral pallidotomy for midbrain tremor after pontine hemorrhage, Case report. *J Neurosurg* 91 : 885-888, 1999

8) Ngyuen JP, Degos JD : Thalamic stimulation and proximal tremor. A specific target in the nucleus ventrointermedius thalami. *Arch Neurol* 50 : 498-500, 1993

9) Ohye C, Shibazaki T, Hirai T, Kawashima Y, Hirato M, Matsumura M : Special role of the parvocellular red nucleus in lesion-induced spontaneous tremor in monkeys. *Behav Brain Res* 28 : 241-252, 1988

10) Taha JM, Favre J, Baumann TK, Burchiel KJ : Tremor control after pallidotomy in patients with Parkinson's disease : correlation with microelectrode findings. *J Neurosurg* 86 : 643-647, 1997