

## Diagnostic Imaging of Recurred Mandibular Ameloblastoma with Large Soft Tissue Involvement

Kwan-Soo Park, Sam-Sun Lee, In-Seong Jeon\*, Soon-Chul Choi

Department of Oral and Maxillofacial Radiology & Dental research Institute, College of Dentistry, Seoul National University

\*Dept. of Oral and Maxillofacial Surgery, Sanggyepaik Hospital, Inje University

### ABSTRACT

An uncommon case of a patient with recurrent mandibular ameloblastoma involving various adjacent soft tissues is presented with plain film radiography, computed tomography and magnetic resonance imaging (MRI) and bone scan. The tumor involved mandible and eroded several bones including foramen ovale. This case shows that although an ameloblastoma primarily affect mandible, exact radiographic evaluation of tumor extent will assist the surgeon in the progress of rational approaches to the management of ameloblastoma. (*Korean J Oral Maxillofac Radiol* 2000 ; 30 : 281-285)

**KEY WORDS** : ameloblastoma, recurrence, mandible, skull base

Ameloblastoma is the second most frequent odontogenic tumor<sup>1</sup> and represents about 1% of all tumors and cysts of the jaws. It is usually benign but invades locally and has high recurrence rate and occasionally metastasizes. Histopathologically, it is divided into 4 categories-follicular, plexiform, acanthomatous and granular cell type.<sup>2</sup> It is most common in the third and fourth decade and shows no sexual predilection and occurs predominantly in the mandible.

In plain film radiography, ameloblastoma in the mandible shows a multilocular (so called "soap-bubble" or "honey-comb") expansile radiolucency or a unilocular radiolucency.<sup>3</sup> It frequently shows bucco-lingual cortical expansion especially in axial CT scan. Ameloblastoma in the maxilla can show haziness and mucosal thickening in the maxillary sinus, and also show multilocular or unilocular radiolucency.<sup>4</sup> CT and MRI are essential for diagnosis and treatment planning of ameloblastoma, because they can show tumor extension, border invasion, shell-like bulging of the bony cortex, papillary projection and so on.<sup>5</sup>

The treatment of ameloblastoma includes conservative or radical resection. In case of multicystic type, radical resection is preferably performed and the tumor is removed with a safety margin of at least 1 cm in healthy tissue.<sup>6</sup> The recurrence rate of ameloblastoma has been reported variously by nu-

merous authors. Some authors have found the overall recurrence rate to be 55-90%. However, the incidence of recurrence following radical resection including bone and soft tissues has been reported to be 5-15%.<sup>7</sup>

We present a case of recurrent mandibular ameloblastoma which extensively involves adjacent soft tissues and is suspicious of extension into the skull base.

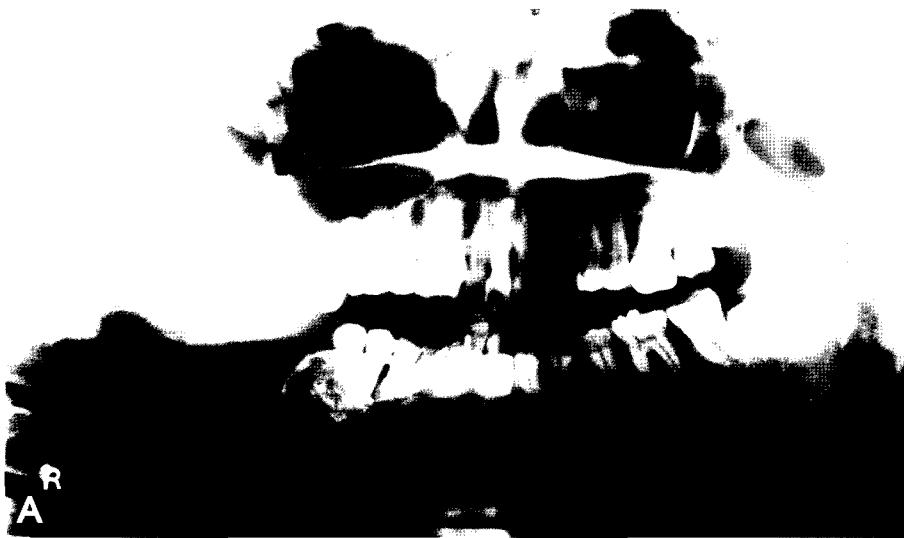### Case report

A 40-year-old woman visited Seoul National University Dental Hospital (SNUDH) for discomfort of right buccal mucosa. The history revealed that she had undergone surgery in 1982 for an ameloblastoma of right mandibular body. The procedure included partial mandibulectomy with bone grafting. Three years later, she underwent an operation of graft removal because of infection on graft site. On her visit-14 years after graft removal, she had a right facial swelling, firm mass palpated on right cheek, hyperplastic tissue on right buccal mucosa, and redness on lower right molar area.

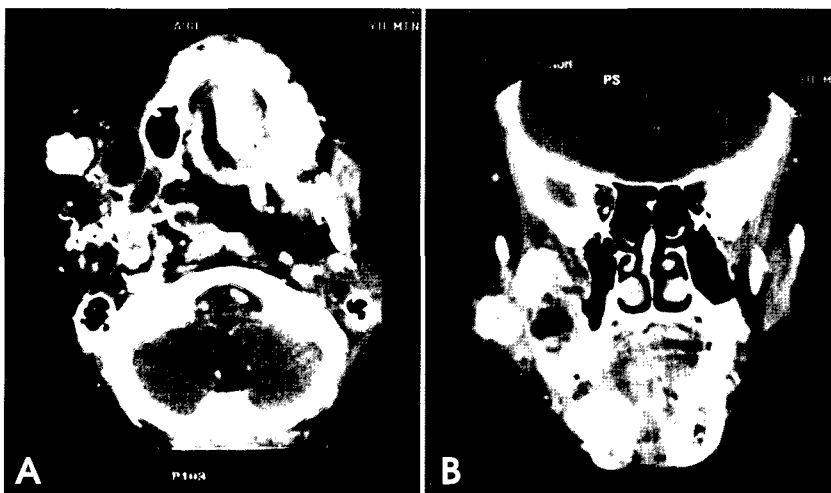
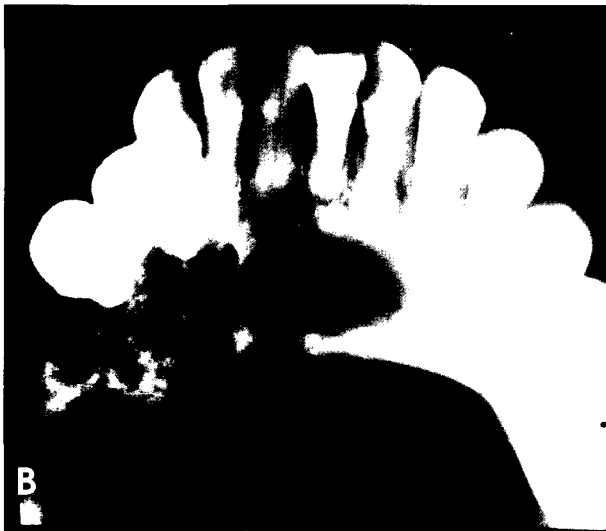In the panoramic and occlusal radiography, honey-comb and soap-bubble appearances of mandible were seen from lateral side alveolar bone of #42 tooth to resected border of right mandibular body, the bony cortex showed thinning and expansion and cystic radiolucent lesion was also seen on mandibular body (Fig. 1). Lateral wall of the right maxillary sinus was depressed and alveolar bone of the maxillary tuberosity was eroded.

The CT scan showed the mass primarily involving right

접수일 : 2000년 8월 18일      채택일 : 2000년 9월 26일  
Corresponding to : Prof. Soon-Chul Choi  
Department of Oral and Maxillofacial Radiology, College of Dentistry, Seoul National University, 28 Yongon-dong, Chongno-gu, Seoul, Korea 110-768  
Tel) 822-760-2622, Fax) 822-744-3919  
E-mail) raychoi@snu.ac.kr



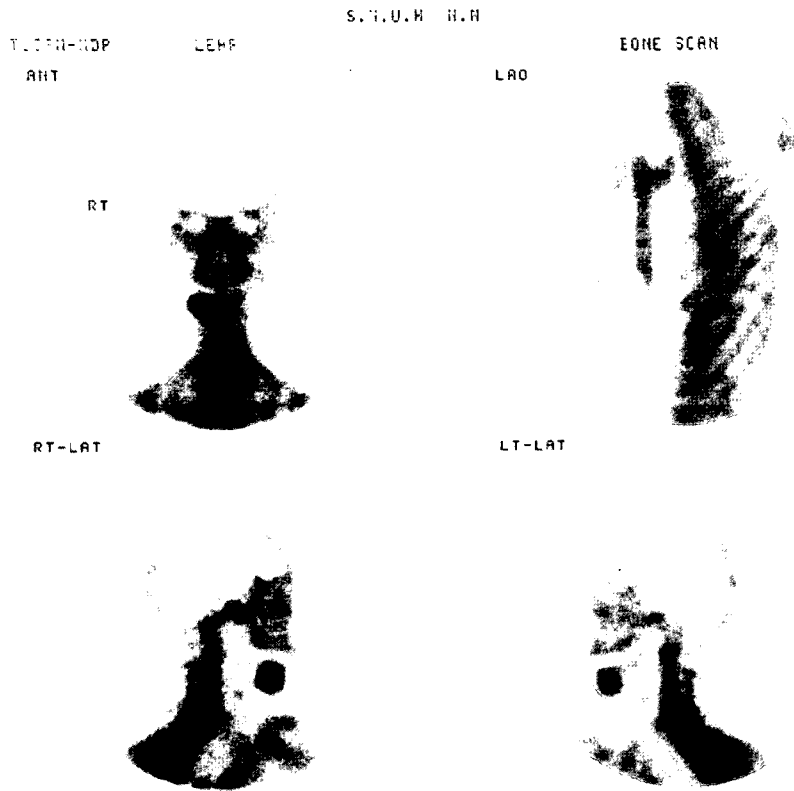
**Fig. 1.** Panoramic (A) and Occlusal radiograph (B). Honey-comb and soap-bubble appearances of mandible are seen from lateral side alveolar bone of #42 tooth to resected border of right mandibular body, the bony cortex showed thinning and expansion and cystic radiolucent lesion was also seen on mandibular body.



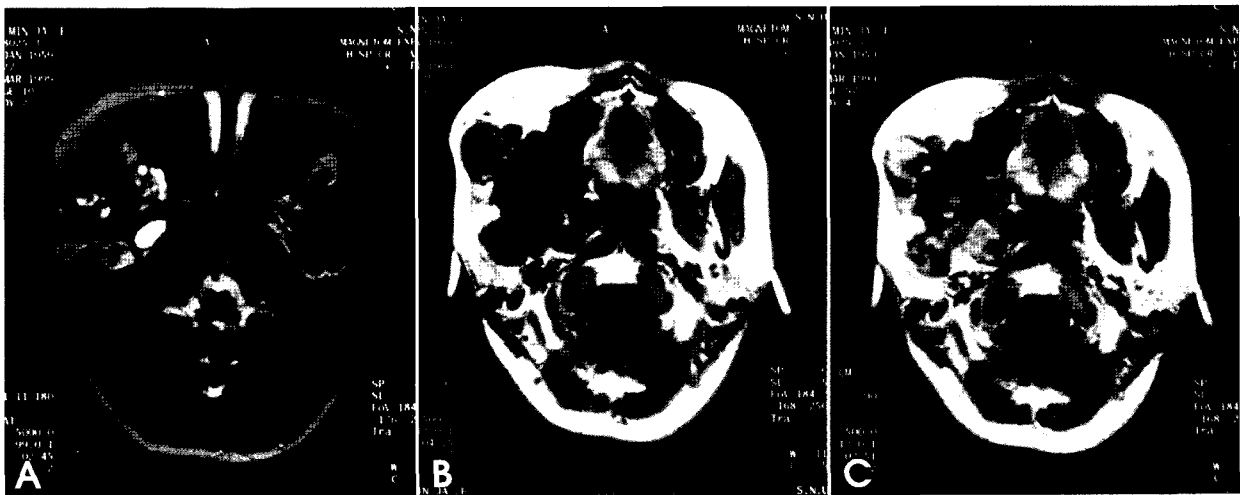
**Fig. 2.** Axial (A) and Coronal (B) Enhanced CT scan. The mass is involving right masticator space with extension to upper masticator space, and causing atrophy of upper portion of right temporal muscle, depression and erosion of lateral wall of right maxillary sinus, and right sphenoid sinus. The mass is heterogeneously enhanced and the lesion similar to described above was seen in the right mandibular body.

masticator space with extension to upper masticator space, atrophy of upper portion of right temporal muscle, depression and erosion of lateral wall of right maxillary sinus and right

sphenoid sinus. The mass was heterogeneously enhanced and the lesion similar to described above was seen in the right mandibular body (Fig. 2).



**Fig. 3.** <sup>99m</sup>Tc bone scan. Collection of radioisotope in right mandible is seen, but no evidence of metastasis to distant area.



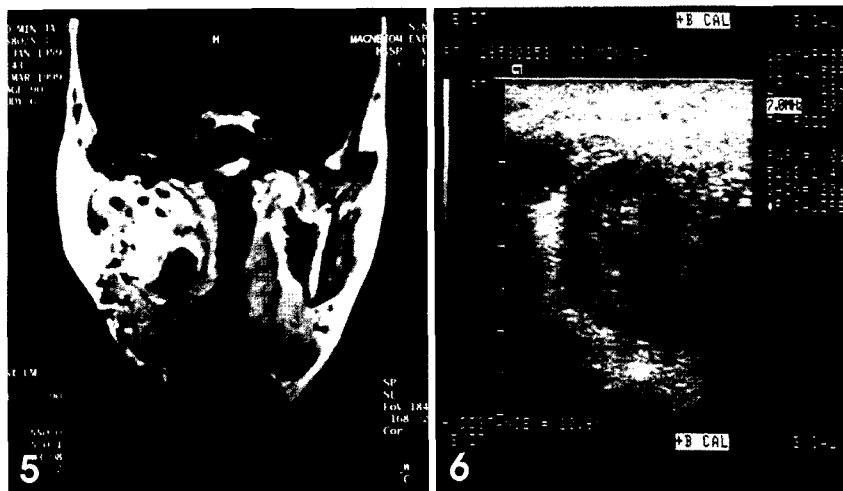
**Fig. 4.** T2-weighted (A), T1-weighted (B), Enhanced (C) MRI. The mass with solid and cystic nature and lobulating contour in the right masticator space is observed, and it is extended to lower part through pterygoid muscle displacing parapharyngeal fat plane and parapharyngeal mucosal space.

The <sup>99m</sup>Tc bone scan in March 1999, showed collection of radioisotope in right mandible but no evidence of metastasis to distant area (Fig. 3).

In the MRI, the mass with solid and cystic nature and lobulating contour in the right masticator space was observed, and it was extended to lower part through pterygoid muscle displacing parapharyngeal fat plane and parapharyngeal mucosal

space (Fig. 4). In the enhanced coronal view, widening of foramen ovale was suspicious and the area showing similar signal intensity of the main mass was seen in the right carotid sinus (Fig. 5). In the neck sonography, 2 cm sized round enlarged lymph node was seen in the right submandibular area (Fig. 6).

Resection operation of partial mandibulectomy and partial



**Fig. 5.** Enhanced coronal MRI. Widening of foramen ovale was suspicious and the area showing similar signal intensity of the main mass is seen in the right cavernous sinus.

**Fig. 6.** Neck sonography. Round enlarged lymph node is seen in the right submandibular area.

maxillectomy with supraomohyoid neck dissection under general anesthesia was done. Neither cavernous sinus extension nor lymph node metastasis was identified, and biopsy specimens showed no evidence of high mitosis incidence and malignant transformation at any slice. We concluded it was a recurrent ameloblastoma of plexiform type mixed with granular cell type unexpectedly extended to surrounding area.

### Discussion

Ameloblastoma occurs mainly in the mandible but rarely in the maxilla. If once occurred in the maxilla, about a half of all maxillary ameloblastomas develop in the posterior part of the maxilla. They have the potential to break through the maxilla into the adjacent vital structures such as the infratemporal fossa, the pterygomaxillary space, the masticator space and the orbit.<sup>8,9</sup> However, mandibular ameloblastomas rarely show extensive growth into the other vital structures unlike maxillary ones. Therefore, this case is unique because of the large soft tissue involvement although recurrence.

In this case, panoramic view was helpful in diagnosing of this huge mass by showing the pathognomonic honey-comb appearance. And CT and MR imaging showed the extension of the mass. Cause of recurrence is mainly that adequate radical therapy was not performed. When a surgery is done, 1 cm safety margin must be confirmed, so it is very useful to verify the border of mass with imaging modalities such as CT or MR imaging. Though contrast-enhanced CT scan can visualize more easily tumor tissue breaking through thin cortical boundaries than MR imaging, decreased attenuation due to fibrosis and edema may make delineation of the tumor-normal tissue interface more difficult in case that electron density of

abnormal tissue approximates that of the normal surrounding tissue.<sup>10</sup> MR imaging can more clearly show interfaces between mass and surrounding tissues. In the primary ameloblastoma outlined with bone tissue, CT scan may have better interpretation capabilities, but in the recurrent maxillary ameloblastomas or the recurrent mandibular ameloblastomas such as this case involving large soft tissue areas, MR imaging may have better interpretation capabilities because this type of tumor was developed from resected bony surface or soft tissues near resection margin.<sup>11</sup>

In pre-operation MR imaging, involvement of skull base was doubted due to the widening of right foramen ovale and the high signal intensity of cavernous sinus. The widening of the foramen ovale may be caused to slight erosion of the skull base due to the mass, however, because the cavernous sinus originally have the high signal intensity in the MRI, it could not mean the extension of the mass. The mass adjacent to skull base was easily separated and no cavernous sinus extension was identified on the operation.

Recurrent ameloblastoma may not be always outlined by bony tissues and may seem to be originated from soft tissues adjacent to resected jaw bone and may involve extremely large area such as this case. Almost of all reported cases were maxillary ones, however, mandibular ones were rarely reported because ameloblastoma occurred on mandible could be easily resected with safety margin compared with ameloblastoma on maxilla presenting complex interface with adjacent structures. In this respect, MR imaging is essential to evaluate the extent of tumors. In our case, the tumor portion which was not completely resected and impacted to the adjacent soft tissues seem to originate a recurrence. This was revealed by same histopathologic result from mandible and various adja-

cent soft tissues.

This case of recurrent mandibular ameloblastoma involved adjacent soft tissues and erosion of the maxilla and skull base is uncommon. Although an ameloblastoma primarily affect mandible, exact radiographic evaluation of tumor extent to the adjacent soft tissue will assist the surgeon in the progress of rational approaches to the management of ameloblastoma.

### References

1. Atikson CH, Harwood AR, Cummings BJ. Ameloblastoma of the jaw. A reappraisal of the role of megavoltage irradiation. *Cancer* 1984 ; 53 : 869-73.
2. Shafer WG, Hine MK, Levy BM. A Textbook of Oral pathology. 1983 ; 281-4.
3. Ueno S, Nakamura S, Mushimoto K, Shirasu R. A clinicopathologic study of ameloblastoma. *J Oral Maxillofac Surg.* 1986 ; 44 : 361.
4. Imai K. et al. Ameloblastoma of the maxilla:report of five cases. *Dentomaxillofac Radiol* 1980 ; 9 : 41.
5. M. Minami, T. Kaneda, H Yamaoto et al. Ameloblastoma in maxillo-mandibular region: MR imaging. *Head and Neck Radiology* 1992 ; 184 : 389-93.
6. Gardner DG, Pecak AMJ. The treatment of ameloblastoma based on pathologic and anatomic principles. *Cancer* 1980 ; 46 : 2514-9.
7. Collings SJ, Harrison A. Recurrent ameloblastoma?-an historic case report and review of the literature. *Br Dent J* 1993 ; 174 : 202-6.
8. Dramola JO, Abioye AA, Aqjage HA, et al. Maxillary malignant ameloblastoma with intraorbital extension : report of a case. *J Oral Maxillofac Surg* 1980 ; 38 : 203-6.
9. Kyriazis AP, Karkazis GC, Kyriazis AA. Maxillary ameloblastoma with intracerebral extension. *Oral Surg Oral Med Oral Pathol* 1971 ; 32 : 582-7.
10. Heffez L, Mafee MF, Vaiana J. The role of magnetic resonance imaging in the diagnosis and management of ameloblastoma. *Oral Surg Oral Med Oral Pathol* 1988 ; 65 : 2-12.
11. Kwai T, Murakami S, Kishino M, Matsuya T, Sakuda M, Fuchihata H. Diagnostic imaging in two cases of recurrent maxillary ameloblastoma : comparative evaluation of plain radiographs, CT and MR images. *British J Oral Maxillofac Surg* 1998 ; 36 : 304-10.