

Neuronal Dysfunction in Patients with Chronic Alcoholism Evaluated by In Vivo ¹H Magnetic Resonance Spectroscopy

Bo-Young Choe¹, Euy-Neyng Kim², Chang-Wook Lee³, In-Ho Baik³, Kwang-Soo Lee⁴, Byung-Chul Son⁵, Heung-Jae Chun¹, Hyoung-Koo Lee¹, Tae-Suk Suh¹, Jae-Moon Lee², Kyung-Sub Shinn^{1,2}

Purpose : With the use of localized, water-suppressed *in vivo* ¹H magnetic resonance spectroscopy (MRS), we evaluated the proton metabolic alterations in patients with chronic alcoholism and healthy normal controls.

Material and Methods : Patients with chronic alcoholism (N=10) and normal control subjects (N=10) underwent MRS examinations using a stimulated echo acquisition mode (STEAM) pulse sequence with 2×2×2 cm³ volume of interest (VOI) in the left cerebellum and basal ganglia. Proton metabolite ratios relative to creatine (Cr) were obtained using a Marquart algorithm.

Results : The specific feature in patients with chronic alcoholism was a significant decrease of N-acetylaspartate (NAA)/Cr ratio in the left cerebellum, compared with normal controls. No clear correlation of other metabolite ratios such as choline (Cho)/Cr and inositols (Ins)/Cr was established.

Conclusion : Our preliminary study suggests that the reduction of NAA/Cr ratio may indicate neuronal loss in patients with chronic alcoholism. Thus, *in vivo* ¹H MRS may be a useful modality in the clinical evaluation of patients with chronic alcoholism based on the proton metabolite ratios.

Index words : Magnetic resonance spectroscopy, Chronic alcoholism

Introduction

It has been known that patients with chronic alcoholism have smaller, lighter and more shrunken brains

than age- and sex-matched adults with no history of alcoholism and that chronic alcohol consumption leads to cellular changes, resulting in abnormalities in brain morphology (1). Severe central nervous system (CNS) complications can be affected by a variety of specific process-

JKSMRM 4:94-99(2000)

¹Departments of Biomedical Engineering, Kangnam St. Mary's Hospital, College of Medicine, The Catholic University of Korea

²Departments of Radiology, Kangnam St. Mary's Hospital, College of Medicine, The Catholic University of Korea

³Departments of Psychiatry, Kangnam St. Mary's Hospital, College of Medicine, The Catholic University of Korea

⁴Departments of Neurology, Kangnam St. Mary's Hospital, College of Medicine, The Catholic University of Korea

⁵Departments of Neurosurgery, Kangnam St. Mary's Hospital, College of Medicine, The Catholic University of Korea

This study was supported by the Research Fund of Catholic Medical Center. This paper was presented at the Seventh Scientific Meeting and Exhibition of the International Society of Magnetic Resonance in Medicine at Philadelphia, Pennsylvania, USA, May 22-28, 1999.

Received; June 7, 2000, accepted; Aug 29, 2000

Address reprint requests to : Bo-Young Choe, Ph.D., Department of Biomedical Engineering, Kangnam St. Mary's Hospital, College of Medicine, The Catholic University, #505 Banpo-Dong, Seocho-Gu, Seoul 137-040, Korea
Tel. 82-2-590-2427 Fax. 82-2-590-2425 E-mail: bychoe@cmc.cuk.ac.kr

es related to ethanol intoxications such as Wernicke's encephalopathy, hepato-cerebral degeneration, central pontine myelinolysis and Marchiafava-Bignami syndrome. Cerebral atrophy and ventricular dilatation are well known lesions that can be detected in patients with chronic alcoholism by MRI (2) and PET (3). Atrophy of the mamillary bodies has been identified in approximately 80% of alcoholics with a history of classic Wernicke's encephalopathy (4). However, the neuropathological mechanisms of attentional disorders and CNS dysfunction associated with chronic alcoholism are not fully elucidated yet.

The technique of localized *in vivo* ¹H MRS has become practical in the clinical environment through the judicious use of commercial 1.5 T MR systems in conjunction with the improved pulse sequences (5). This technique is a rapid, sensitive, non-invasive and potentially risk-free method which can identify and quantify the level of biochemical compounds, and to investigate the metabolism and biochemistry of a variety of brain diseases and disorders (6, 7). This application opens up the possibility of observing major proton metabolites such as N-acetylaspartate (NAA), creatine/phosphocreatine (Cr), choline-containing compounds (Cho) and inositols (Ins). Information may be obtained about local cellular metabolism by determining peak metabolite ratios of the neurochemical compounds detected in the MR spectra.

The purpose of this study was to investigate the proton metabolic differences of cerebellum and basal ganglia in patients with chronic alcoholism compared with normal controls, and to test the possibility that ¹H MRS could provide neuropathologic criteria in the diagnosis of chronic alcoholism. Employing image-guided, water-suppressed *in vivo* ¹H MRS with a 1.5 T whole body MRI/MRS system, we have studied the spectral patterns in patients with chronic alcoholism without evidence of neurological and neuropsychological impairment.

Materials and Method

Subjects

Ten male patients with chronic alcoholism (age range 31-64 years) were recruited from Catholic Medical Center detoxication unit. The average amount of alcohol consumed was 155 cans of beer per week (SD = 36). All of the patients fulfilled DSM III-R criteria for alcohol de-

pendence, had a family history of alcoholism in at least one first-degree relative, had an early onset history of alcoholism, had at least a 10-year history of alcohol abuse, and had undergone detoxification 7-50 days before the study. After complete description of the study to the patients or family members, written informed consent was obtained. Patients with a history of another neuropsychiatric disorder or a drug abuse were excluded from the study.

None of the patients were past or present users of any drug other than alcohol. The normal control group consists of 10 healthy male volunteers (age range 27-61 years) who were recruited from the Catholic University Medical Center (CUMC) staff, residents, interns and medical students. None of the control subjects had any serious drinking habit or any known neurological or psychiatric deficits.

MRS examination

All localized, water-suppressed *in vivo* ¹H MRS studies were performed on a 1.5 T MRI/MRS system (GE Signa Advantage, version 4.8; GE Medical Systems, Milwaukee, Wisconsin) using a stimulated echo acquisition method (STEAM) sequence after water suppression with three chemical-shift-selective saturation (CHESS) RF pulse and dephasing gradients (8-9). Using T1 (20 ms TE, 400 ms TR) and T2-weighted (90 ms TE, 2500 ms TR) MR images, 2 × 2 × 2 cm³ (8 ml) voxels in the left cerebellum and basal ganglia were selected while avoiding the lateral ventricle (Figure 1). All of the water-suppressed *in vivo* ¹H MR spectra were obtained from voxels localized in the left cerebellum and basal ganglia in patients with chronic alcoholism and control subjects. Spectral parameters were: 20 ms TE, 2000 ms TR, 30 ms TM, 128 averages, 2500 Hz spectral width, and 2048 data points. The total examination time per case was approximately 30 minutes. All ¹H MR spectra were acquired with use of the standard birdcage quadrature head coil (GE Medical Systems, Milwaukee, Wisconsin) that produces a uniform RF field (63.86 MHz). Raw data were transferred to a Sun SPARC station IPC (Sun Microsystems, Mountain View, California) and processed by the SAGE data analysis package (GE Medical Systems, Milwaukee, Wisconsin).

Shimming with the water signal was performed to obtain a uniform and homogeneous magnetic field by adjustment of the linear shims. Typical line width (full

width at half maximum) was 3–4 Hz. Special attention was given to locating the water signal frequency to maximize the water suppression. Exponential line broadening (0.5 Hz) was used for apodization of the FID. Time domain data were converted to frequency domain by Fourier transformation. Frequency domain spectra were phased by hand, with use of frequency-independent phase corrections only. Phased absorption spectra are reported directly without baseline correction or resolution enhancement. Since water suppression was done upto 99 %, baseline correction was not necessary in the study. All of the ¹H MR spectra were plotted and analyzed in the absorption mode, and fitted to Lorentzian lineshapes. Peak areas for each proton metabolite were measured using a Marquart algorithm (10). Proton resonances in the spectra obtained from brain tissues were assigned on the basis of prior assignments (11). Resonance peak assignments of major proton metabolites were CH₃ of NAA, 2.00 ppm; N-CH₃ of Cr, 3.00 ppm; N-(CH₃)₃ of Cho, 3.20 ppm; H4 and H6 of Ins, 3.50 ppm. The quantitative results were evaluated with the intensity of the Cr resonance as a reference (12). After blindly processed, we calculated the metabolite ratios of NAA/Cr, Cho/Cr and Ins/Cr in the cerebellum and basal ganglia of the brain, and compared with those of normal controls. The ratio of Glx/Cr was not estimated due to the negligible alterations in the cerebellum and basal ganglia of the brain.

Statistics

Statistical analysis was performed using SPSS (SPSS

for Windows, Version 6.0, SPSS Inc., Chicago, Illinois). The data were analyzed with two-tailed t-tests, where $p < 0.05$ was considered statistically significant.

Results

Figure 1 shows typical axial MR images in patients with chronic alcoholism with the voxels selected from the left cerebellum and basal ganglia for localized *in vivo* ¹H MRS. Brain atrophy and ventricular enlargement were well demonstrated in the spin echo MR images. Unlike spectral patterns of the basal ganglia, those of the cerebellum were substantially different between patients with chronic alcoholism and control subjects in Figure 2. In particular, NAA signal intensity in patient with chronic alcoholism showed a marked decrease compared with that in normal control. Figure 3 shows a comparison of proton metabolite ratios (NAA/Cr and Ins/Cr) between patients with chronic alcoholism and normal controls. The specific feature in patients with chronic alcoholism was a significant decrease of NAA/Cr ($p = 0.001$) ratios compared with normal controls. In Table 1, the ratio of NAA/Cr in patients with chronic alcoholism was 0.99 ± 0.17 , while that in normal controls was 1.35 ± 0.18 . However, no significant difference of Ins/Cr ($p = 0.125$) and Cho/Cr ($p = 0.831$) was established between patients and control subjects. The ratios of Ins/Cr and Cho/Cr in patients with chronic alcoholism were 0.57 ± 0.21 and 0.65 ± 0.11 , while those in normal controls were 0.64 ± 0.16 and 0.67 ± 0.12 , respectively.

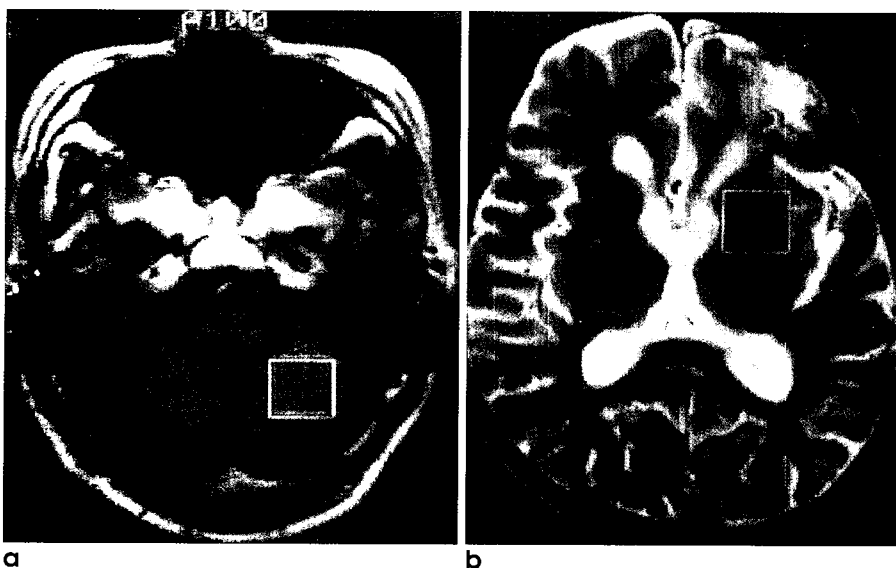


Fig. 1. Typical axial MR images in patients with chronic alcoholism with the voxels of left (a) cerebellum and (b) basal ganglia selected for localized *in vivo* ¹H MRS. **b**

Discussion

In vivo ¹H MRS is most sensitive to unbound, freely mobile metabolites, and has clinical applications to categorize noninvasively the various states of metabolic or

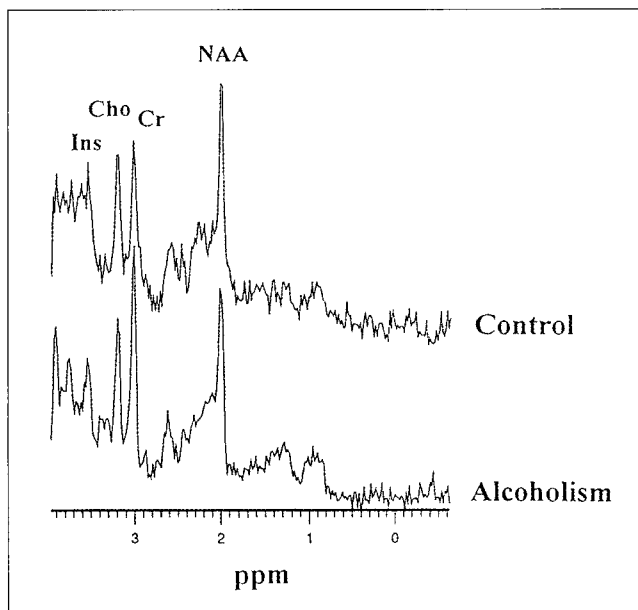


Fig. 2. Localized, water-suppressed *in vivo* ¹H MR spectra obtained from the left cerebellum of a normal control and a patient with chronic alcoholism. Chemical shifts are indicated in parts per million (ppm). A marked reduction in the NAA signal intensity is noted in the patient with alcoholism.

biochemical disorders. A spatially localized, water-suppressed STEAM pulse sequence that samples the relative levels of mobile metabolites from a VOI defined from an MR image has provided a valuable biochemical basis for integrating anatomical and pathological information obtained from MRI. Our preliminary study shows that it is possible to monitor proton metabolites including neurochemical compounds that may be involved in patients with chronic alcoholism. *In vivo* ¹H MR spectra were used to study proton metabolites of the left basal ganglia and cerebellum in patients with

Table 1. Comparison of Proton Metabolite Ratios in the Cerebellum between Patients with Alcoholism and Normal Controls

	Inc/Cr	Cho/Cr	NAA/Cr
Controls	0.64±0.16	0.67±0.12	1.35±0.18
Pt #1	0.46	0.54	0.90
Pt #2	0.75	0.64	0.85
Pt #3	0.27	0.68	1.22
Pt #4	0.96	0.73	0.99
Pt #5	0.75	0.71	1.08
Pt #6	0.67	0.77	1.29
Pt #7	0.51	0.53	0.87
Pt #8	0.45	0.67	0.81
Pt #9	1.35	0.65	1.10
Pt #10	0.53	0.57	0.80
Mean±SD	0.57±0.21	0.65±0.11	0.99±0.17
P	0.125	0.831	0.001

Note. - Ratios for the controls are mean SD (standard deviation).

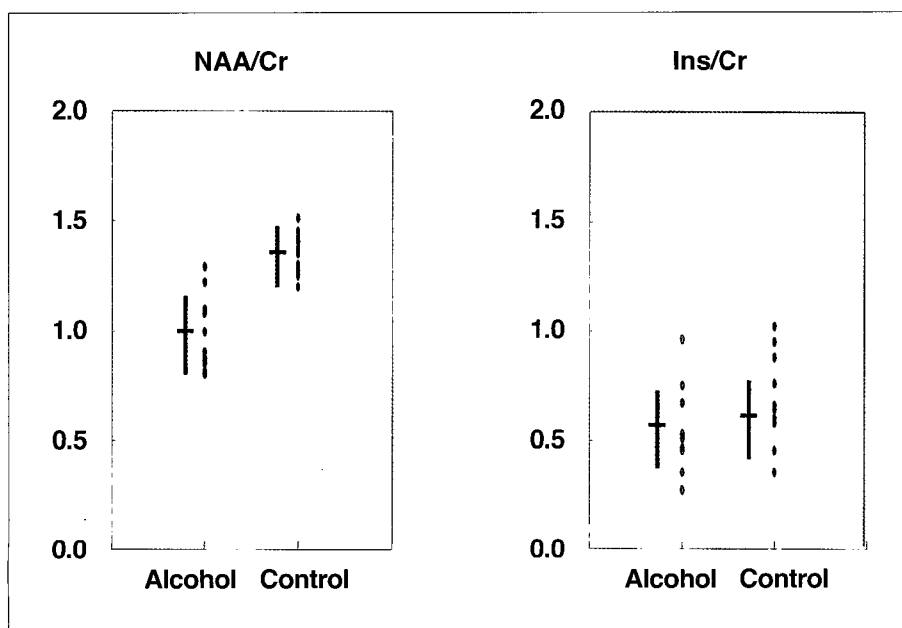


Fig. 3. Comparison of NAA/Cr and Ins/Cr ratios in the cerebellum between patients with chronic alcoholism (Alcohol) and normal controls (Control). Note that the mean and SD are shown with cross mark (+).

chronic alcoholism. The combination of anatomical and biochemical metabolic information offers a new means for understanding the neuropathologic progression in patients with chronic alcoholism.

Like other previous studies (13-14), we observed that patients with chronic alcoholism had decreased ratio of NAA/Cr, particularly in the cerebellum. The ratio of NAA/Cr was within normal range in two patients who had detoxication more than 45 days. These patients showed improved clinical symptoms which indirectly indicated the correlation between the ratio of NAA/Cr and clinical improvement. However, the ratios of Ins/Cr and Cho/Cr did not show any good clinical correlation. Thus, the ratio of NAA/Cr seems to be quite sensitive for metabolic evaluation in patients with chronic alcoholism, and the ratio of NAA/Cr may serve as a metabolic criterion that can specify the grade in patients with chronic alcoholism and predict the patient's clinical outcome.

The proton metabolite ratios (i.e., NAA/Cr) of the cerebral white matter for normal controls are generally in good agreement with other groups (15-16). The proton metabolite ratio, particularly NAA/Cr ratio, was significantly reduced in the left cerebellum in patients with chronic alcoholism, compared with normal controls ($p=0.007$). The decrease of NAA signal intensity may indicate neuronal loss or dysfunction in the cerebellum in patients with chronic alcoholism since NAA is located almost exclusively in neurons (17), and is believed to be a neuronal marker.

Despite the limited number of patients included in this study, our results strongly suggest that *in vivo* ^1H MRS may be a useful modality for clinical evaluation in patients with chronic alcoholism based on the proton metabolite ratios, in particular NAA/Cr ratio. Moreover, *in vivo* ^1H MRS could aid in better understanding the neuropathologic process in patients with chronic alcoholism and enhance the ability to accurately assess post-alcoholic brain damage. It is necessary to investigate the spectral alterations in various stages in patients with chronic alcoholism for further detailed analysis

Acknowledgments

We express our gratitude to Mr. Sang-Mook Lee, Mr. Ho-Gun Lee, and Mr. Byung-Hoon Ha (Kangnam St. Mary's Hospital, Seoul, Korea) for providing technical support and patient treatment. This study was support-

ed by the Research Fund of Catholic Medical Center. This paper was presented at the Seventh Scientific Meeting and Exhibition of the International Society of Magnetic Resonance in Medicine at Philadelphia, Pennsylvania, USA, May 22-28, 1999.

References

1. Harper CG, Kril JJ. Neuropathology of alcoholism. *Alcohol and alcoholism* 1990;25:207-216.
2. Hayakawa K, Kumagai H, Suzuki Y, Furusawa N, Haga T, Hoshi T, Fujiwara Y, Yamaguchi K. MR imaging of chronic alcoholism. *Acta Radiologica* 1992;33:201-206.
3. Wang GJ, Volkow ND, Roque CT, Cestaro VL, Hitzemann RJ, Cantos EL, Levy AV, Dhawan AP. Functional importance of ventricular enlargement and cortical atrophy in healthy subjects and alcoholics as assessed with PET, MR imaging, and neuropsychologic testing. *Radiology* 1993;186:59-65.
4. Charness ME, DeLaPaz RL. Mamillary body atrophy in Wernicke's encephalopathy: Antemortem identification using magnetic resonance imaging. *Ann Neurol* 1987;22:595-600.
5. Bottomley PA. Human *in vivo* NMR spectroscopy in diagnostic medicine: clinical tool or research probe? *Radiology* 1989;170:1-15.
6. Aue WP. Localization methods for *in vivo* nuclear magnetic resonance spectroscopy. *Rev Magn Reson Med* 1986;1:21-72.
7. Frahm J, Bruhn H, Gyngell ML, Merboldt KD, Hanicke W, Sauter R. Localized high-resolution ^1H NMR spectroscopy using stimulated echoes: initial applications to human brain *in vivo*. *Magn Reson Med* 1989;9:79-93.
8. Ordidge RJ, Bendall MR, Gordon RE, Connelly A. Volume selection for *in vivo* spectroscopy. In: Govil G, Khetrpal CL, Sarans A, eds. *Magnetic resonance in biology and medicine*. New Delhi: Tata-McGraw-Hill, 1985:387-397.
9. Frahm J, Merboldt KD, Hanicke W. Localized proton spectroscopy using stimulated echoes. *J Magn Reson* 1987;72:502-508.
10. Kreis R, Farrow N, Ross B. Localized ^1H NMR spectroscopy in patients with chronic hepatic encephalopathy: analysis of change in cerebral glutamine, choline, and inositols. *NMR in Biomed* 1991;4:109-116.
11. Frahm J, Bruhn H, Gyngell ML, Merboldt KD, Hanicke W, Sauter R. Localized high-resolution proton NMR spectroscopy using stimulated echoes: Initial applications to human brain *in vivo*. *Magn Reson Med* 1989;9:79-93.
12. Ross B, Kreis R, Ernst T. Clinical tools for the 90s: magnetic resonance spectroscopy and metabolic imaging. *Eur J Radiol* 1992;14:128-140.
13. Jagannathan NR, Desai NG, Raghunathan P. Brain metabolite changes in alcoholism: an *in vivo* proton magnetic resonance spectroscopy (MRS) study. *Magn Reson Img* 1996;14:553-557.
14. Langleben D, Bloomer C, Fein G, Meyerhoff DJ. Evidence of neuronal damage in the midbrain of chronic heavy drinkers. *Proc. 6th ISMRM* 1998;3:1716.
15. Kugel H, Heindel W, Ernestus RI, Bunke J, du Mesnil R,

Neuronal Dysfunction in Patients with Chronic Alcoholism Evaluated by In Vivo ¹H Magnetic Resonance Spectroscopy

Friedmann G. Human brain tumors: Spectral patterns detected with localized H-1 MR spectroscopy. Radiology 1992; 183:701-709.

16. Jarvik JG, Lenkinski RE, Grossman RI, Gomori JM, Schnell MD, Frank I. Proton MR spectroscopy of HIV-infected pa-

tients: Characterization of abnormalities with imaging and clinical correlation. Radiology 1993;186:739-744.

17. Nadler JV, Cooper JR. N-acetyl-L-aspartic acid content of human neural tumors and bovine peripheral nervous tissues. J Neurochem 1972;19:313-319.

대한자기공명영상학회지 4:94-99(2000)

알콜중독환자의 신경기능 장애: 생체 양성자 자기공명분광 연구

¹가톨릭대학교 의과대학, 의공학교실
²가톨릭대학교 의과대학, 방사선과학교실
³가톨릭대학교 의과대학, 정신과학교실
⁴가톨릭대학교 의과대학, 신경과학교실
⁵가톨릭대학교 의과대학, 신경외과학교실, 강남성모병원

최보영¹ · 김의녕² · 이창욱³ · 백인호³ · 이광수⁴ · 손병철⁵ · 전홍재¹ · 이형구¹
서태석¹ · 이재문² · 신경섭^{1,2}

목적 : 국한적 수분억제 생체내 양성자 자기공명분광학을 사용하여 만성 알코올 중독자와 정상 건강인의 뇌대사물질의 비율을 비교평가하였다.

대상 및 방법 : 만성 알코올 중독자 10명, 정상 건강인 10명의 좌측 소뇌와 basal ganglia 의 관심부위 2 × 2 × 2 cm³를 각각 선택하여 STEAM 펄스시퀀스를 이용하였다. Creatine (Cr)을 기준으로 Marquart 알고리즘을 이용하여 각 대사물질의 비율을 산출하였다.

결과 : 만성 알코올 중독자의 특징적인 소견은 정상인과 비교하여 볼 때 N-acetyl aspartate (NAA)/Cr 비율이 감소하였다. 그러나 Choline (Cho)/Cr 등 다른 대사비율은 정상인과 유의한 차이를 발견할 수 없었다. NAA/Cr 비율은 임상평가와 상당한 상호관계가 있는 것으로 나타났다.

결론 : 본 예비실험 결과는 만성 알코올 중독자의 NAA/Cr 의 비율 감소를 토대로 환자 소뇌의 신경세포 소실을 추정할 수 있었다. NAA/Cr 비율은 향후 만성 알코올 중독자의 임상평가를 추정할 수 있는 대사표준으로 사용될 수 있음을 시사해주고 있다. 따라서 생체내 양성자 자기공명분광법은 양성자 비율을 토대로 만성 알코올 중독자의 임상평가에 유용한 방법으로 사용될 수 있으리라 사료된다.

통신저자 : 최보영, 137-040 서울시 서초구 반포동 505번지, 가톨릭대학교 의과대학, 의공학교실
Tel. 82-2-590-2427 Fax. 82-2-590-2425 Email: bychoe@cmc.cuk.ac.kr