

# 원거리근육입구형심실중격결손과 폐동맥협착이 동반된 대혈관전위

김 웅 한\* · 이 택 연\* · 김 수 철\* · 전 흥 주\* · 한 미 영\*\* · 김 수 진\*\*  
이 창 하\* · 정 철 현\* · 오 삼 세\* · 이 영 탁\*

=Abstract=

## Transposition of great arteries with pulmonary stenosis and remote muscular inlet ventricular septal defect

Woong-Han Kim, M.D.\*, Taek-Yeon Lee, M.D.\*, Soo Cheol Kim, M.D.\*, Hong Joo Jeon, M.D.\*,  
Mi Young Han, M.D.\*\*, Soo Jin Kim, M.D.\*\*, Chang Ha Lee, M.D.\*, Cheol Hyun Chung, M.D.\*,  
Sam Sae Oh, M.D.\*, Young-Tak Lee, M.D.\*

We report a successful biventricular repair of D-transposition of great arteries, pulmonary stenosis and remote muscular inlet ventricular septal defect, after modified Blalock-Taussig shunt early in infant. A long left ventricle-to-aorta intraventricular rerouting tunnel was created without stenosis by transferring the medial papillary muscle of the tricuspid valve to the tunnel, obliterating the trabeculation of right ventricle in the course of tunnel and excising the secondary chordae of the tricuspid valve.

(Korean Thorac Cardiovasc Surg 2000;33:262-4)

Key word : 1. Transposition of great vessels  
2. Rastelli operation.

## Case

Over the past several years a number of centers have reported favorable results with Rastelli or Lecompte procedure for complete transposition of great arteries(TGA) with ventricular septal defect(VSD) and pulmonary stenosis(PS). The VSD in this instance was mostly perimembranous type. We present a case of

TGA and PS in combination with remote muscular inlet type VSD. After palliation early in infancy, successful biventricular repair was performed when the patient was 22 months of age.

A male neonate(age, 2 days) was referred to our hospital for evaluation. Echocardiography revealed D-TGA, remote VSD, and combined severe valvar and subvalvar PS.

At the age of 50 days, he underwent right side modified

\*부천세종병원 흉부외과, 세종심장연구소

Department of Thoracic and Cardiovascular Surgery, Sejong Heart Institute, Puchon-shi, Kyonggi-do, Korea

\*\*부천세종병원 소아과

Pediatric Cardiology, Sejong General Hospital, Puchon-shi, Kyonggi-do, Korea

논문접수일 : 99년 9월 16일 심사통과일 : 2000년 3월 15일

책임저자 : 김웅한(422-052) 경기도 부천시 소사구 소사본2동 91-121, 부천세종병원 흉부외과. (Tel) 032-3401-151 (Fax) 032-349-3005,

E-mail : woonghan@kics.or.kr

본 논문의 저작권 및 전자매체의 지적소유권은 대한흉부외과학회에 있다

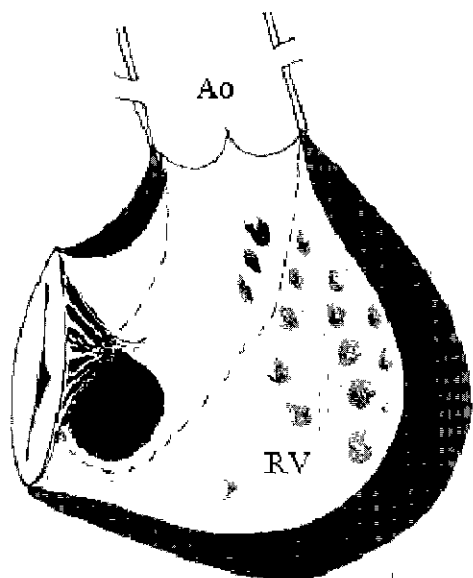


Fig. 1. Intraventricular tunnel repair of the transposition of great arteries with pulmonary stenosis and remote muscular inlet ventricular septal defect. The dashed lines indicate the suture sites for baffling of left ventricular outflow tract. Ao = aorta, RV = right ventricle.

Blalock-Taussig shunt(4 mm). Repeat evaluation at age 16 months by cardiac catheterization and echocardiography showed D-TGA, remote muscular inlet VSD(diameter, 8.5-10.5 mm), combined PS, adequately sized both ventricle with good function, large big ascending aorta(annulus, 20 mm) and well-grown both pulmonary arteries. The VSD was relatively small compared to ascending aorta, but the absolute size( $2.8 \text{ cm}^2/\text{m}^2$ ) was not restrictive.

When the child was 22 months of age(body weight, 11 kg), anatomic repair was performed. After sternotomy, hypothermic cardiopulmonary bypass with takedown of the shunt and cardioplegic arrest, the right atrium and the right ventricle were opened, and the intracardiac anatomy was explored. At this time surgical options about a biventricular repair depending on the feasibility of channeling left ventricle blood to the aorta. The papillary muscle of mitral valve was inserted in the opposite ventricular chamber, on the edge of the VSD. So it was not an obstacle to tunnel reconstruction. But the minor chordae of the tricuspid valve at the edge of VSD, the medial papillary muscle of tricuspid valve, and the trabeculations of the right ventricle were the obstacles.

The trabeculations in the course of tunnel of the right ventricle were obliterated primarily with pledget-supported

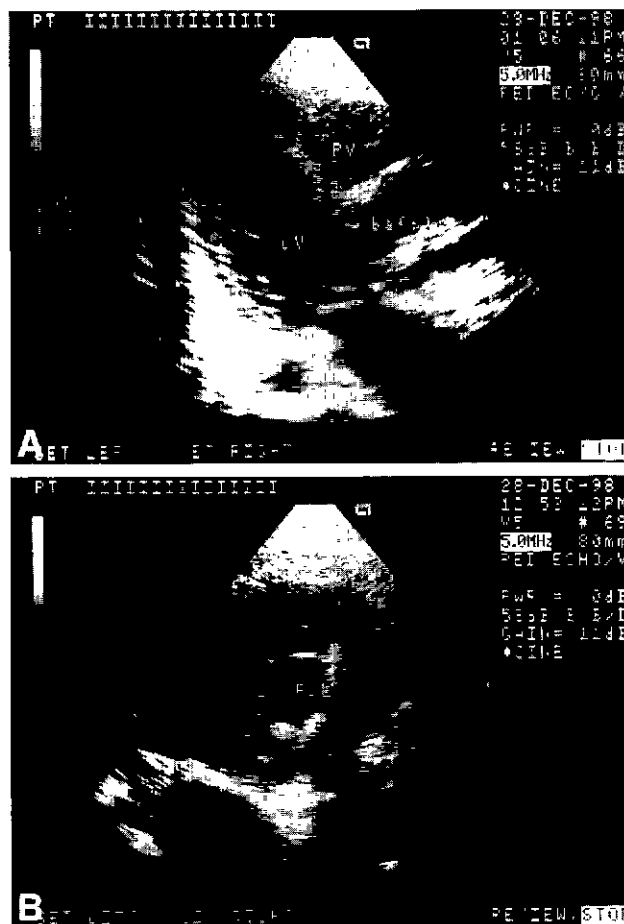

Fig. 2. Postoperative transthoracic echocardiographic view of the left ventricular outflow tract demonstrating unobstructive intraventricular rerouting tunnel (A) long-axis view, (B) cross-section view.

interrupted mattress sutures, and all the secondary chordae of the tricuspid valve on upper margin of the VSD were excised. And then a long intraventricular rerouting tunnel from the LV to the aorta was created with glutaraldehyde-fixed autologous pericardium while managing to avoid stenosis.

It was accomplished removing the medial papillary muscle of the tricuspid valve at its muscular insertion and was secondarily reimplanting onto the tunnel patch. A small 1-way atrial septal defect was created to allow right-to-left decompression.

The ascending aorta was huge and in the anterior, the pulmonary artery was in the posterior, so the pulmonary valve was obliterated, and valved pulmonary conduit(14 mm, Polystan, Copenhagen, Denmark) was used to restore the continuity between the right ventricle and the pulmonary artery. The patient was separated from the bypass without difficulty, and a

postrepair intraoperative transesophageal echocardiography showed no anatomic defect, except trivial tricuspid regurgitation.

Cardiopulmonary bypass and aortic cross-clamp time were respectively 295 and 196 minutes. The patient was extubated on the 1st postoperative day and the remaining postoperative course was uneventful. The postrepair  $P_{RV/LV}$  in the intensive care unit was 0.32-0.42. He was discharged on the 12<sup>th</sup> postoperative day. The patient remains well 6 months after the operation.

### Comment

The Rastelli or Lecompte procedures are considered the standard surgical procedure in many centers for the repair of TGA associated with VSD and PS<sup>1-4)</sup>. However, the VSD in this instance was mostly perimembranous type<sup>1,2)</sup>. And the remote muscular VSD was thought to be anatomic contraindications for the intracardiac rerouting<sup>3)</sup>. The challenge in this patient is to decide preoperatively and with certainty whether this can be actually carried out. And the keypoint in the surgical decision-making is the feasibility of an intraventricular repair, and the obstacles of the left ventricle-to-aorta tunnel are the size of VSD, the valve apparatus of tricuspid valve, straddling of valve, troublesome trabeculation of right ventricle.

The VSD enlargement may be difficult, dangerous, and causing wide exposure of trabeculation of the right ventricle in remote muscular inlet type VSD. However, in our experience, the Rastelli-type operation was feasible, even in the presence of remote muscular inlet-type VSD.

Wide and long left ventricle-to-aorta intraventricular rerouting tunnel and satisfactory decompression of the right ventricle could be obtained without interfering with the tricuspid valve function and the right ventricular function.

### References

1. Kim YJ, Song H, Lee JR, Rho JR, Suh KP. *Lecompte procedure for complete transposition of the great arteries with ventricular septal defect and pulmonary stenosis*. Ann Thorac Surg 1994;57:876-9
2. Lecompte Y, Neveux JY, Leca F, et al. *Reconstruction of the pulmonary outflow tract without prosthetic conduit*. J Thorac Cardiovasc Surg 1982;84:727-33.
3. Vouhe PR, Tamisier D, Leca F, Ouaknine R, Vernant F, Neveux JY. *Transposition of the great arteries, ventricular septal defect, and pulmonary outflow tract obstruction. Rastelli or Lecompte procedure?* J Thorac Cardiovasc Surg 1992;103:428-36.
4. Niinami H, Imai Y, Sawatari K, Hoshino S, Ishihara K, Aoki M. *Surgical management of tricuspid malinsertion in the Rastelli operation. Conal flap method*. Ann Thorac Surg 1995;59:1476-80