

# 흉벽의 임파관종

김 영 진\* · 이 철 주\* · 소 동 문\* · 김 정 태\* · 강 준 규\* · 홍 준 화\*

=Abstract=

## Lymphangioma of the Chest Wall

Young Jin Kim, M.D.\*, Cheol Joo Lee, M.D.\*, Dong Moon Soh, M.D.\*,  
Jung Tae Kim, M.D.\*, Joon Kyu Kang, M.D.\*, Joon Hwa Hong, M.D.\*

Lymphangioma(or cystic hygroma) of the chest wall is rare case. We experienced one such case in a 16-year-old girl who complained of a large recurrent mass on her right upper posterolateral chest wall which had developed several years ago. The diagnosis was made following a physical examination, chest magnetic resonance imaging(MRI), and radio isotope (RI) lymphangiography and was confirmed by a histopathological examination. We performed total excision of the lesion followed by a repeated sclerosing therapy with intralesional injection of Vibramycin.

(Korean J Thorac Cardiovasc Surg 1999;32:855-7)

Key word : 1. Lymphangioma  
2. Thorax neoplasm

### CASE REPORT

A 15-year-old girl was admitted having a recurrent, growing, non-tender mass on her right posterolateral aspect of the chest wall persisting for 2 years. Resections of the mass had been performed twice before admitting her to our hospital, and the histological examination had revealed lymphangioma. On physical examination, the lesion was measured to be about 11 cm in length and 5 cm in width. It was soft, poorly circumscribed and covered with skin which had a few small bullous lesions. The patient was in relatively good health. For evaluating the mass, magnetic resonance imaging (MRI) and radio isotope (RI) lymphangiography were performed. The MRI showed a multiloculated cystic lesion with high intensity signals on T2 weighted images. These findings were compatible with cystic lymphangioma, but the RI showed nothing significant. We performed a wide excision of the multilobulated mass

along its previous scar, which had a thin capsule filled with lymphatic fluid. The draining tube was removed on the third post-operative day. The pathologic diagnosis was lymphangioma composed of a bundle of skeletal muscle and fibrous tissue with several dilated vessels. During the outpatient follow-up period, there was recurrent swelling with fluid collection inside. Repeated fluid aspiration and sclerosing therapy with Vibramycin (500 mg per time) cleared up her condition within 2 months.

### DISCUSSION

Lymphangiomas or cystic hygromas are commonly seen in children and result from a failure of lymphatic drainage into the venous system due to atresia or insufficiency of efferent lymphatic channels. Neck and axillary regions are most commonly affected, while the condition is rarely found in the mediastinum, abdominal viscera, retroperitoneal space,

\*아주대학병원 흉부외과

Department of Thoracic and Cardiovascular Surgery, School of Medicine, Ajou University

논문접수일 : 98년 9월 13일 심사통과일 : 98년 11월 17일

책임저자 : 김 영진, (442-749) 경기도 수원시 팔달구 원천동 산 5번지. 아주대학병원 흉부외과, (Tel) 0331-219-5210, (Fax) 0331-219-5215  
본 논문의 저작권 및 전자매체의 지적소유권은 대한흉부외과학회에 있다.

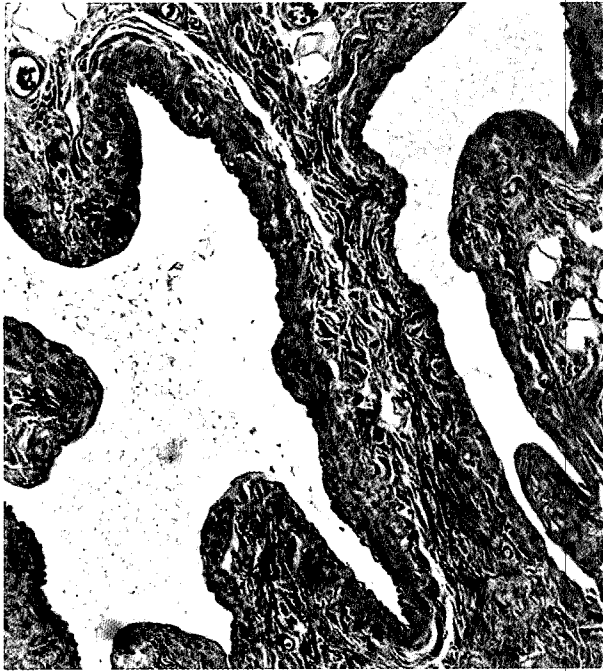


Fig. 1. Histologic findings of lymphangioma: Irregular dilated lymphatic vascular structures were found inside. (H&E stain, X100 )

bones, pelvis, inguinal area, scrotum, arm, and chest wall. Surgical treatment of lymphangioma may be complicated in some rare cases by its wide and fine microinvasion.

Lymphangiomas or cystic hygromas are considered to be soft, cystic tumors first described by Redenbacher in 1828. In 1959, the first report of a lymphangioma of the chest wall was made by Fuller and Conway<sup>1)</sup>. The incidence is quite low, and no sexual discrepancy of incidence<sup>2)</sup> exists. Most of these lesions are detected in the younger groups with about 65% to 75% diagnosed at birth, and 80% to 90% at two or three years of age<sup>3)</sup>. In our case, the patient developed a small chest wall mass at one year old which very slowly continued to grow until she was 16 years old. The most commonly affected sites are the neck and axilla. A review of the literature showed that about 75% of the lymphangiomas occurred in the neck and 20% in the axillary region. Other locations include the mediastinum, retroperitoneal space, abdominal viscera, bones, pelvis, inguinal area, and chest wall<sup>2-6)</sup>. The reasons for this condition are congenital malformations of the lymphatic system resulting from a failure of the lymphatic sac to join the venous drainage system. A cystic formation occurs due to the absence of communication between the lymphatic and the venous systems. According to Kennedy's<sup>1)</sup> classification of lymphangiomas consisting of superficial cutaneous, cavernous, cystic hygroma, and diffuse systemic lymphangioma, our case belongs to the cavernous type. A

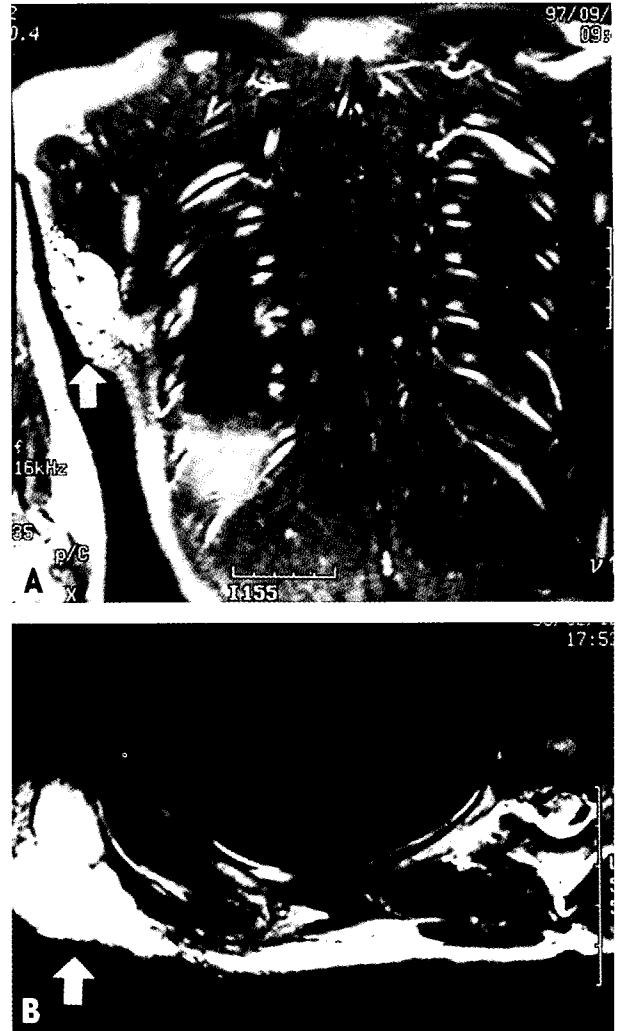

Fig. 2. Chest magnetic resonance findings (A; coronal section, B; transverse section) in T2-weighted image: Multilobulated high signal intensity mass was located between the subcutaneous layer and the muscle layer (arrow).

cavernous lymphangioma is made up of dilated lymphatic channels that are dispersed throughout one or more epidermal layers as well as the subcutaneous layer. The most common presenting symptom and sign is a mass which is characteristically multilobulated and soft. There are several methods for diagnosing lymphangiomatous lesions. Simple radiographs have limited value. Transillumination can help to differentiate cystic lesions from solid masses. Ultrasonography can reveal multilobulated cystic masses containing multiple septa. Computed axial tomography can show a thin-walled cystic mass filled with water-like dense material. Magnetic resonance imaging can be used to demonstrate the relationship of the lesion to surrounding

structures, with high intensity signals on T2 weighted images. Therefore, MRI is considered the imaging modality of choice<sup>7)</sup>. Lymphoma and deep hemangioma are diseases of differential diagnosis<sup>3)</sup>. The treatment of choice is meticulous, complete excision after diagnosis has been made because severe complications such as infection, hemorrhage or compression of adjacent structures may cause a dangerous condition. However a thin wall or a poorly delineated the mass may make complete removal an impossible task. Many postoperative complications may occur including recurrence, infection, swelling and serous fluid collection which would necessitate prolonged drainage, damage to the surrounding structure, and cosmetic problems<sup>5)</sup>. Other adjuvant treatments have been used such as radiotherapy, injection of sclerosing agents, carbon dioxide laser, and in cases involving asymptomatic patients, some surgeons have recommended conservative management with close observations.

## REFERENCES

1. Kennedy TL. *Cystic hygroma-lymphangioma: a rare and still unclear entity.* Laryngoscope 1989;99:1-10.
2. David K. Nosan, MD, David S. Martin, MD, John A. Stith, MD. *Lymphangioma presenting as a delayed posttraumatic expanding neck mass.* Am J Otolaryngol 1995;16:186-9.
3. Marcos Ardenghy, MD, Yoko Miura, MD, Rodney Kovach, MD, Julio Hochberg, MD. *Cystic hygroma of the chest wall : A rare condition.* Ann Plast Surg 1996;37:211-3.
4. Shivdev Singh, MD, M. L. Baboo, MD, I. C. Pathak, MD. *Cystic lymphangioma in children: Report of 32 cases including lesions at rare sites.* Surgery 1971;69(6):947-51.
5. Ninh TN, Ninh TX. *Cystic hygroma in children: A report of 126 cases.* J Pediatr Surg 1974;9(2):191-95.
6. Sheth S, Nusbaum AR, Hutchings GM, Sanders RC. *Cystic hygroma in children: sonographic-pathologic correlations.* Radiology 1987;162(3):821-4.
7. Siegel MJ, Glazer HS, St. Amour TE, et al. *Lymphangiomas in children; MR imaging.* Radiology 1989;170:467-70.

### =국문초록=

흉벽의 임파관종은 전 세계적으로 매우 드물게 보고 되어있다. 본원에서는 16세의 여자환자로 우측 상부 후측방 흉벽에 반복적으로 나타나는 거대 종괴를 주소로 내원한 임파관종 환자를 치험하였다. 진단은 이학적 검사와 흉부 핵자기공명 촬영, 동위원소 임파관 촬영술을 실시하였으며 조직검사로 확진하였다. 치료는 외과적 완전 절제를 하였으며 술후 반복적 림프액의 유출로 수술부위에 vibramycin을 주사하였다.

- 중심단어 : 1. 임파종  
2. 흉곽 종양