

/
/

I. ⁹⁻¹¹⁾(longitudinal prospective study)

1) , 가 가 .

2). 8
95 %
3).

2 ¹¹⁾ ,
6 6 ,
6 24
가
가
가

4). 가
20 가 ,

5). ¹²⁾ Bengazi ¹¹⁾

가 ,
 ,

6, 7). ,
(,) 가
8). ¹³⁾ Adell ⁹⁾

. 6

0.7mm 0.6mm 2 1
 0.4 mm 가 ,
 Apse 10) 가
 가 14 - 16), 34
 17, 18) 20 67
 가 19) 7 , 14
 39 , 1
 1 3 7
 가 가 가 11 ,
 가 가 10
 (31) 가 (17
) (11) , 3
 가 가
 , 6 가
 가? 가) (25 , 6
 , 2 3
 가

(De Trey
 Zinc cement, De Trey Div, Dentsply Ltd,
 England) 20).

2.
 ll. ()
 1. (1)
 가 ,
 (retro -
 spective, longitudinal)
 (SIM
 Clinic) , • ()
 ;

0.5 mm

• ; 가 , Trentini 22)

가

0.5 mm

• ; 가 (*)

0.5 mm

21).

• (Jemt¹⁸); , 가 0; 가 . / / 3 가 1;

(10

가 . 2; 3)

$$\boxed{= \frac{\quad}{\quad} \times \quad}$$

1

가

. 3; 가 0.14(0.31) ,
. 4; 가 . (p=0.84)
0.14(0.23)

(2)

1. (mm), (mm),

(mm)	10.9(1.6)	11.0(1.6)
(mm)	0(1.7)	0.7(1.3)*
(mm)	2.7(1.1)	3.3(1.1)*
(mm)	2.8(1.2)	3.7(0.9)**

*p<0.05, **p<0.01;

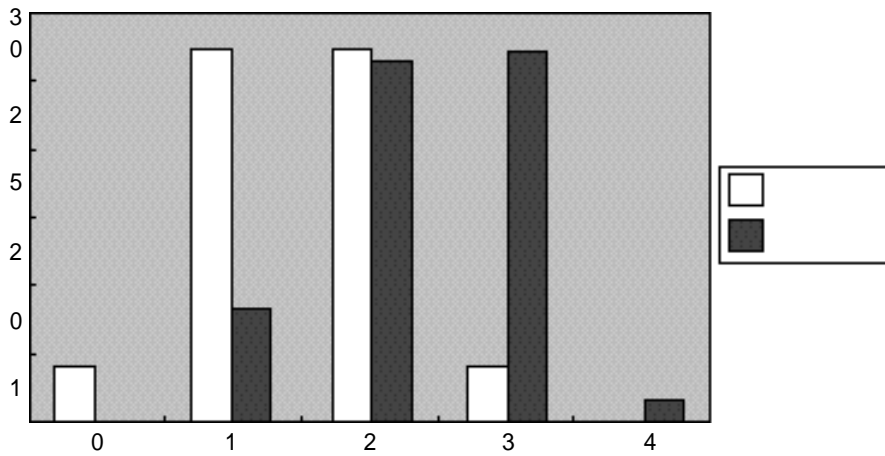
1.4(0.7) 2.3(0.8)***
 1.6(0.7) 2.4(0.7)***

***p<0.001;

3 () ()

0 1 2 3 4

3	0	14	5	13	13	1	12	0	1
1	0	13	3	14	13	3	15	0	0
4	0	27	8	27	26	4	27	0	1



1.

(Abacus Concepts, Inc., Berkeley, CA, 1995)

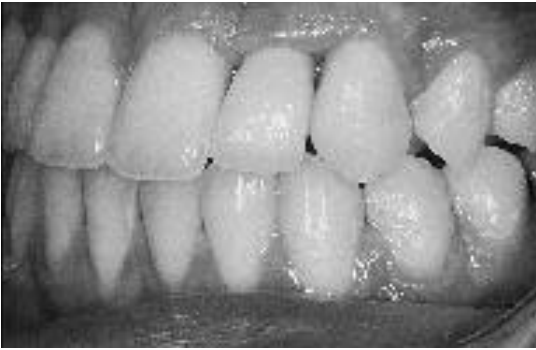III.

가

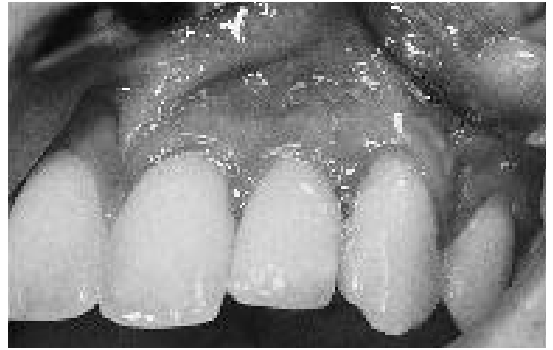가 Wilcoxon signed rank test

가 p<0.05

StatView 4.51



(가)



()

1. 21

(가), 52

, ()

1

1

52

(0.1mm)

3

(가)

()

가

(0.7mm)
($p < 0.05$).

가

(0.6mm)

(0.9mm)

가

($p < 0.01$).

가 ()

()

가 ($p < 0.001$).

IV.

(2)

1(27)

2(27)

2(26)

3(27)

(3).

(1).

2

19)

, 1 3

(0.7mm, p<0.05) . Harris²⁵⁾가
 22). 4 72 0.8 mm
 가(creeping attachment)
 가 , (Bråhemark system) , 가
 가
 Trentitni ²²⁾
 (Trentitni ²²⁾ 1995: 0.06 - 0.17, .
 0.65 - 0.77, : 0.14,
 0.31). 가 .
 (0.1mm).
 Adell ¹⁰⁾ 39
 1.7mm, ¹⁶⁾
 24 Bengazi ¹¹⁾ .
 0.5mm 가 ,
 가 , (0.7mm)가 가(0.6 -
 , 0.9mm) .
 가 1.5
 가 2.3
²³⁾ (3 - 5 mm)
 10 - 11 0.6 - 1.1mm 4
 , (7%) .
 , 27 (45%)가
 Jemt¹⁹⁾
 가
 가 3 (1.4 - 2.3 , 1.4 - 2.5,
 1.6 - 2.4, 1.5 - 2.5) Jemt
 가 3
 Becker ²⁴⁾ (39)
 (18) .
 가

가 26)

V.

가 가

가 20 (31)

가

12)

(,)

(0.1mm)

가

26)

가

가

(p<0.05).

(0.7mm),

가 (p<0.001).

27),

가 가 .

prospective longitudinal study)

(

가 가

28)

29)

가

VII.

1. Adell, R., Lekholm, U., Rockler, B., Brånemark, P-I. : " A 15 - year study of osseointegrated fixtures in the partially edentulous jaw ", Int. J. Oral Sur., 10 : 387 - 416, 1981.
2. Jemt, T., : " Modified single and

short - span restorations supported by osseointegrated fixtures in the partially edentulous jaw ", J. Prosthet. Dent., 55 : 243 - 247, 1986.

3. Esposito, M., Hirsh, J - M., Lekholm, U., Thomsen, P. : " Biological factors contributing to failures of osseointegrated oral implants(1). Success criteria and epidemiology ", Eur. J. Oral Sci., 106 : 527 - 551, 1998.
4. Andersson, B. : " Implants for single - tooth replacement. A clinical and experimental study on the Brånemark CeraOne System ", Swedish Dental Journal, supplement 108, 1995.
5. Öwall, B., Käyser, A. F., Carlsson, G. E. : " Prosthodontics around the world " In:Öwall, B., Käyser, A. F., Carlsson, G. E.(eds.) Prosthodontics. Principles and management strategies " 1st ed., London, Mosby - Wolfe, pp. 9 - 19, 1996.
6. Berglundh, T., Lindhe, J., Ericsson, I., Marinello, C., Liljenberg, B., Thomsen, P. : " The soft tissue barrier at implants and teeth ", Clin. Oral Impl. Res., 2 : 81 - 90.
7. Berglundh, T., Lindhe, J., Jonsson, K., Ericsson, I. : " The topography of the vascular systems in the periodontal and peri - implant tissues in the dog ", J. Clin. Periodontol., 21 : 189 - 193, 1994.
8. Listgarten, M. A., Lang, N. P., Schroeder, H. E., Schroeder, A. : " Periodontal tissues and their counterparts around endosseous implants ", Clin. Oral Impl. Res., 2 : 1 - 19, 1991.
9. Adell, R., Lekholm, U., Rockler, B.,

Brånemark, P - I., Lindhe, J., Eriksson, B., Sbordone, L. : " Marginal tissue reactions at osseointegrated titanium fixtures; (I). A 3 - year longitudinal prospective study " , Int. J. Oral Maxillofac. Surg., 15 : 39 - 52, 1986.

10. Apse, P., Zarb, G. A., Schmitt, A., Lewis, D. W. : " The longitudinal effectiveness of osseointegrated dental implants. The Toronto Study: Peri - implant mucosal response ", Int. J. Periodont. Restor. Dent., 11 : 95 - 111, 1991.
11. Bengazi, F., Wennström, J. L., Lekholm, U. : " Recession of the soft tissue margin at oral implants " Clin. Oral Impl. Res., 7 : 303 - 310, 1996.
12. Wennström, J. L. : " Mucogingival considerations in orthodontic treatment " , Seminars in Orthodontics, 2 : 46 - 54, 1996.
13. Berglundh, T., Lindhe, J. : " Dimensions of the peri - implant mucosa. Biological width revisited ", J. Clin. Periodontol. 23 : 971 - 973, 1996.
14. Israelson, H., Plemons, J. M. : " Dental implants, regenerative techniques, and periodontal plastic surgery to restore maxillary anterior esthetics ", Int. J. Oral Maxillofac. Implants, 8 : 555 - 561, 1993.
15. Palacci, P.: " Peri - implant soft tissue management: Papilla regeneration technique " , In: Palacci, P., Ericsson, I., Engstrand, P., Rangert, B.(eds). Optimal Implant Positioning & Soft Tissue Management for the Brånemark System, Chicago,

Quintessence, 59 - 70, 1995.

16. Becker, W., Becker, E. B. : “ Flap designs for minimization of recession

adjacent to maxillary anterior implant sites : A clinical study “ Int. J. Oral Maxillofac. Implants, 11 : 46 - 54,

1996.

17. Neale, D., Chee, W. W. L. : " Development of implant soft tissue emergence profile: A technique " J. Prosthet. Dent., 71 : 364 - 368, 1994.
18. Breeding, L. C., Dixon, D. L. : " Transfer of gingival contours to a mast cast " , J. Prosthet. Dent., 75 : 341 - 343, 1996.
19. Jemt, T. : " Regeneration of gingival papillae after single - implant treatment " , Int. J. Periodont. Restor. Dent., 17 : 327 - 333, 1997.
20. Andersson, Brånman, P., Carlsson, L., Brå-emark, P - I. : " A new Brånemark single tooth abutment: Handling and early clinical experiences " , Int. J. Oral Maxillofac. Implants, 7 : 105 - 111, 1992.
21. Olsson, M., Lindhe, J., Marinello, C. P. : " On the relationship between crown form and clinical features of the gingiva in adolescents " , J. Clin. Periodontol., 20 : 570 - 577, 1993.
22. Trentini, C. M., Moriarty, J. D., Phillips, C., Camilla Tulloch, J. F. : " Evaluation of the use of orthodontic records to measure the width of keratinized tissue " , J. Periodontol., 66 : 438 - 442, 1995.
23. Lindhe, J., Nyman, S. : " Alterations of the position of the marginal soft tissue following periodontal surgery " , J. Clin. Periodontol., 7 : 525 - 530, 1980.
24. Becker, W., Lekholm, U., Dahlin, C., Becker, B. E., Donath, K. : " The effect of clinical loading on bone regenerated by GTAM barriers: A study in dogs " Int. J. Oral Maxillofac. Implants, 9 : 305 - 313, 1994.
25. Harris, R. J. : " Creeping attachment associated with the connective tissue with partial - thickness double pedicle graft " , J. Periodontol. 68 : 890 - 899, 1997.
26. Smith, R. G. : " Gingival recession; Reappraisal of an enigmatic condition and a new index for monitoring " , J. Clin. Periodontol., 24 : 201 - 205, 1997.
27. King, K. O., Sadler, J. F., Higgason, J. D., Towner, J. D. III, Pennel, B. M. : " The effects of angulation upon pre - and postoperative photographs " , J. Periodontol. 34 : 139 - 141, 1963.
28. Andersson, B., Brånman, P., Widmark, G., Waas, A. : " Anterior tooth replacement with implants with a narrow alveolar ridge form " , Clin. Oral Impl. Res., 4 : 90 - 98, 1993.
29. Paolantonio, M., di Murra, C., Cattabriga, A., Cattabriga, M. : " Subpedicle connective tissue graft versus free gingival graft in the coverage of exposed root surfaces; A 5 - year clinical study " , J. Clin. Periodontol., 24 : 51 - 56, 1997.

- Abstract -

Alterations of the soft tissue
dimensions
around implant-supported single-
tooth replacements
in the maxillary anterior region
– A retrospective longitudinal study –

Moon - taek Chang

Department of Periodontology/Institute of
Oral Bio - science, College of Dentistry,
Chonbuk National University

Departments of Periodontology and
Prosthetic Dentistry, Faculty of odontology,
Göteborg University, Sweden

This study was performed to investigate the soft tissue changes around single implant - supported crowns during follow - up periods.

Twenty patients(31 implants) whose single missing tooth in the maxillary anterior region had been replaced with an single implant - supported crown were recruited for the study. Crown length, soft tissue level and papilla height at the single implant - supported crowns were measured at follow - up examination and calculated from the slides taken at time of crown placement. as well Papilla index was scored from the slides taken at the time of crown placement and follow - up examination.

A very little amount of recession occurred and the soft tissue level moved

more apically and the papilla height increased significantly($p<0.01$). Especially, both mesial and distal papilla index at single implant - supported crowns increased significantly during follow - up periods($p<0.001$). When the two slides taken at the time of crown placement and follow - up were compared simultaneously, except one site, papillae size increased at all sites.

From the results of the study, the interdental papillae at the single implant - supported crowns seemed to regenerate significantly and their crown margins were stable during follow - up periods. Hence it is indicated that various surgical interventions at an early stage to enhance soft tissue esthetics around single implants may be unnecessary.

Key words; single implants - soft tissue alterations - recession - interdental papillae