Histologic Alterations in the Liver of Black Bengal Goats Infected with *Fasciola gigantica*

M. M. R. Howlader[1] and M. M. Huq[2]
Bangladesh Livestock Research Institute, Savar, Dhaka 1341, Bangladesh

ABSTRACT: A total of 77 Black Bengal goats (67 females and 10 males) of 3.5 to 5.0 years old between 18 and 20 kg liveweights were used in this study. The whole liver with gall-bladder from respective carcass was collected at slaughter following fecal and postmortem examinations. Tissue sections of all lobes of each liver were prepared and stained with hematoxylin and eosin following a standard procedure. Results confirmed the presence of flukes surrounded by fibrous capsule in the liver. All the animals were suffering from chronic *Fasciola gigantica* infections. The blood vessels in most of the liver tissue were thickened due to proliferation of fibrous tissue around them. Focal infiltration of lymphocytes in the lobules, patches of focal accumulation of neutrophils and eosinophils were found in all the liver tissue. Proliferations of new bile ductules in the hepatic trinity around the bile ducts that were clogged by the flukes were also observed in most tissue sections.
(**Key Words**: Black Bengal Goat, *Fasciola gigantica*, Histologic Alterations, Liver)

INTRODUCTION

Fasciola gigantica infection in ruminants is considered to be one of the most important parasitic diseases in Bangladesh causing losses in lives and/or productivity (Bhuyan, 1970; Rahman et al., 1972; Rahman and Razzak, 1973; Garrels, 1975; Rahman and Mian, 1976). The disease was first reported in the domesticated ruminants of this land in 1954 (Kendall, 1954). *F. gigantica* infection was found in 14.6% of sheep in some areas of Bangladesh (Bhuyan, 1970). The malady in Black Bengal goats is known to be wide spread in some areas of the country (Qadir, 1981; Rahman, 1990). The economic loss due to condemnation of *F. gigantica* affected liver of ruminants is enormous in this country (Kendall, 1954; Bhuyan, 1970). Asian Development Bank (ADB) reported that 50% reduction in milk production, growth rate, production loss and generation loss incurred due to fascioliasis in ruminants in Bangladesh (ADB, 1984). A load of 42 to 139 *F. gigantica* might cause death of a goat (Nooruddin, 1977). Migration of immature flukes in the liver produces migratory tracts within which there is hemorrhage and necrosis (Soulsby, 1982). If the animal survives this stage, healing and regeneration of these lesions results in a considerable distortion of the hepatic architecture (Soulsby, 1982). Although, some reports on the histologic alterations in the liver of *F. hepatica* infected sheep are available in the literature but very little of such information is known in goats. Therefore, this paper describes the histologic alterations in the liver of Black Bengal goats naturally infected with *F. gigantica*.

MATERIALS AND METHODS

Liver and gall-bladder were collected from 77 goats (67 females and 10 males) of 3.5 to 5.0 years old between 18 and 20 kg liveweights which were slaughtered at Mymensingh abattoir and Bangladesh Agricultural University market abattoir. Animals were procured by the butcher of the respective slaughter houses. Fecal samples were collected and examined on the day before the animals were slaughtered. Feces were collected from the suspected animals based on the general poor conditions, rough hair coats and semisolid/loose feces. Each study animal was given an identification number before fecal sample collection. After collection, fecal samples were immediately brought to the laboratory and examined using Stoll's ova counting technique. After fecal examination only the *F. gigantica* positive animals were selected for this study. Animals having mixed infections were not included in this study. Livers with gall-bladders were collected from them at slaughter. At postmortem examination almost all the flukes were found in the

[1] Address reprint requests to M. M. R. Howlader.
[2] Department of Parasitology, Bangladesh Agricultural University, Mymensingh, Bangladesh.
Received February 14, 1996; Accepted August 30, 1996

ventral lobe of the liver of all animals. Representative portions from the ventral and other lobes of the liver were fixed in 10% formol-saline for histological examinations. From each liver six tissue sections were prepared following the paraffin method, cut at 6 micron thickness and stained with hematoxylin and eosin (Luna, 1968). Flukes were identified using the key of Yamaguti (1958) and all were found to be *F. gigantica*.

RESULTS AND DISCUSSION

Alterations in the liver in sub-acute infection by immature flukes

In 36 livers both immature and mature flukes were found. Histologic examination of the liver showed that there was focal infiltration of lymphocytes in the lobules. Patches of focal accumulation of neutrophils and eosinophils were also observed in the liver tissue. Some plasma cells and macrophages were also observed in the affected area (figure 1). This result agreed with the work of Bitakaramire and Bwangamoi (1969) in calves where they found lymphocytes, mast cells and eosinophils in the necrotic smooth muscle of the bile ducts. In this case it was assumed that macrophages were chemotactically attracted not only to microbial products of secondary infections, but also to damaged cells, especially dead hepatocytes and dead neutrophils. Neutrophils not only reached and attacked foreign material first but in dying they served to attack macrophages to the site of invasion (Tizard, 1987). The interpretation of the invasions of eosinophils indicated the parasite burden of the animals. On the other hand, invasion of lymphocytes indicated that a cellular response was taking place in the infected animals but the process was too slow to develop.

Alterations in the liver in chronic infection by mature flukes

In 41 livers only mature flukes were found. Histological examination of tissue sections of the liver infected with *F. gigantica* proved that the flukes were present in the liver tissue which were surrounded by fibrous capsule (figure 2). This fibrosis helped in restoring the liver architecture and resulted in a straightening of hepatic plates which counteracted the distortion produced by other hepatic fibrous capsule formation (Soulsby, 1982). Rushton and Murray (1977) found similar findings in sheep infected with *F. hepatica*. They reported that fibrosis occurred in chronic infestation from week 20 postinfection onwards, at this time regeneration of liver tissue was greatest, which contributed much to the development of fibrous tissue. The fibrosis in this study resembled the observation of Bitakaramire and Bwangamoi (1969) in *F. gigantica* infected calves. The blood vessels in the liver tissue were thickened due to proliferation of fibrous tissue around them (figure 3). In chronic cases more proliferation of fibrous tissue in the area of hepatic trinity and periphery lobules was observed. The findings in this study were consistent with the reports of Murray (1973) who studied sheep infected with *F. hepatica*. He described the tissues around some small portal veins as edematous, and the veins became partially or totally occluded by the pressure created by the edema and that excreted by the cells. This resulted in a marked

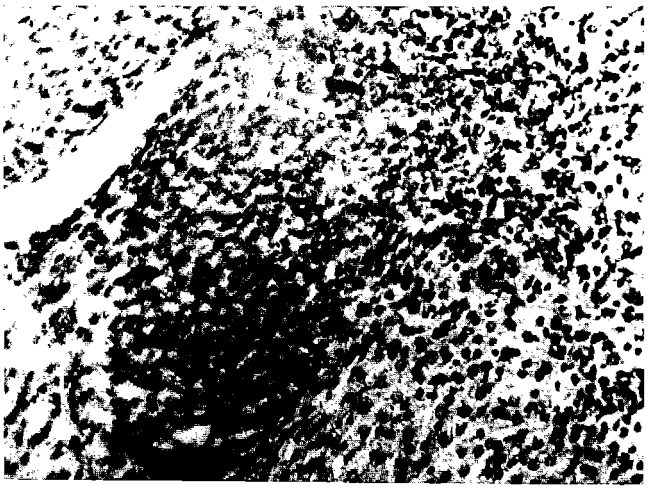

Figure 1. Section of liver with fascioliasis showing focal accumulation of lymphocytes, eosinophils mixed with some neutrophils, plasma cells and macrophages. 10x; H & E.

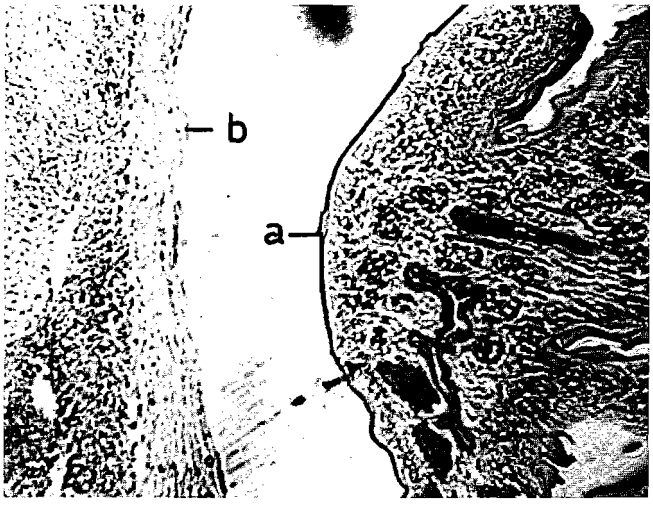

Figure 2. Section of liver with fascioliasis showing the parasite (a) and fibrous capsule (b) 10x; H & E.

increase in intrahepatic blood pressure that caused compensatory fibrosis around the tiny blood vessels. Subsequently, the arteries in the liver became thickened and tortuous.

Figure 3. Section of liver with fascioliasis showing the thickened blood vessels due to proliferation of fibrous tissues. 10x; H & E.

In some animals, well defined abscesses were found in the liver parenchyma (figure 4). The abscess containing the pus was produced by necrotized hepatocytes and damaged neutrophils. The major function of neutrophils was the destruction of foreign material through the process of phagocytosis. Fibrous tissue was assumed to be laid down surrounding the damaged cell. Rushton and Murray (1977) reported that monolobular fibrosis was greatest in the ventral lobe of the liver where fluke migration was maximal. In this study, almost all the flukes were recovered from the ventral lobe of the liver and in histopathology, most damages were also observed in the same lobe of the liver.

Figure 4. Section of liver with fascioliasis showing well defined abscess in the liver parenchyma. 10x; H & E.

The most striking features found were the proliferation of new bile ductules in the hepatic trinity around the bile ducts that were clogged by the flukes (figure 5). This finding revealed that the biliary system in the liver had the ability for autogenic compensation through generation of new ducts. However, this may not be able to exert the optimal function like the original ones that were destroyed due to infestations. These findings were consistent with those of Arora and Lyer (1973) in sheep and goats infected with the same parasite in India.

Figure 5. Section of liver with fascioliasis showing proliferation of new bile duct. 10x; H & E.

The life span of *F. gigantica* in a single primary infection is related to the reaction of the host, in the form of fibrosis and calcification in the bile ducts. The severity of these pathological changes probably depended on the number of flukes that were present and the size of liver and host species and breed (Hammond and Sewell, 1975). In this study, fibrosis and abscess formation were observed, however, no calcification was seen in any case. Hammond (1973) found fibrosis of the bile ducts but no calcification in sheep killed 203 days after infection with *F. gigantica*. This difference was probably due to the small numbers of flukes that were recovered from the test animals. The severity of the disease in the form of fibrosis and abscess formation in chronic infection revealed the primary infection of the animals with the flukes. It may be concluded that *F. gigantica* could damage the liver of

Black Bengal goats through fibrosis and abscess formation in chronic infections.

ACKNOWLEDGEMENT

We gratefully acknowledge the help of Dr. Priya Mohan Das, Department of Pathology, Bangladesh Agricultural University, Mymensingh, Bangladesh for histopathological interpretation of *Fasciola* infected livers.

REFERENCES

Anon, 1984. Report Asian Development Bank, Bangladesh.

Arora, R. C. and P. K. R. Lyer. 1973. Studies on the pathology of fascioliasis in sheep and goats. Indian J. Anim. Sci. 43:720-723.

Bhuyan, M. A. 1970. A survey of helminths parasitizing the livers of domesticated ruminants in East Pakistan. M. Sc. (Vet. Sc.) Thesis, East Pakistan Agricultural University, Mymensingh.

Bitakaramire, P. K. and O. Bwangamoi. 1969. Experimental infection of calves with *Fasciola gigantica*. Expt. Parasit 25:353-357.

Carrels, G. 1975. Castrointestinal parasitic infestation of cattle in some villages of Dhaka and Tangail Districts in Bangladesh. Bangladesh Vet. J. 9:9-10.

Hammond, J. A. 1973. Experimental chronic *Fasciola gigantica* infection in sheep. Trop. Anim. Hlth Prod. 5:12-21.

Hammond, J. A. and M. M. H. Sewell. 1975. Experimental infections of cattle with *Fasciola gigantica* Numbers of parasites recovered after varying periods of infection. Trop. Anim. Hlth Prod. 7:105-113.

Kendall, S. B. 1954. Fascioliasis in Pakistan. Ann. Trop. Med. Parasitol. 48:307-313.

Luna, L. G. 1968. Manual of Histologic Staining Methods of the Armed Forces Institute of Pathology. Third Edition. McCraw Hill Book Co., New York. pp. 12-46.

Murray, M. 1973. Fascioliasis: Pathology. Helminth Diseases of cattle, sheep and horses in Europe, edited by C. M. Urquhart and J. Armour, Glasgow: MacLehouse.

Nooruddin, M. 1977. Clinico-pathological studies of *Fasciola gigantica* infections in goat. M. Sc. Thesis, Bangladesh Agricultural University, Mymensingh, Bangladesh.

Qadir, A. N. M. A. 1981. A preliminary study on the epidemiology of fascioliasis in goats. Bangladesh Vet. J. 15:7-12.

Rahman, A., K. M. Ali and A. Rahman. 1972. Incidence of diseases of cattle in Mymensingh. Bangladesh Vet. J. 6:25-30.

Rahman, M. H. and A. Razzak. 1973. Incidence of helminth parasites infecting cattle in the Kotwali thana of Comilla. First Bangladesh Vet. Conference, Mymensingh.

Rahman, A., M. U. Ahmed and A. S. Mian. 1976. Studies on the diseases of goats in Bangladesh, Mortality of goats under farm and rural conditions. Trop. Anim. Hlth Prod. 8:90.

Rahman, A. Z. 1990. Pathological investigation on the mortality of goats in Mymensingh. M. Sc. Thesis, Bangladesh Agricultural University, Mymensingh, Bangladesh.

Rushton, B. and M. Murray. 1977. Hepatic pathology of a primary experimental infection of *Fasciola hepatica* in sheep. J. Comp. Path. 87:459-470.

Soulsby, E. J. L. 1982. Helminths, Arthropods and Protozoa of Domesticated Animals. Seventh Edition, Bailliere Tindall and Cassell, London. pp. 785-792.

Tizard, I. 1987. Veterinary Immunology: An Introduction. Third Edition. W. B. Saunders Company, London.

Yamaguti, S. 1958. Systema Helminthum, Vol. 1, Interscience Publishers, Inc. New York, pp. 839-841.