

## Expression patterns of proliferating cell nuclear antigen in the small intestine of mice infected with *Metagonimus yokogawai* and *Metagonimus* Miyata type

Jae-Ran YU<sup>1)\*</sup>, Nahye MYONG<sup>2)</sup> and Jong-Yil CHAI<sup>3)</sup>

Department of Parasitology<sup>1)</sup>, College of Medicine, Kon-Kuk University, Chungju 380-701, Department of Pathology<sup>2)</sup>, College of Medicine, Dan-Kuk University, Chonan 330-715, and Department of Parasitology and Institute of Endemic Diseases<sup>3)</sup>, Seoul National University College of Medicine, Seoul 110-799, Korea

**Abstract:** Genus *Metagonimus* has been a subject of taxonomic debates for several years. In morphological aspects, *M. yokogawai* has been thought to have three subtypes, namely Yokogawa type (*M. yokogawai* in strict sense), Miyata type and Koga type. But differences in the intestinal pathology induced by these subtypes have not been studied yet. In this study we compared the pathological reactions induced by *M. yokogawai* and *Metagonimus* Miyata type using proliferating cell nuclear antigen (PCNA) index. Metacercariae (Mc) of *M. yokogawai* were collected by artificial digestion of *Plecoglossus altivelis* and Mc of *Metagonimus* Miyata type were collected from *Zacco platypus*. Three hundreds Mc of each species were infected orally to ICR mice. The mice were sacrificed at 3, 6, 10, 16 and 23 days after infection and the small intestines were resected into three portions (proximal, middle, and distal). Immunohistochemical staining for PCNA was done using PC-10 (DAKO-PCNA, CA, USA). The PCNA indices in *M. yokogawai* infected group on the 6th and 23rd day after infection were lower than in the control and Miyata type infected groups ( $p < 0.05$ ) from all of the three intestinal regions. On the other hand, the control group and *Metagonimus* Miyata type infected group did not make any differences in PCNA indices. The villus/crypt (V/C) ratio was also decreased significantly in *M. yokogawai* infected mice but not in *Metagonimus* Miyata type infected ones. It is suggested that *M. yokogawai* induce villous atrophy through a decrease in the cell proliferation at the crypt. The results of this study suggested that *M. yokogawai* induce more serious intestinal pathology than *Metagonimus* Miyata type.

**Key words:** *Metagonimus yokogawai*, *Metagonimus* Miyata type, pathology, PCNA

### INTRODUCTION

*Metagonimus yokogawai* is one of the well known intestinal trematodes in Korea (Chai and Lee, 1990). High infection rates are still

maintained in several endemic areas (Chai *et al.*, 1993; Yu *et al.*, 1994). Morphologically, *M. yokogawai* have been thought to have several subtypes, such as *Metagonimus* Miyata type and *M. Koga* type. They have minor differences in such points as follows: location of testes, distribution of uterine tubules, egg sizes, and end point of vitelline follicles (Saito, 1984).

Chai *et al.* (1993) suggested that the most metagonimiasis patients in inland endemic areas in Korea were not due to *M. yokogawai*

• Received 25 August 1997, accepted after revision 6 October 1997.

\* Corresponding author (e-mail: jaeran.yu@kcucc.konkuk.ac.kr)

but to *Metagonimus* Miyata type or *M. takahashii*. In view of clinical symptoms, metagonimiasis by *M. yokogawai* could evoke severe intestinal troubles such as abdominal pain, watery diarrhea for several days, and weight loss (Chai *et al.*, 1989). Whereas, metagonimiasis by *Metagonimus* Miyata type produces non-specific mild symptoms, so that the patients themselves did not know whether they were infected with parasites.

In this study we tried to compare the pathological reactions induced by *M. yokogawai* and *Metagonimus* Miyata type using PCNA analysis.

**MATERIALS AND METHODS**

**Parasites infection and tissue preparation**

Metacercariae (Mc) of *M. yokogawai* were collected by artificial digestion of *Plecoglossus altivelis* caught at Oshipcheon, Samchok-shi, Kangwon-do. Mc of *Metagonimus* Miyata type were collected from *Zacco platypus* caught at Dalchon river, Chungju-shi, Chungchongbuk-do. Three hundreds Mc of each species were infected orally to ICR mice. Each experimental group used 7 mice and the mice were sacrificed according to the time schedule (Table 1). Ten cm of jejunum from the Treitz' ligament toward the lower direction was resected as the proximal jejunum. Another 10 cm segment which was 5 cm apart from the proximal jejunal segment was prepared as the middle jejunum. The distal jejunum was 10 cm segment which was 5 cm proximal to the ileocecal junction (Fig. 1).

Intestinal segments were fixed in 10% neutral formalin as soon as they were removed from mice. After dehydration with alcohol

series, the tissues were embedded in paraffin and sliced with microtome. The sectioned tissue specimens were put onto albumin-treated slide glasses.

**PCNA staining**

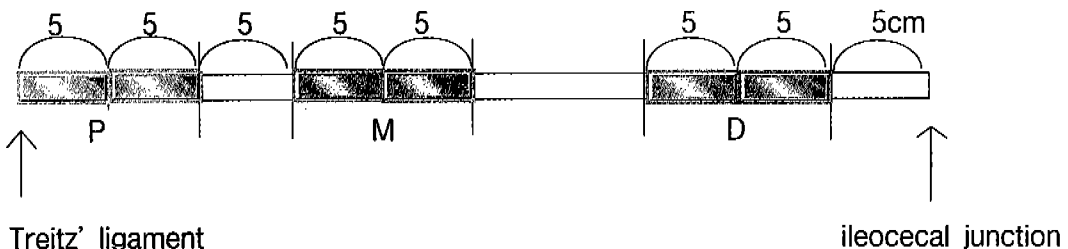
Tissue sections were deparaffinized and hydrated with alcohol series. Endogenous peroxidase activity was blocked by 3% hydrogen peroxide solution for 10 min. After washing with PBS, the slides were blocked with normal goat serum for 15 min to decrease background non-specific binding. Primary antibody (DAKO-PCNA, PC-10, Santa Babara, CA, USA) was reacted for 20 min and secondary antibody was linked for 10 min. Peroxidase-conjugated streptavidin was reacted for 10 min. Color reaction was done by chromogen, 3,3'-diaminobenzidine tetrahydrochloride (DAB, Sigma). For a counter staining, ethyl green solution was used for 30 min.

PCNA index was obtained as the percentage of positively stained cells among 500 cells of crypts. Repeated counting was done in five different fields per mouse.

**Table 1.** The number of mice used for this experiment

PI <sup>a)</sup> day	control	My <sup>b)</sup> (Mc <sup>d)</sup>	Mm <sup>c)</sup> (Mc)
3	7	7 (300)	7 (300)
6	7	7 (300)	7 (300)
10	7	7 (300)	7 (300)
16	7	7 (300)	7 (300)
23	7	7 (300)	7 (300)

a) post infection; b) *M. yokogawai* infected group; c) *Metagonimus* Miyata type infected group; d) number of infected metacercariae.



**Fig. 1.** Preparation of the small intestine of infected mice. P, proximal small intestine; M, middle small intestine; D, distal small intestine.

**Statistical analysis**

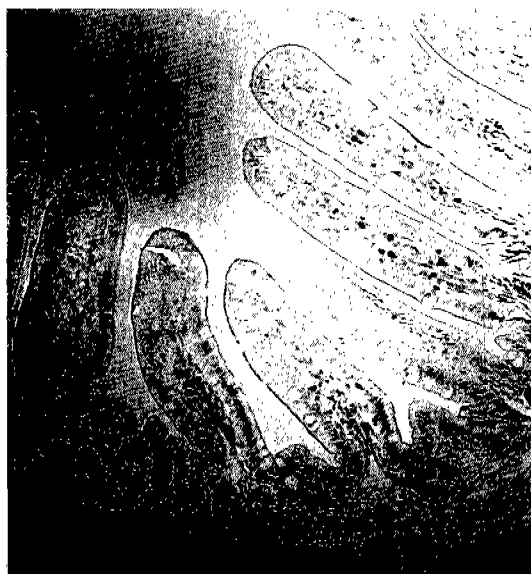For statistical analysis, student's t-test in SPSS program was used. Uninfected control group was compared with *M. yokogawai* infected group and *Metagonimus Miyata* type infected group, respectively.

**RESULTS**

The positively stained cells at PCNA-immunostaining showed brown color. Most nuclei of the crypt cells were stained strongly, but epithelial cells lining villi were very weakly reacted or not stained (Fig. 2). As the epithelial cells are located further from the crypt, the stainability decreased. So, the crypt was the main portion of cell regeneration of the intestine.

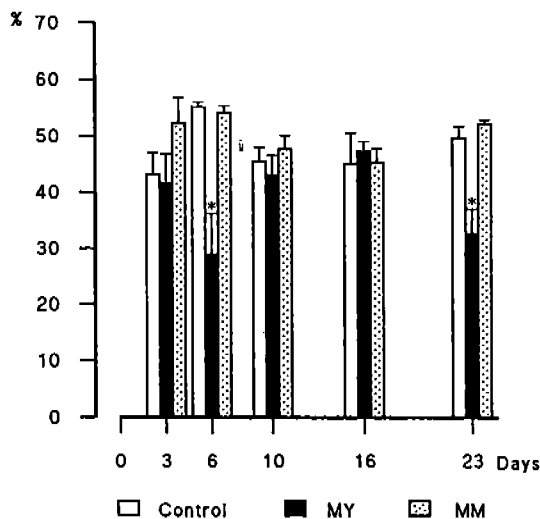
When mice were infected with *M. yokogawai*, they showed similar staining patterns in three different portions of the small intestine. The PCNA indices on the 6th and 23rd day after infection were lower in *M. yokogawai* infected group than the other two groups (control and Miyata type infected groups) ( $p < 0.05$ ) (Fig. 3-5). On the other hand, the control and *Metagonimus Miyata* type infected groups did not make any differences in PCNA indices.

The villus/crypt (V/C) ratio was also meas-

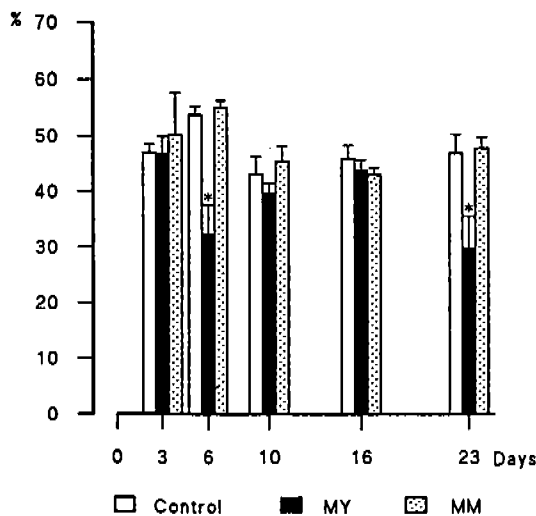


**Fig. 2.** Small intestine of mice stained at PCNA.

ured from 15 villi of each experimental group (Table 2). *M. yokogawai* infected mice showed more intestinal portions which have decreased V/C ratio than *Metagonimus Miyata* type infected ones. The length of villi decreased and the length of crypts increased in *M. yokogawai*



**Fig. 3.** Comparison of PCNA indices among experimental groups in the proximal jejunum of mice. MY, *M. yokogawai* infected group; MM, *Metagonimus Miyata* type infected group. \* $p < 0.05$ , student's t-test.



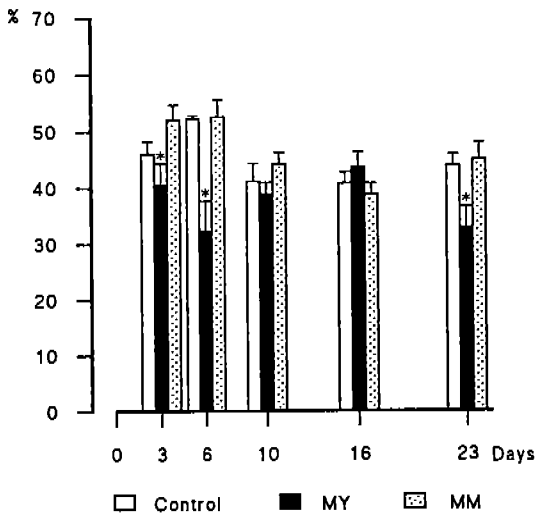
**Fig. 4.** Comparison of PCNA indices among experimental groups in the middle intestine of mice. MY, *M. yokogawai* infected group; MM, *Metagonimus Miyata* type infected group. \* $p < 0.05$ , student's t-test.

infected mice than in control group mice.

**DISCUSSION**

Morphological differential points between *M. yokogawai* and *Metagonimus* Miyata type have been described already (Chai *et al.*, 1993). Genetic differences between the two species were also evaluated recently (Yu *et al.*, 1997a & b). However, differences in the intestinal pathology which were induced by the two kinds of *Metagonimus* species have not been tried yet.

Usually in the endemic area of *Metagonimus*



**Fig. 5.** Comparison of PCNA indices among experimental groups in the distal small intestine of mice. MY, *M. yokogawai* infected group; MM, *Metagonimus* Miyata type infected group. \*p < 0.05, student's t-test.

Miyata type, the infected person, visitor or resident does not complain any specific physical discomfort. However, when a foreigner visits the endemic area of *M. yokogawai*, and eat sweet fish there, he often suffers from diarrhea (Chai *et al.*, 1989).

In this study, *M. yokogawai* infected group showed lower PCNA index in the small intestine. There were two troughs of PCNA indices after *M. yokogawai* infection. The worms are still immature and active on the 6th day after infection, so the stimuli by the worms may make harmful effects on the crypt cells. But as to the second trough on the 23rd day after infection, it is very difficult to find the reason. Proliferating cell nuclear antigen (PCNA) is considered as an indicator of proliferating cells of late G1 and S stage of the cell cycle, and many studies were performed to analyze the PCNA index to evaluate the prognosis of cancer (Van Dierendonck *et al.*, 1991). Because decreased PCNA index means reduction in the population of proliferative cells, it is likely that *M. yokogawai* made inhibitory effects on the cell proliferation in intestinal crypts at that time.

It is well studied that when intestinal trematodes infect the host, they usually produce villous atrophy and crypt hyperplasia of the host intestine, so V/C ratio of the infected host intestine decreases (Chai *et al.*, 1994; Yu *et al.*, 1995). In this study, the experimental groups which had decreased PCNA indices usually showed decreased V/C ratios. So, it is suggested that *M. yokogawai* induce villous atrophy through reduction of the proliferating cells in the crypt.

**Table 2.** Comparative values<sup>a)</sup> of V/C ratio among experimental groups

PI (days)	Control			My <sup>b)</sup>			Mm <sup>c)</sup>		
	P <sup>d)</sup>	M <sup>e)</sup>	D <sup>f)</sup>	P	M	D	P	M	D
3	6.59	4.72	3.27	4.83	4.17 <sup>g)</sup>	2.49 <sup>h)</sup>	6.28	4.57	2.59 <sup>g)</sup>
6	7.36	4.86	3.12	5.93 <sup>h)</sup>	3.74 <sup>h)</sup>	2.80	6.16 <sup>g)</sup>	4.43	3.21
10	6.60	4.03	3.40	7.43	3.53	3.08	6.11	4.09	3.31
16	8.06	4.76	3.54	6.86	3.86 <sup>g)</sup>	3.08	7.34	4.26	2.59
23	7.48	4.89	3.14	6.55 <sup>h)</sup>	4.01 <sup>h)</sup>	2.77	7.15	4.28	2.75

<sup>a)</sup>Mean values counted from 15 villi in each group; <sup>b)</sup>My, *M. yokogawai* infected group; <sup>c)</sup>Mm, *Metagonimus* Miyata type infected group; <sup>d)</sup>P, proximal small intestine; <sup>e)</sup>M, middle small intestine; <sup>f)</sup>D, distal small intestine; <sup>g)</sup>p<0.01, student's t-test; <sup>h)</sup>both PCNA index (p<0.05) and V/C ratio (p<0.01) decreased.

The three different locations of the small intestine showed the same reaction patterns. It seems likely that *M. yokogawai* makes a diffuse damage on the intestinal mucosa rather than a local influence.

In case of *Metagonimus* Miyata type infection, the mice did not show lowered PCNA indices compared with normal control mice. The number of experimental groups which developed lower V/C ratio than control groups was also smaller than in *M. yokogawai* infected groups. It should be ruled out whether ICR mice are susceptible to *M. yokogawai* infection but less susceptible to Miyata type infection. If ICR mice are less susceptible to Miyata type, the higher PCNA indices could be due to low number of flukes in the intestine. It could be also speculated, however, that *Metagonimus* Miyata type induces milder pathologic reactions on the small intestine of mice than *M. yokogawai*.

#### REFERENCES

- Chai JY, Huh S, Yu JR, *et al.* (1993) An epidemiological study of metagonimiasis along the upper reaches of the Namhan River. *Korean J Parasitol* **31**: 99-108.
- Chai JY, Lee SH (1990) Intestinal trematodes of humans in Korea: *Metagonimus*, heterophyids and echinostomes. *Korean J Parasitol* **28**(suppl): 102-122.
- Chai JY, Yu JR, Lee SH, Jung HC, Song IS, Cho SY (1989) An egg-negative patient of acute metagonimiasis diagnosed serologically by ELISA. *Seoul J Med* **30**: 139-142.
- Chai JY, Yun TY, Kim J, Huh S, Choi MH, Lee SH (1994) Chronological observation of intestinal histopathology and intraepithelial lymphocytes in the intestine of rats infected with *Metagonimus yokogawai*. *Korean J Parasitol* **32**: 215-221.
- Saito S (1984) Species differentiation of genus *Metagonimus*. *Reports on Meetings for Parasite Taxonomy and Morphology, Japan* (2): 1-4.
- Van Dierendonck JH, Wijsman JH, Keijzer R, Van de Velde CJH, Cornelisse CJ (1991) Cell-cycle-related staining patterns of anti-proliferating cell nuclear antigen monoclonal antibodies. *Am J Pathol* **138**: 1165-1172.
- Yu JR, Chung JS, Chai JY (1997a) Different RAPD patterns between *Metagonimus yokogawai* and *Metagonimus* Miyata type. *Korean J Parasitol* **35**: 295-298.
- Yu JR, Chung JS, Huh S, Chai JY, Lee SH (1997b) PCR-RFLP patterns of three kinds of *Metagonimus* in Korea. *Korean J Parasitol* **35**: 271-276.
- Yu JR, Hong ST, Chai JY, Lee SH (1995) The effect of reinfection with *Neodiplostomum seoulensis* on the histopathology and activities of brush border membrane bound enzymes in the rat small intestine. *Korean J Parasitol* **33**: 37-43.
- Yu JR, Kwon SO, Lee SH (1994) Clonorchiasis and metagonimiasis in the inhabitants along Talchongang (River), Chungwon-gun. *Korean J Parasitol* **32**: 267-269.

=초록=

## 요코가와흡충 및 미야타흡충 감염 마우스 소장 PCNA 발현 양상

유재란<sup>1)</sup>, 명나혜<sup>2)</sup>, 채종일<sup>3)</sup>

건국대학교 의과대학 기생충학교실<sup>1)</sup>, 단국대학교 의과대학 병리학교실<sup>2)</sup>,  
서울대학교 의과대학 기생충학교실 및 풍토병연구소<sup>3)</sup>

*Metagonimus*속 흡충의 형태학적인 차이점에 대하여는 잘 알려져 있으나 이들에 의해 유발되는 소장병변에 대한 차이는 알려지지 않았다. 본 연구는 소장선와의 상피세포가 두 *Metagonimus*속 흡충 감염시 반응하는 정도를 S 시기에 분열하는 세포의 핵 내 polymerase delta accessory protein을 염색하여 비교 관찰한 것이다. 요코가와흡충 (*M. yokogawai*)의 피낭유충은 삼척산 은어에서 분리하였고, 미야타흡충 (*Metagonimus Miyata type*)은 충주산 피라미에서 분리하여 사용하였다. 마우스 한 마리당 300개의 피낭유충을 감염시키고 감염 후 3일, 6일, 10일, 16일 및 23일째에 희생시켜 관찰하였다. 상부 소장에서는 요코가와흡충 감염군의 6일, 23일째에서 염색된 선와 상피세포수의 유의한 ( $P<0.05$ ) 감소를 보였다. 중부 소장에서도 상부 소장에서와 같은 양상을 보였다. 하부소장에서는 요코가와흡충 감염군에서 3일, 6일 및 23일째에 유의한 ( $P<0.05$ ) 감소를 보였다. 미야타흡충 감염군에서는 세 부위의 소장에서 모두 감염을 시키지 않은 대조군과 차이를 보이지 않았다. 위의 결과로 요코가와흡충 감염이 미야타흡충 감염시 보다 마우스 소장 선와 세포 증식을 억제하고 이의 결과로 용모의 위축을 초래함을 알 수 있었다.

[기생충학잡지 35(4): 239-244, 1997년 12월]