

Identification of larval *Gnathostoma* obtained from imported Chinese loaches

Woon-Mok SOHN^{1)*} and Soon-Hyung LEE²⁾

Department of Parasitology¹⁾, College of Medicine, Gyeongsang National University, Chinju 660-280,
Department of Parasitology and Institute of Endemic Diseases²⁾, Seoul National University
College of Medicine, Seoul 110-799, Korea

Abstract: We observed the morphological characteristics and identified the species of gnathostome larvae obtained from the imported Chinese loaches. The early third-stage larvae (EL₃) were collected from viscera of the loaches and a part of them were infected to mice. The advanced third-stage larvae (AdL₃) were recovered from the mice at 4 weeks post-infection. Both larval worms were fixed with 10% formalin, cleared in alcohol-glycerin solution, mounted with glycerin-jelly, and observed. A total of 369 EL₃ were collected from viscera of 9,493 Chinese loaches. The whole body of EL₃ was covered with about 190 transverse rows of minute cuticular spines and 0.624 × 0.101 mm in average size. A pair of lips were protruded at the anterior end, and the muscular esophagus and brownish intestine were followed. The characteristic head bulb was provided with 4 rows of hooklets. The average number of hooklets in the respective row was 36.7, 39.5, 41.6 and 44.3 posteriorly. AdL₃ was 2.660 × 0.346 mm in average size, and retained the esophagus (about 0.755 mm length) and cervical sac (about 0.355 mm length). The average number of hooklets in the respective row on the head bulb was 39.0, 41.9, 43.9 and 45.6, posteriorly. On the basis of the morphological characteristics, they were identified as the third-stage larvae of *Gnathostoma hispidum*.

Key words: *Gnathostoma hispidum*, early third-stage larva, advanced third-stage larva, Chinese loach, mouse

INTRODUCTION

Genus *Gnathostoma* is a clinically important nematode which inhabits in the tissue. In this genus, about 20 species have been reported in the literature. However, only seven species, *G. spinigerum*, *G. hispidum*, *G. turgidum*, *G. doloresi*, *G. nipponicum*, *G. americanum* and *G. procyonis*, were proved as the valid ones by Miyazaki (1960). Later, Miyazaki (1991) added 3 more species, *G. miyazakii*, *G. malaysiae* and

G. vietnamicum as new species, and Daengsvang (1980) insisted that *G. didelphis* and *G. brasiliense* are also valid ones.

Numerous human cases of gnathostomiasis have been reported in various countries of Southeast Asia, Japan, China, India, the Philippines, Israel and Mexico (Beaver *et al.*, 1984) since the first case was described in Thailand (Levinsen, 1889). As the causative species of gnathostomiasis, *G. spinigerum*, *G. hispidum*, *G. nipponicum* and *G. doloresi* have been reported. However, almost all cases were caused by *G. spinigerum* and only a few cases were by the other species (Miyazaki, 1960; Ando *et al.*, 1988; Nawa *et al.*, 1989). In case of *G. hispidum*, it has been known that a lot of

• Received Aug. 16 1996, accepted after revision Aug. 26 1996.

*Corresponding author

Japanese people were infected by eating raw flesh of loaches imported from China (Morita *et al.*, 1984; Demitsu and Aizawa, 1985; Araki, 1986).

In Korea, there have been no reports on the recovery of larval gnathostomes except that by Kim (1973). He found two larval *Gnathostoma* from the abdominal muscle of a snake head, *Channa argus*, and identified as the third-stage larvae of *G. spinigerum*. After that time some workers surveyed cyclopoid copepods, tadpoles and loaches for the recovery of gnathostome larvae, however no worms were detected, and indigenous infection in human or definitive hosts have not been reported yet (Kim, 1973; Kim, 1983; Koga *et al.*, 1985).

Recently we found the gnathostome larvae in the muscle of loaches imported from China and identified as the third-stage larvae of *G. nipponicum* (Sohn *et al.*, 1993), and we also found gnathostome larvae in the viscera of Chinese loaches. And so in this study, the morphological characteristics of larval *Gnathostoma* obtained from the viscera of Chinese loaches and from experimentally infected mice were observed for the species identification.

MATERIALS AND METHODS

A total of 9,493 loaches, *Misgurunus anguillicaudatus*, imported from China was purchased from a wholesale house of freshwater fish located in Puk-gu, Pusan, Korea. The loaches were transferred in our laboratory, and their muscle and viscera were isolated and artificially digested with pepsin-HCl solution in a 36°C incubator. Digested

materials were washed with 0.85% saline and were examined under a stereomicroscope to collect gnathostome larvae. A part of collected worms (early third-stage larva: EL₃) were fixed with 10% formalin under the cover glass pressure, cleared in alcohol-glycerin solution and mounted in glycerin-jelly. To obtain the advanced third-stage larvae (AdL₃), 10 EL₃ were given orally to 5 mice respectively, and they were recovered from the various organs of mice at 4 weeks after infection. The recovered AdL₃ were mounted in glycerin-jelly after processing as the same manners in EL₃. Both larval worms were observed and measured under a light microscope.

RESULTS

A total of 369 larval gnathostomes (early third-stage larva: EL₃) were collected from 9,493 Chinese loaches. All larvae were found in the viscera of loaches and their monthly detection status in loaches was provided in the Table 1.

The whole body of EL₃ was covered with about 190 transverse rows of minute cuticular spines and 0.624 × 0.101 mm in average size. A pair of lips were protruded at the anterior end, and the muscular esophagus (about 0.229 mm long) and brownish intestine were followed, and the anus opened at the ventral side of posterior end. Two pairs of cervical sacs (about 0.133 mm long) were clearly observed in region of the esophagus (Figs. 1 & 2). The characteristic head bulb (0.034 × 0.071 mm in average size) was provided with 4 rows of hooklets (Fig. 3). The average number of hooklets in the respective row was 36.7, 39.5,

Table 1. Infection status of imported Chinese loaches with larval gnathostome

Month (Year) examined	No. loaches examined	No. larvae detected	Ratio of loach: larva
5 (1993)	424	0	—
6	188	2	94.0:1
7	134	3	44.7:1
12	311	1	311.0:1
1 (1994)	2,272	86	26.4:1
2	1,869	142	13.2:1
3	2,888	118	24.5:1
4	1,625	17	95.6:1
Total	9,493	369	25.7:1

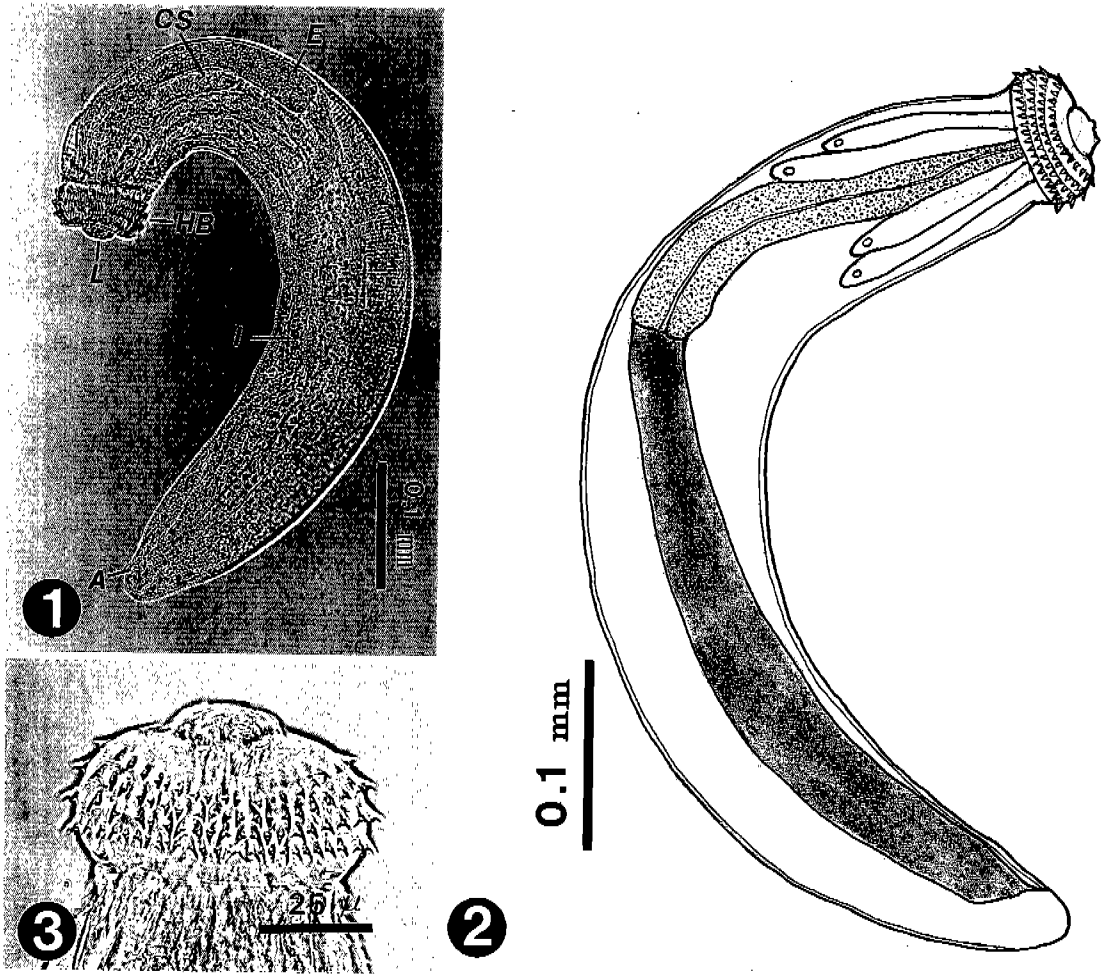


Fig. 1. The early third-stage larva (EL₃) of *G. hispidum* collected in the viscera of a loach imported from China. A: anus; CS: cervical sac; E: esophagus; HB: head bulb; I: intestine; L: lip. **Fig. 2.** The schematic drawing of EL₃ of which transverse striations of minute cuticular spines were omitted. **Fig. 3.** The head bulb of an EL₃ which retained 4 rows of hooklets with sharp-pointed end.

41.6 and 44.3, posteriorly. Morphological features and measurements were compatible with those of *G. hispidum* EL₃ reported by previous authors (Table 2).

A total of 37 AdL₃ were recovered from 5 mice experimentally infected with 10 EL₃ respectively, and their average recovery rate was 74.0%. Almost all worms were encysted in the muscle of mice, much more grown than EL₃ and covered with fine cuticular spines on the whole body (Figs. 4, 5 & 6). They were 2.660 × 0.346 mm in average size, and its esophagus was 0.755 mm long and the cervical sac 0.355 mm long. The characteristic head bulb (0.097 × 0.193 mm in average size)

was mostly provided with 4 rows of hooklets (Fig. 7) and rarely with 5 rows with 3-7 hooklets. The average number of hooklets in the respective row on the head bulb was 39.0, 41.9, 43.9 and 45.6, posteriorly. Morphological features and measurements were compatible with those of *G. hispidum* AdL₃ reported by previous authors (Table 3).

DISCUSSION

The genus *Gnathostoma* is a well-known causative agent of the creeping eruption in human. Human gnathostomiasis has been mainly caused by *G. spinigerum*, and

Table 2. Measurements^{a)} of the larval gnathostome from the Chinese loaches and comparison with those of previous authors

Organs	Present study (1996) ^{b)}	Takakura <i>et al.</i> (1985) ^{c)}	Akahane <i>et al.</i> (1982) ^{d)}
Body length	0.536–0.806 (0.624)	0.586 ± 0.100	(0.613)
width	0.082–0.122 (0.101)	0.074 ± 0.013	(0.093)
Esophagus	0.198–0.272 (0.229)	0.243 ± 0.035	(0.243)
Cervical sac	0.107–0.160 (0.133)	—	(0.163)
Head bulb length	0.031–0.041 (0.034)	0.030 ± 0.005	(0.044)
width	0.066–0.086 (0.071)	0.061 ± 0.007	(0.068)
No. of hooklets on head bulb			
1st row	35–39 (36.7)	33–45 (38.0)	(39.0)
2nd row	38–41 (39.5)	36–45 (39.8)	(40.0)
3rd row	39–44 (41.6)	35–49 (41.6)	(41.8)
4th row	42–45 (44.3)	39–50 (44.7)	(45.4)

^{a)}Unit is mm (average); ^{b)}10 larvae, ^{c)}64 and ^{d)}21 EL₃ of *G. hispidum* were measured.

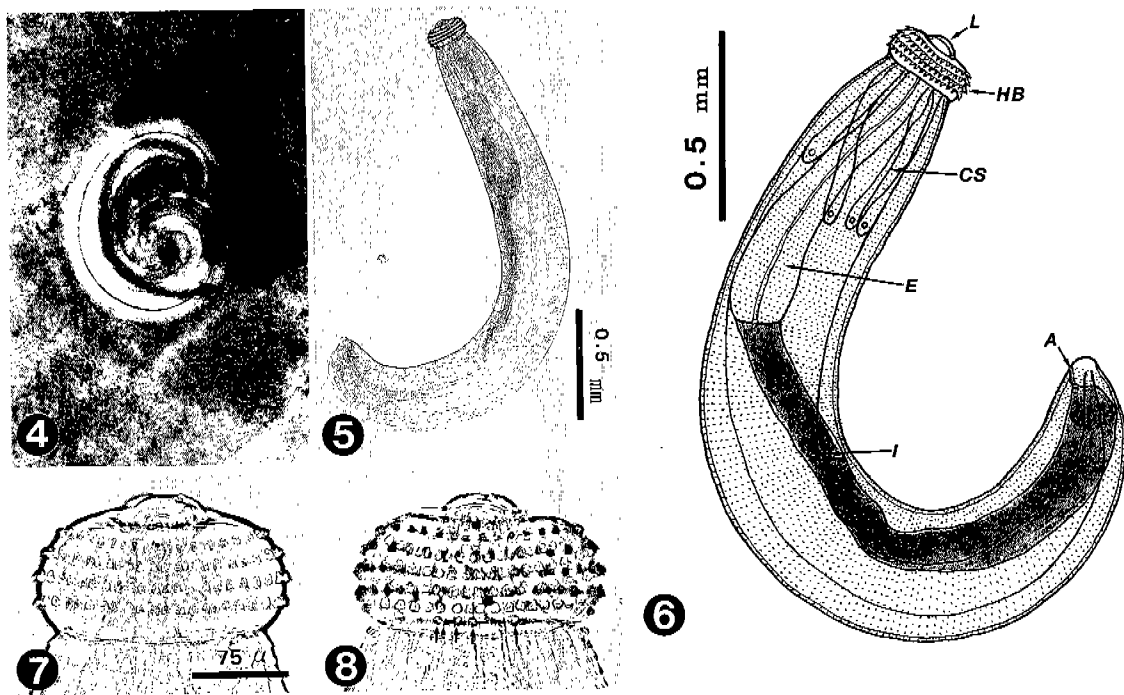


Fig. 4. The advanced third-stage larva (AdL₃) of *G. hispidum* encysted in the liver of an experimental mouse. **Fig. 5.** The AdL₃ of *G. hispidum* recovered from the muscle of a mouse experimentally infected with EL₃. **Fig. 6.** The schematic drawing of AdL₃. **Fig. 7.** The head bulb of an AdL₃ bearing 4 transverse rows of hooklets. **Fig. 8.** The head bulb of an AdL₃. Note the 5th row of hooklets (arrow marks).

sometimes by *G. hispidum*, *G. doloresi* and *G. nipponicum* (Beaver *et al.*, 1984; Morita *et al.*, 1984; Nawa *et al.*, 1988; Ando *et al.*, 1988). However in case of the human infections by *G. hispidum*, there has been a considerable

increase in Japan since 1980. The Japanese patients were presumably caused by ingesting raw flesh of loaches imported from China (Demitsu and Aizawa, 1985). All of the larval gnathostomes collected from the imported

Table 3. Measurements^{a)} of the advanced third-stage larvae (AdL₃) from the experimentally infected mice and comparison with those of previous authors

Organs	Present study (1996) ^{b)}	Takakura <i>et al.</i> (1985) ^{c)}	Akahane <i>et al.</i> (1982) ^{d)}
Body length	2.244~3.080 (2.660)	2.89 ± 0.25	(3.1)
width	0.306~0.377 (0.346)	0.23 ± 0.03	(0.3)
Esophagus	0.714~0.816 (0.755)	0.89 ± 0.12	(0.9)
Cervical sac	0.306~0.459 (0.355)	—	(0.5)
Head bulb length	0.087~0.122 (0.097)	0.069 ± 0.008	(0.121)
width	0.184~0.204 (0.193)	0.155 ± 0.012	(0.198)
No. of hooklets on head bulb			
1st row	38~40 (39.0)	31~42 (38.5)	(38.3)
2nd row	40~44 (41.9)	34~44 (38.6)	(40.5)
3rd row	42~46 (43.9)	37~45 (41.6)	(41.8)
4th row	44~48 (45.6)	41~49 (44.3)	(46.0)
5th row	0~7 (1.5)	0~3 (0.3)	—

^{a)}Unit is mm (average); ^{b)}10 larvae, ^{c)}18 and ^{d)}9 AdL₃ of *G. hispidum* were measured.

Chinese loaches (Akahane *et al.*, 1982; Akahane and Mako, 1984) and the worms recovered from human cases with past history of eating raw Chinese loaches (Morita *et al.*, 1984; Araki, 1986) were identified as larvae of *G. hispidum*.

In Korea, human gnathostomiasis was recorded only one case (Lee *et al.*, 1988). The case was imported from Thailand and the detected worm was identified as *G. spinigerum*. Recently we found the gnathostome larvae in the muscle of loaches imported from China and identified as the third-stage larva of *G. nipponicum* (Sohn *et al.*, 1993). In the present study, we also found larval *Gnathostoma* from imported Chinese loaches, which were identified as the third-stage larvae of *G. hispidum* when their morphological characteristics and measurements were compared with previous records.

G. hispidum is a common parasite of domestic or wild pigs in Asia and Europe. It is widely distributed from Southeastern Asia to Far East, however is not in Korea. In China, a few reports concerning the prevalence of adult worms in domestic pig were available (Chen, 1936; Wang *et al.*, 1976; Huang *et al.*, 1986), but not on larval worms in loaches. By the reports in Japan, Akahane and Mako (1984) detected 1,076 EL₃ and a few AdL₃ of *G. hispidum* from the Chinese loaches of 110 Kg from April, 1981 to December, 1983, and Koga

et al. (1985) found 576 larvae from 4,461 Chinese loaches. In this study, we found 369 EL₃ from the viscera of 9,493 Chinese loaches, and the prevalence in loaches investigated in February, 1994 was most high. However, the monthly prevalence of larvae in loaches are not meaningful without knowing the locality where caught in China. Akahane and Mako (1984) reported that the Chinese loaches from Nanking more prevalent than those from Peking and Tientsin.

There is a considerable confusion in the literature with regard to the stage of larval gnathostomes found in the first or second intermediate host. Daengsvang (1968) called them as the early third-stage and the advanced third-stage larva. On the other hand, Koga *et al.* (1985) reported that AdL₃ of which body length is about 3.0 mm was 2% among the 576 larval *G. hispidum* collected from 4,461 Chinese loaches. However in this study, no AdL₃ were found from 9,493 Chinese loaches, but AdL₃ recovered from the experimentally infected mice were compatible with those from Chinese loaches described by Koga *et al.* (1985) and also with those from experimental animals recorded by Akahane *et al.* (1982) or Takakura *et al.* (1985).

Miyazaki (1960) mentioned that the number and the shape of hooklets on the head bulb are very useful for species identification of the genus *Gnathostoma*. The hooklet features of

Table 4. Comparison of the number of hooklets on head bulbs in several species of larval *Gnathostoma*

Species	1st row	2nd row	3rd row	4th row
<i>G. nipponicum</i> ^{a)}	29~36 (32)	30~37 (35)	31~41 (37)	—
<i>G. dolores</i> ^{a)}	34~42 (38)	35~43 (40)	34~39 (36)	33~41 (37)
<i>G. spinigerum</i> ^{a)}	40~47 (43)	37~49 (45)	42~52 (47)	48~58 (52)
<i>G. hispidum</i> ^{b)}	32~38 (36)	37~41 (40)	39~44 (42)	42~48 (45)
Present study	35~39 (37)	38~41 (40)	39~44 (42)	42~45 (44)

^{a)}From Miyazaki (1952); ^{b)}from Koga *et al.* (1985)

the larval gnathostomes in this study were compatible with those of *G. hispidum* described by previous authors, however they were definitely different from those of other 3 species distributed in Far East (Table 4).

REFERENCES

Akahane H, Iwata K, Miyazaki I (1982) Studies on *Gnathostoma hispidum* Fedtschenko, 1872 parasitic in loaches imported from China. *Jpn J Parasitol* **31**: 507-516 (in Japanese).

Akahane H, Mako T (1984) Infection patterns of *Gnathostoma hispidum* in loaches imported from mainland China. *Jpn J Parasitol* **33**: 509-513 (in Japanese).

Ando K, Tanaka H, Taniguchi Y, Shimizu M, Kondo K (1988) Two human cases of gnathostomiasis and discovery of a second intermediate host of *Gnathostoma nipponicum* in Japan. *J Parasitol* **74**(4): 623-627.

Araki T (1986) Gnathostomiasis-parasitic diseases caused by eating raw loaches. *Kansen Ensyu Meneki (Infection, Inflammation and Immunology)* **16**: 110-111 (in Japanese).

Beaver PC, Jung RC, Cupp EW (1984) Clinical Parasitology, 9th ed., 340-342 pp. Lea & Febiger, Philadelphia.

Chen HT (1936) Parasites in slaughter houses in Canton. Part 1. Helminths of Kwangtung hogs. *Lingnan Sci J* **15**: 31-44.

Daengsvang S (1968) Further observations on the experimental transmission of *Gnathostoma spinigerum*. *Ann Trop Med Parasitol* **62**: 88-94.

Daengsvang S (1980) A monograph on the genus *Gnathostoma* and gnathostomiasis in Thailand. Southeast Asian Medical Information Center, Tokyo.

Demitsu T, Aizawa H (1985) Gnathostomiasis cutis. *Rinshohifuka* **39**: 255-260 (in

Japanese).

Huang WC, Xia BF, Koga M, Ishii Y (1986). A survey on *Gnathostoma hispidum* Fedtschenko, 1872 in Jiangxi, People's Republic of China. *Jpn J Parasitol* **35**(3): 223-227.

Kim CH (1983) The infection status of sparganum and *Gnathostoma* in frogs of southern part of Korea. *Korean J Parasitol* **21**(1): 83-86 (in Korean).

Kim YK (1973) A study on *Gnathostoma* (1) An investigation into the geographical distribution of larvae on the second and third stage in Gyengsang Nam do. *Bull Pusan Nat Univ (Natur Sci)* **15**: 111-116 (in Korean).

Koga M, Ishibashi J, Ishii Y, Hasegawa H, Choi DW, Lo TY (1985) Morphology and experimental infections of gnathostome larvae from imported loaches, *Misgurunus anguillicaudatus*. *Jpn J Parasitol* **34**: 361-370. (in Japanese).

Lee SH, Hong ST, Chai JY (1988) Description of a male *Gnathostoma spinigerum* recovered from a Thai woman with meningoencephalitis. *Korean J Parasitol* **26**(1): 33-38.

Levinsen GM (1889) Om en ny Rundorm hos Mennesket, *Cheiracanthus siamensis* n. sp. *Videnskabel Meddel fra den naturhist Foren i Kjobenhaven*, 323-326.

Miyazaki I (1960) On the genus *Gnathostoma* and human gnathostomiasis, with special reference to Japan. *Exp Parasitol* **9**: 338-370.

Miyazaki I (1991) An illustrated book of helminthic zoonoses, p368-409. International Medical Foundation of Japan, Tokyo.

Miyazaki I, Ishii Y (1952) On a gnathostome larva encysted in the muscle of salamander, *Hynobius*. *Acta Med (Fukuoka)* **22**: 467-473.

Morita H, Segawa T, Nishiyama T (1984) *Gnathostoma* cases caused by imported loaches. *J Nara Med Assoc* **35**: 607-619 (in Japanese).

Nawa Y, Imai J, Ogata K, Otsuka K (1989) The first record of a confirmed human case of

- Gnathostoma doloresi* infection. *J Parasitol* **75**: 166-169.
- Sohn WM, Kho WG, Lee SH (1993) Larval *Gnathostoma nipponicum* found in the imported Chinese loaches. *Korean J Parasitol* **31**(4): 347-352.
- Takakura Y, Ohnishi Y, Akao N, Kondo K, Yoshimura H (1985) Studies on experimental infection to the piglets with *Gnathostoma hispidum* larvae and morphology of the worms. *Jpn J Parasitol* **34**(4): 211-218 (in Japanese).
- Wang P, Sun Y, Zhao Y (1976) On the development of *Gnathostoma hispidum* in the intermediate host with special reference to its transmission route in pigs. *Acta Zool Sinica* **22**: 45-52.

=초록=

중국산 수입 미꾸리로부터 획득한 악구충 제3기 유충의 종 동정

손운목¹⁾, 이순형²⁾

경상대학교 의과대학 기생충학교실¹⁾, 서울대학교 의과대학 기생충학교실 및 풍토병연구소²⁾

중국산 수입 미꾸리로부터 획득한 악구충 유충의 형태학적 특징을 관찰하고 종 동정하고자 하였다. Early third-stage larva (EL₃)는 중국산 미꾸리의 내장에서 분리 수집하였고 advanced third-stage larva (AdL₃)는 EL₃를 마우스에 실험감염시킨 후 4주에 회수하였다. 미꾸리 및 마우스로부터 획득한 총체들을 10% formalin으로 고정하였고 alcohol-glycerin 용액을 거쳐 glycerin-jelly로 봉입한 후 관찰 및 계측하였다. 총 9,493마리의 중국산 미꾸리를 조사하였던 바, 총 369마리의 EL₃가 검출되었다. EL₃는 평균 0.624 × 0.101 mm 크기이었고 체표면에 약 190 줄의 가로주름(transverse striation)이 나 있었으며 각 주름에는 미세한 가시(cuticular spine)들이 일정한 간격으로 배열되어 있었다. 총체의 전단에는 1쌍의 구순이 돌출되어 있었고 그 뒤로 근육성의 인두(평균 0.229 mm)와 갈색의 장이 이어졌으며 후단 근처의 복측에 항문이 개구하였다. 특징적인 head bulb(평균 0.034 × 0.071 mm)에는 소구(hooklet)가 평균 36.7개, 39.5개, 41.6개 및 44.3개씩 4줄 배열되어 있었고 head bulb 바로 뒤에는 2쌍의 cervical sac(평균 0.133 mm)이 인두를 따라 길이로 배열되어 있었다. AdL₃는 평균 2.660 × 0.346 mm 크기이었고 총체 전단의 구순, 특징적인 head bulb(평균 0.097 × 0.193 mm), 근육성의 인두(평균 0.755 mm), 2쌍의 cervical sac(평균 0.355 mm), 갈색의 장 등을 가지고 있었다. 대부분의 총체 head bulb에는 소구가 평균 39.0개, 41.9개, 43.9개 및 45.6개씩 4줄 배열되어 있었으나 몇몇 총체에서는 5번째 줄에 3~7개의 소구가 배열되어 있었다. 이상의 형태학적 특징 및 계측치를 토대로 하여 중국산 수입 미꾸리와 실험감염 마우스로부터 획득한 악구충을 폐지악구충(*Gnathostoma hispidum*)의 제3기 유충으로 동정하였다.

(기생충학잡지 32(3): 161-167, 1996년 9월)