

# 국소의치 증례에서 attachment를 지대치에 설치해주는 방법

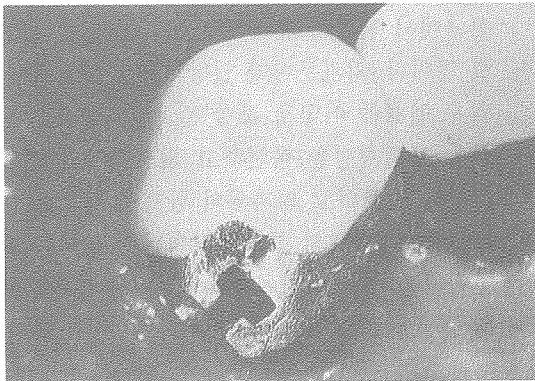
고대 구로병원 치과  
과장 신상완

문) 국소의치 증례에서 attachment를 지대치에 설치해주는 방법에 대하여 알고 싶습니다

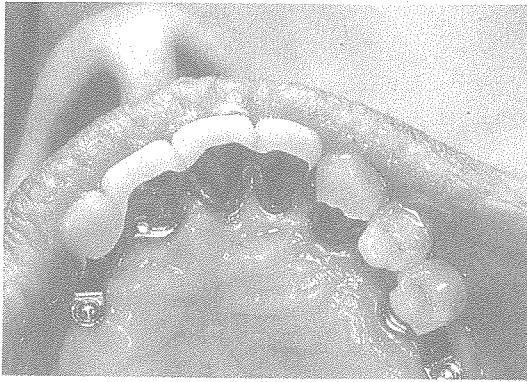
답) 스위스의 Bern 대학의 Graber 교수(1988)는 attachment를 다양한 형태로 국소의치 지대치에 설치해주는 방법을 소개하였다.

\* Attachment 의 설치방법

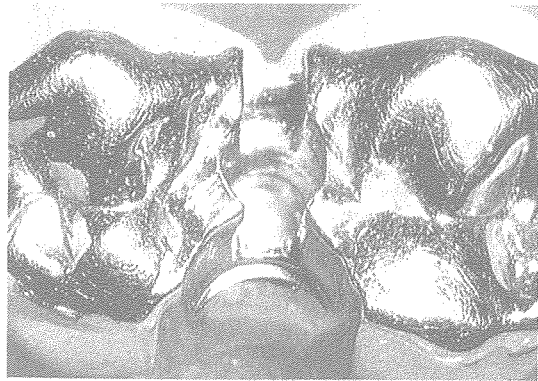
- a) Intracoronal (치관내)
- b) Extracoronal (치관외)
- c) Interproximal (지대치들 사이 인접면)
- d) Within cantilevered pontics (cantilever된 인공치내)
- e) Attached to cantilevered pontics (cantilever된 인공치관외)
- f) In pontics between bridge retainer (bridge의 인공치관내)
- g) Attached to root copings (root coping에 붙여서 extraradicular 형태)



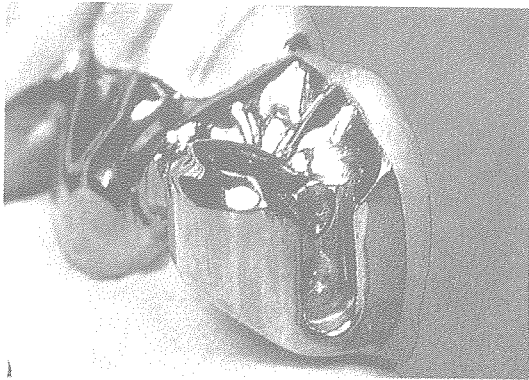
a : Intracoronal




b : Extracoronal



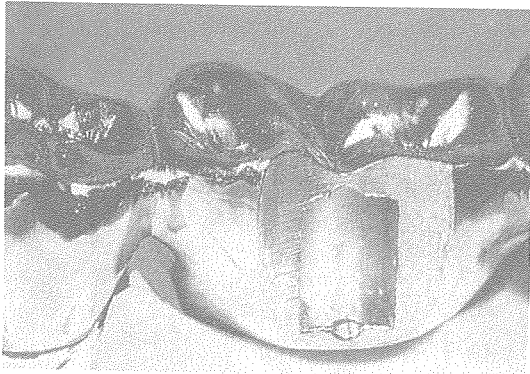
c : Interproximal



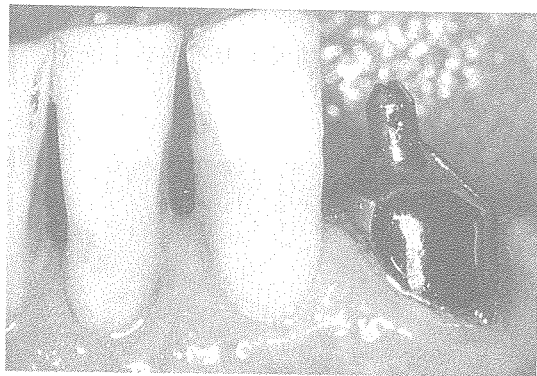
d : Within cantilevered pontics



e : Attached to cantilevered pontics



f : In pontics between bridge retainer



g : Attached to root copings