

Mansonian schistosomiasis in rectum

— Report of a case —

So Dug LIM¹⁾, Yeon-Lim SUH²⁾, Je G CHI^{1)*}, Sung-Tae HONG³⁾ and Soon-Hyung LEE³⁾

Department of Pathology¹⁾ and Parasitology³⁾, Seoul National University College of Medicine, Department of Diagnostic Pathology, Samsung Medical Center²⁾

Abstract: Schistosomiasis is a snail-transmitted trematodiasis acquired by immersion in water which contains the cercariae. In Korea, six imported cases of urinary schistosomiasis by *Schistosoma haematobium* and one case of imported cerebral schistosomiasis by *S. mansoni* were reported. Herein we report a case of *S. mansoni* infecting rectum of a 46 year-old Korean male, who had been to Saudi Arabia for two years. On colonoscopy for routine physical check up, a 0.4 cm polyp in the rectum was detected and biopsy was done. Microscopically, rectal mucosa showed several granulomas which were composed of macrophages, lymphocytes, neutrophils and eosinophils. The center of each granuloma showed an ovoid egg often containing miracidium. The eggs measured $130 \times 60 \mu\text{m}$ in average size. They had yellowish-brown transparent shell with the characteristic lateral spine. This is the 8th imported case of schistosomiasis in Korea and the second one infected by *S. mansoni*.

Key words: *Schistosoma mansoni*, rectum, Korea, imported case.

INTRODUCTION

Schistosomiasis caused by trematodes inhabiting in the blood vessels of man is a parasitosis affecting 200 to 250 million people around the world, mainly in tropical and subtropical regions of Africa, Asia, central and south America (Beaver *et al.*, 1984). Depending on the parasitic species, the ureters and the urinary bladder or the intestine and the liver are primarily involved. Other organs such as the lungs, kidneys, and central nervous system (Beaver *et al.*, 1984; Lee *et al.*, 1995) may be affected in schistosomiasis.

In Korea, seven imported cases of urinary schistosomiasis by *S. haematobium* and cerebral schistosomiasis by *S. mansoni* have

been reported (Table 1). However there is no report on intestinal schistosomiasis (Min *et al.*, 1982; Lee *et al.*, 1995).

Herein we report the 8th case of *S. mansoni* in Korea, which infected the rectum of a 46 year-old Korean male who had been to Saudi Arabia for two years as a construction worker in 1978.

CASE DESCRIPTION

A 47-year old man visited Samsung Medical Center for a routine physical check up. He had been essentially asymptomatic. Specifically no gastrointestinal symptoms were present. On colonoscopic examination, a 0.4 cm polyp was noted in the rectum, for which an endoscopic biopsy was done (Fig. 1). Microscopically four fragments of rectal mucosa showed focal ulceration, chronic inflammation and focal fibrosis. The lamina propria showed scattered granulomas without central necrosis. A total of

• Received Nov. 20 1995, accepted after revision Dec. 1 1995.

* Corresponding author

Table 1. Summary of imported schistosomiasis in Korea.

	Involved organ	Species	History of abroad travel	Diagnostic method
1	Urinary bladder	<i>S. haematobium</i>	Yemen	egg & biopsy
2	Urinary bladder	<i>S. haematobium</i>	Yemen	egg & biopsy
3	Urinary bladder	<i>S. haematobium</i>	Yemen	egg & biopsy
4	Urinary bladder	<i>S. haematobium</i>	Yemen	egg & biopsy
5	Urinary bladder	<i>S. haematobium</i>	Yemen	egg
6	Urinary bladder	<i>S. haematobium</i>	Yemen	egg & biopsy
7	Cerebellum, Spinal cord	<i>S. mansoni</i>	Yemen	egg, biopsy & serologic test
8	Rectum	<i>S. mansoni</i>	Saudi Arabia	egg & biopsy

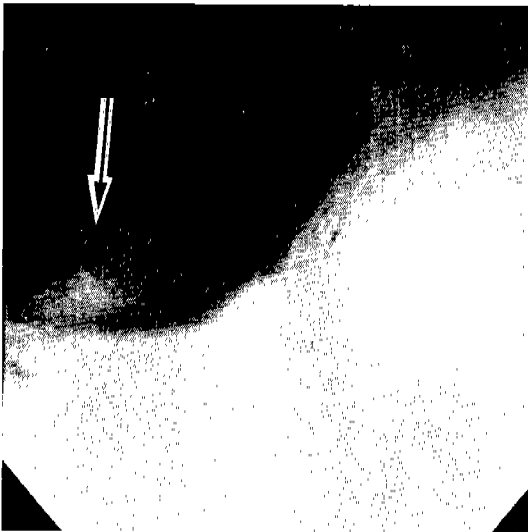


Fig. 1. Colonoscopic examination revealed a 0.5 cm polyp (arrow) in the rectum.

7 granulomas were seen in serial sections of the 4 biopsy fragments. The granulomas were largely comprised of epithelioid cells with sprinklings of lymphocytes, eosinophils and some multinucleated Langhans giant cells. The center of each granuloma showed an ovoid egg often containing miracidium (Fig. 2). Some eggs were cut across and some were degenerated. The eggs measured $130 \times 60 \mu\text{m}$ in average size. They had yellowish-brown transparent shell and no operculum. One longitudinally sectioned egg showed the definite lateral spine along the anterolateral side, and its length was $130 \mu\text{m}$ (Fig. 3). The miracidium was often seen in eggs and the miracidia showed the epidermal plates heavily invested with cilia, a pair of cephalic penetration glands and a primitive gut (Fig. 3).

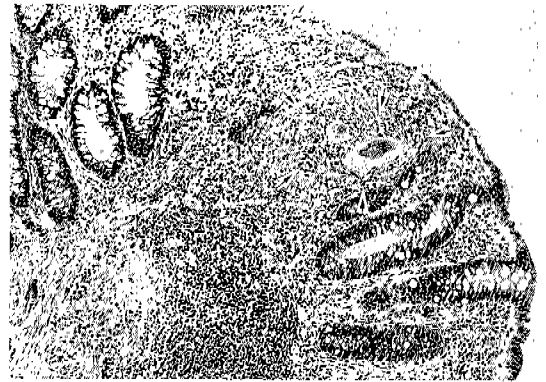

Fig. 2. Microscopically the rectal mucosa is chronically inflamed and contains a focus of egg granuloma (arrows), original magnification, $\times 100$.

No vascular abnormality could be seen. After making the diagnosis of schistosomiasis the patient was retrospectively questioned for the history of travel outside Korea. The patient gave us the information that he had been to Saudi Arabia for two years as a construction worker in 1978. At that time he swam in the river. He came back home and remained in good health ever since that time.

DISCUSSION

Schistosomiasis is virtually not existent in Korea, because there are no appropriate intermediate host. The disease is acquired by invasion of the cercaria into the skin due to direct contact with cercaria-containing the water (Song *et al.*, 1981; Lee *et al.*, 1989). Therefore all cases so far reported in Korea are imported ones from outside countries. In these cases, a contact history to fresh water in

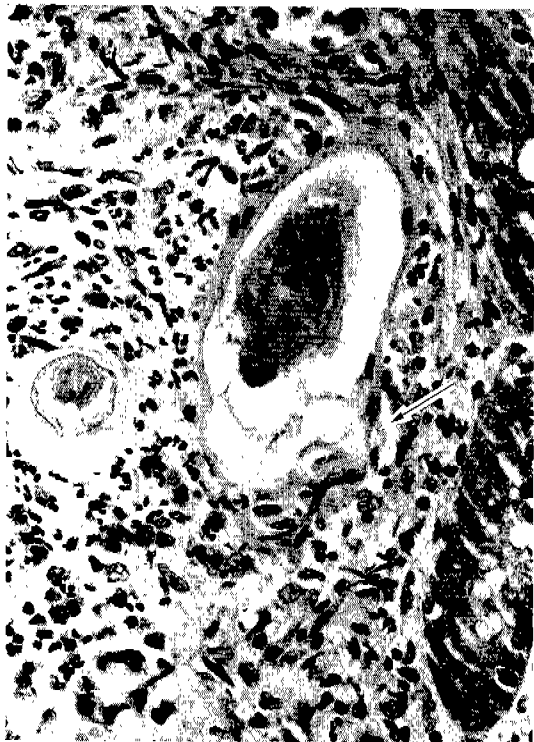

Fig. 3. Close up view of *S. mansoni* eggs, one egg shows a characteristic lateral spine of the shell (arrow) and miracidium in the center, original magnification, $\times 400$.

endemic areas gives helpful diagnostic hint for schistosomiasis. The present case is another example of imported schistosomiasis of the intestine in a Korean man.

Schistosomiasis is a blood-dwelling parasite. After several days in the skin, all migrating schistosomula penetrate directly into the veins and are transferred passively to the heart and lungs. Schistosomula on reaching the lungs transform into slender forms with cuticular spines and migrate actively within the pulmonary capillaries to reach the systemic circulation (Miller and Wilson, 1980; Beaver *et al.*, 1984). Sexually mature worms are typically found in the mesenteric venules draining the large bowel and the most posterior segment of the ileum. The granulomas are first seen when the eggs break out of the venules into the submucosal and mucosal layers of the intestine. Some of the eggs escaping into the lumen of the bowel are passed in the feces.

Among 3 main species of human

schistosomiasis, *S. mansoni* involves mainly the large intestine producing symptoms which depend upon the number of worms. Most symptoms of the chronic phase are produced by the eggs and granulomatous inflammation they elicit, rather than by the adult worms (Gutierrez, 1990). The majority of individuals infected with *S. mansoni* have no gross abnormalities in the intestine. However, the lesions are mostly in the rectum, consisting of sandy patches and inflammatory polyps (Dimmette *et al.*, 1956; Domingo and Warren, 1969; Gutierrez, 1990). Our case presented a polypoid mass. Microscopically, most lesions are alike and consist of granulomas in different stages of evolution and variable amounts of fibrosis in the mucosa and submucosa. To explain the prominent egg granulomas in schistosomiasis, the delayed cell-mediated immunity is known to be an important factor. Continuous enzymatic and antigenic secretions of these eggs may induce granulomatous responses of lymphocytes, eosinophils and macrophages (Ahn and Colley, 1984; Mahmoud, 1977).

The diagnosis is based on the typical morphology of the eggs in feces or in the tissue. All schistosome eggs should be measured carefully to exclude other parasitic eggs. Presence of the long lateral spine is the diagnostic clue for *S. mansoni*. Definite diagnosis often requires serial sections, to find the typical spine in the tissue. Fixation and dehydration processing usually distort the egg shell resulting in artifacts often resembling a spine. In our case, only one definite lateral spine could be confirmed in serial sections.

The present case has no related symptoms of intestinal schistosomiasis. Since long time has passed from his stay at Saudi Arabia, no living adults are expected. The findings described in this record may be residual lesions in chronic schistosomiasis. More egg granulomas could be expected in the remaining mucosa of his intestine, but of little clinical importance. However, praziquantel (25 mg/kg \times 3, 2 days) was prescribed.

In conclusion, our case is the first imported case of intestinal schistosomiasis and the second one of *S. mansoni* infection in Korea.

REFERENCES

Ahn MH, Colley DG (1984) Immunological responses by soluble egg antigen of *Schistosoma mansoni* in mice. *Korean J Parasitol* **22**: 203-208.

Beaver PC, Jung RC, Cupp E (1984) *Clinical Parasitology* (9th ed.). Lea & Febiger, Philadelphia.

Cotran RS, Kumar V, Robbins SL (1994) *Robbins: Pathologic basis of disease* (5th ed.). W.B. Saunders, Philadelphia.

Dimmette RM, Elwi AM, Sproat HF (1956) Relationship of schistosomiasis to polyposis and adenocarcinoma of large intestine. *Am J Clin Pathol* **26**: 266-276.

Domingo EO, Warren KS (1969) Pathology and pathophysiology of the small intestine in murine Schistosomiasis mansoni, including a review of the literature. *Gastroenterology* **56**: 231-40.

Gutierrez Y (1990) *Diagnostic pathology of parasitic infections with clinical correlations*. Lea & Febiger, Philadelphia.

Helmstadter V, Ostertag KD, Wysocki S, et al. (1994) Schistosomiasis and signet ring cell carcinoma of the ileocecal valve. *Dtsch Med Wochenschr* **119**: 301-304 (abstracts).

Lee HF, Wykoff DE, Beaver PC (1966) Two cases of human Schistosomiasis in new localities in Thailand. *Am J Trop Med Hyg* **15**: 303-306.

Lee SY, Park YY, Kwon PS, et al. (1989) Urinary schistosomiasis: a case report. *Korean J Urol* **30**: 224-227.

Lee YK, Choi TY, Jin SY, et al. (1995) Imported CNS schistosomiasis. *J Korean Med Sci* **10**: 57-61.

Long E, Harrison R, Bickle Q, et al. (1980) Factors affecting the acquisition of resistance against *Schistosoma mansoni* in the mouse. The effect of varying the route and the number of primary infections, and the correlation between the size of the primary infection and the degree of resistance that is acquired. *Parasitology* **81**: 355-371.

Mahmoud AA (1977) Schistosomiasis. *N Engl J Med* **297**: 1329-31.

Miller P, Wilson RA (1980) Migration of the schistosomula of *Schistosoma mansoni* from the lungs to the hepatic portal system. *Parasitology* **80**: 267-288.

Min DY, Soh CT, Lee MS, et al. (1982) Urinary schistosomiasis among Korean returnees from the middle east. *Yonsei Rep Trop Med* **13**: 224-7.

Pan CT (1965) Studies on the host-parasite relationship between *Schistosoma mansoni* and the snail *Australorbis glabratus*. *Am J Trop Med Hyg* **14**: 931-979.

Song JM, Lee MS, Min DY, et al. (1981) A case of urinary schistosomiasis. *J Korean Med Assoc* **24**: 1095-1098.

=초록=

직장에 발생한 만손주혈흡충증 일례 보고

임소덕¹⁾, 서연립²⁾, 지제근¹⁾, 홍성태³⁾, 이순형³⁾

서울대학교 의과대학 병리학교실¹⁾, 기생충학교실³⁾, 삼성서울병원 진단병리과²⁾

주혈흡충증은 물을 매개로 하여 패류에서 유출된 유미유충에 감염되어 생기는 수인성 기생충 질환으로, 만손주혈흡충증은 남미, 아프리카와 중동지역에서 흔히 유행한다. 한국에서는 수입증례로 방광에 발생한 6례의 주혈흡충증과 뇌에 발생한 한례의 만손주혈흡충증이 보고된 바 있다. 저자들은 2년 동안 사우디 아라비아에서 건축업을 하다가 귀국한 46세 남자의 직장에 발생한 만손주혈흡충증을 경험하여 이를 보고한다. 환자는 정기 신체검사에서 직장경 검사상 직장에 0.4 cm 크기의 폴립이 발견되었다. 광학현미경상 점막 및 점막하에 조직구, 림프구, 호중구와 호산구로 구성된 수개의 육아종이 관찰되었고 각 육아종에는 미라시디움을 갖고 있는 총란이 있었다. 총란은 130 × 60 μm 크기였고 반투명한 껍데기와 매우 특징적인 측방극(lateral spine)을 보여 만손주혈흡충에 해당하였다. 본 증례는 우리 나라에서 8번째 주혈흡충증의 수입 증례이며 만손주혈흡충증으로는 두 번째이고, 장의 병변이 확인된 주혈흡충증례로는 첫 번째이다.