

The effect of reinfection with *Neodiplostomum seoulensis* on the histopathology and activities of brush border membrane bound enzymes in the rat small intestine

Jae-Ran YU^{1)*}, Sung-Tae HONG²⁾, Jong-Yil CHAI²⁾ and Soon-Hyung LEE²⁾

Department of Parasitology¹⁾, College of Medicine, Konkuk University, Chungju 380-701, Department of Parasitology and Institute of Endemic Diseases²⁾, Seoul National University College of Medicine, Seoul 110-799, Korea

Abstract: *Neodiplostomum seoulensis*, one of the human intestinal trematodes, was reinfected to albino rats, and worm recovery rates, histopathology and activity changes of the intestinal brush border membrane bound enzymes were observed. The experimental groups were three; uninfected, primary infection and reinfection. The worm recovery rate in the reinfection group was much lower than in the primary infection group 14 days after infection. The duodenal histopathology showed villous atrophy during the first and second week in the primary infection group. In the reinfection group, however, villous changes occurred as early as 3 days after the infection, and the lesion was found healed 7 days after infection. The activities of alkaline phosphatase and sucrase in the duodenum of primary infection rats decreased nearly half of the controls 2 weeks after infection, whereas the activities were unchanged in the reinfection group. However, no changes in the activities were observed in the proximal jejunum between the experimental groups. These findings suggested that a secondary infection of *N. seoulensis* in rats should make less damage on the intestinal mucosa than a primary infection.

Key words: *Neodiplostomum seoulensis*, albino rats, reinfection, worm recovery, histopathology, brush border membrane bound enzymes

INTRODUCTION

In a histopathological study on the small intestine of mice and rats infected with *Neodiplostomum seoulensis* (Seo, Rim and Lee, 1964) Hong and Shoop, 1994, degenerative changes of villi and hyperplasia of crypts sustained over 2 weeks after infection (Lee *et al.*, 1985). Because these morphological

changes were basically reversible, they were recovered by 2 or 3 weeks after infection, although very heavily infected mice died of intestinal bleeding and malabsorption in 2 weeks after infection (Lee *et al.*, 1989; Huh *et al.*, 1988). Gushima (1939) demonstrated that repeated infection of rats or mice with *Metagonimus* could evoke a stronger host resistance. According to Kang *et al.* (1983), reinfection of dogs with *M. yokogawai* induced lower worm recovery rates, lower intestinal site migration of parasites and faster recovery of the small intestinal pathology. Although the host intestinal tissue is recovered histopathologically, it is still uncertain whether the mucosa is recovered functionally or not.

• Received Dec. 28 1994, accepted after revision Jan. 22 1995.

• This study was supported in part by NON DIRECTED RESEARCH FUND, Korea Research Foundation, 1993.

* Corresponding author

To understand the correlation between morphological changes and functional derangements of the small intestine, the activity of brush border membrane bound enzyme is a useful index. It is known that the brush border membrane bound enzymes are on the surface of the brush border of the enteroepithelial cells. The enzymes are disaccharidases (sucrase, maltase, lactase, trehalase), peptidases (aminopeptidase N, dipeptidyl aminopeptidase IV, r-glutamyl transpeptidase) and alkaline phosphatase (Andersen *et al.*, 1983; Song *et al.*, 1986; Raul *et al.*, 1988). They are engaged in the process of the last digestion before absorption. Their activities are the highest in the upper and middle jejunum (Asp *et al.*, 1975).

The first human infection case with *N. seoulensis* suffered from severe gastro-intestinal symptoms (Seo *et al.*, 1982). He was in acute phase of a primary infection. However, further cases showed no recognizable symptoms probably due to chronic or repeated infection (Hong *et al.*, 1984 & 1986). In order to understand this difference better, we observed both morphological and functional changes in the small intestine of rats primary or reinfected with *N. seoulensis*.

MATERIALS AND METHODS

1. Experimental infection of rats with *N. seoulensis*

Sprague-Dawley rats were purchased from the animal colony of Seoul National University. They were treated with praziquantel, mebendazole and metronidazole during adaptation period of a week. Metacercariae of *N. seoulensis* were collected after artificial

digestion of snakes (*Rhabdophis tigrina*), which had been captured nearby Chinju, Kyong-sangnam-do.

The rats were divided into three groups such as uninfected control, primary infection group, and secondary infection (reinfection) group. For the primary infection group, 500 metacercariae were infected per rat and for the reinfection group, primary infection rats were treated with praziquantel after 2 weeks. They were reinfected with the same amount of metacercariae at 3 weeks after the treatment. The rats were sacrificed 3, 7 and 14 days after primary and reinfection. Fifteen rats per group were used for worm recovery and 6 rats per group for histopathological observation. Enzyme activity were compared 14 days after infection only and used 10 rats per group (Fig. 1).

2. Worm recovery from the rats

The small intestines of the rats were resected and the lumen was opened and dipped in 0.85% cold physiologic saline for 2 hrs. The isolated worms were collected and counted.

3. Histopathological observation

Two rats per each group were used for pathological examination. Two segments of the small intestine, one 5 cm distal from pylorus and the other 10 cm distal from Treitz ligament, were fixed in 10% neutral formalin. The tissues were dehydrated by successive changes of alcohols, cleared in xylene, embedded in paraffin, and sectioned in 4 μm thickness. After stain with hematoxylin and eosin, the sections were examined with light microscope.

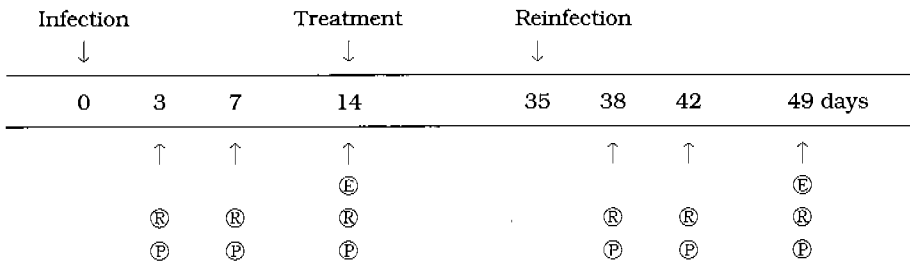


Fig. 1. Flow chart of the experimental design. Ⓜ: measurement of enzyme activities, Ⓜ: recovery of adult worms, Ⓟ: observation of histopathology

4. Enzyme activity assay

1) Tissue preparation: The duodenum (from the pylorus to the Treitz ligament) and proximal jejunum (proximal one-third of the small intestine from the Treitz ligament to the ileo-cecal junction) of 10 rats per group were removed. The mucosal layer of the removed segments was collected by scraping with a slide glass on the ice chamber. The scraped tissues were homogenized for 1 minute by a teflon homogenizer (Model S63C, Tri-R instruments, Inc., NY) in 30 vol. of 0.05 M mannitol-2 mM Tris HCl buffer (pH 7.0). The concentration of CaCl_2 of the homogenate was made 10 mM by adding 0.4 M CaCl_2 . The mucosal homogenate was sonicated by a sonicator (Model W-380, Heatsystem-Ultrasonics, INC, NY) for 30 seconds.

2) Alkaline phosphatase: Alkaline phosphatase activity was assayed using p-nitrophenol phosphate as substrate at pH 10.0. The reaction mixture containing 190 mM NaHCO_3 , 4 mM substrate, 5 mM MgCl_2 , 1 mM ZnSO_4 and 10 μl of prepared mucosa was incubated for 30 min. at 37°C. The reaction was stopped by adding 2.5 ml of 0.02 N NaOH, and absorbance was measured at 400 nm with a spectrophotometer (Uvikon spectrophotometer, Kontron Instruments, Zürich).

3) Disaccharidases: The activities of sucrase and maltase were measured. The 0.056 M substrate buffer solution was made by mixing of 0.1 M sodium maleate buffer, pH 6.0, and the disaccharides. TGO (tris glucose oxidase o-dianisidine reagent) solution was made with 100 ml of 0.5 M Tris HCl buffer (pH 7.0), 4 mg of glucose oxidase, 0.5 mg of peroxidase, and 100 mg of o-dianisidine. This solution was stabilized for 3 days at 4°C before use. The substrate buffer solution, 50 μl , and the same volume of mucosal homogenates were mixed and incubated for 30 min. at 37°C to hydrolyse substrate. Then for color reaction, 1.5 ml of TGO solution was added. After 30 min. incubation at 37°C, 0.75 ml of 50% H_2SO_4 was added to stop the reaction. The absorbance was measured at 530 nm.

4) Enzyme activity units: The one unit of enzyme activity corresponded to the hydrolytic activity of 1 μmol substrate per minute at

37°C. Protein was measured by the modified method of Lowry *et al.* (1951).

RESULTS

1. Worm recovery rate

The worm recovery rates of reinfection group were lower than the primary infection group. The highest recovery rate was observed at 7 days in both primary infection and reinfection groups. The percentage of recovery rates were shown in Fig. 2.

2. Histopathological findings (Table 1)

1) Duodenum: In the uninfected group, the villus/crypt (V/C) height ratio was 3:1 and a few inflammatory cell, mainly plasma cells, were infiltrated in stroma. In the primary infection group, villous changes such as tip blunting, shortening and fusion and increased number of goblet cells appeared from 1 week after infection. But these findings were observed from 3 days in the reinfection group. After 14 days, the V/C ratio was decreased in primary infection group, but increased in the reinfection group.

2) Jejunum: The distinct morphological changes of the villi were not observed in all the

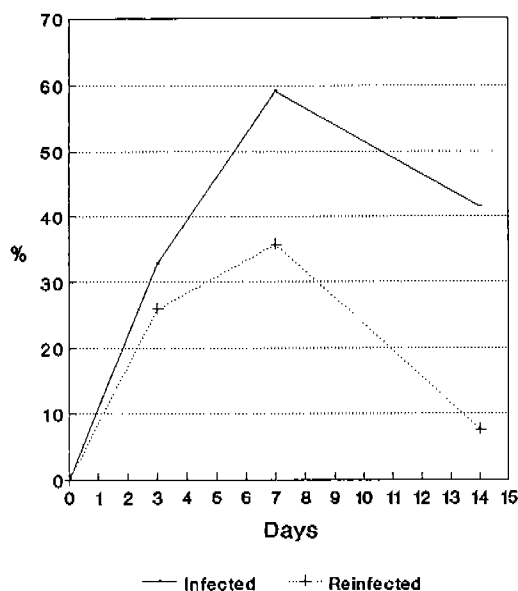


Fig. 2. Recovery rates of *N. seoulensis* from the experimentally infected rats.

Table 1. Histopathological findings of the small intestine in rats infected with *N. seoulensis*

Histopathological lesion	Findings by rat groups						
	Control	Primary infection			Reinfection		
		3D	7D	14D	3D	7D	14D
	d/j	d/j	d/j	d/j	d/j	d/j	d/j
Villous changes							
shortening	-/-	-/-	+/-	+/-	+/-	+/-	+/-
blunting	-/-	-/+	+/+	+/+	+/+	+/+	+/-
fusion	-/-	-/+	+/-	+/-	+/-	+/-	+/-
epithelial erosion	-/-	+/-	+/-	+/-	+/-	+/-	+/-
epithelial compression	-/-	+/-	+/-	+/-	+/-	+/-	+/-
goblet cell	-/-	-/-	↑/-	↑/-	↑/↑	↑/↑	↑/-
Stromal changes							
edema	-/-	-/+	+/+	+/+	-/+	+/+	+/+
vascular congestion	-/-	-/-	+/-	+/+	+/+	+/+	+/+
cell infiltration	+/+	+/+	+/+	+/+	+/+	+/-	+/-
Submucosal layer							
vascular congestion	-/-	+/+	+/+	+/+	+/+	+/+	+/+
cell infiltration	-/-	-/±	+/-	+/+	+/-	+/-	+/-
V/C ratio	3:1/3:1	3:1/3:1	2.5:1/3:1	1:2/3:1	1.5:1/2.5:1	1.5:1/3:1	2:1/3:1

-: disappear; +: appear; ↑: increase; D: days; d: duodenum; j: jejunum

infected groups. But the number of goblet cells was increased only in the reinfection group after 3 days of infection, and it became same with that of uninfected control at 2 weeks. The inflammatory cells in the stroma were mostly plasma cells in the primary infection group, whereas they were eosinophils in the reinfection group. The V/C ratio was not much different from the control group in all the infected ones.

3. Changes of the enzyme activity
(Table 2)

1) Alkaline phosphatase: The enzyme activity of the duodenum was higher than that of jejunum in control group. In duodenum, the activity of primary infection group decreased as 52.5% (P < 0.01) as that of the control group. Whereas, there was no significant difference between reinfection and control groups. In jejunum, the changes of activities were not observed between groups.

2) Sucrase: The enzyme activity was not much different according to the intestinal

location in the control group. In the duodenum, the activity of primary infection group decreased as 61.2% (P < 0.01) as that of the control group. On the other hand, the activity of reinfection group increased as 157% (P < 0.01) as that of the control group. In the jejunum, the activity of reinfection group increased as 126.7% (P < 0.01).

3) Maltase: No significant enzyme activity changes were observed between groups and locations of the small intestine.

DISCUSSION

In the dog reinfected with *Metagonimus yokogawai*, decreased worm recovery rate, milder villous change and moving to the distal intestine of the pathological lesion were observed (Kang *et al.*, 1983). In the present study, the worm recovery rates of reinfection group were lower than that of the primary infection group. Especially at 2 weeks after reinfection, the worm recovery rate was markedly decreased than that of the primary

Table 2. Mean enzyme activities in the brush border of small intestine of rats infected with *N. seoulensis* (unit: μ /mg protein)

Locations	Enzymes	Activities (% change) by group			
		Control I ^{a)}	Primary infection	Control II ^{b)}	Reinfection
Duodenum	Alk. phosphatase	1849.7 \pm 447.8	971.5 \pm 350.1 (52.5 ^{c)}	1671.5 \pm 371.6	1618.3 \pm 221.9 (96.8)
	Sucrase	32.7 \pm 7.6	18.5 \pm 6.9 (61.2 ^{c)}	25.8 \pm 6.4	40.5 \pm 5.5 (157.0 ^{c)}
	Maltase	192.9 \pm 27.2	172.7 \pm 19.7 (89.5)	160.7 \pm 15.5	168.8 \pm 28.7 (105.0)
Jejunum	Alk. phosphatase	996.8 \pm 324.5	902.4 \pm 183.1 (90.5)	1125.7 \pm 287.0	1271.5 \pm 143.2 (112.9)
	Sucrase	38.1 \pm 8.4	41.1 \pm 10.3 (107.9)	43.8 \pm 6.5	55.5 \pm 6.6 (126.7 ^{c)}
	Maltase	188.6 \pm 24.2	174.8 \pm 18.8 (92.7)	151.8 \pm 17.1	159.4 \pm 19.8 (105.0)

^{a)}Control I: control for primary infection group. ^{b)}Control II: control for reinfection group. ^{c)}p < 0.01.

infection. Probably it was related with the "self-cure" phenomenon suggested by Stoll in 1929. The phenomenon could be related with the mucosal defense by actions of intraepithelial lymphocytes, macrophages, mast cells, T-cells, and goblet cells. The stimulated macrophages, mast cells and T-cells by combined parasite Ag and specific Ab secreted goblet cell stimulating factor (prostaglandins, proteinases), so increased mucus secretion by increased goblet cells, that the immune expulsion of intestinal helminth, for example, *Nippostrongylus brasiliensis* was achieved (Tse & Chadee, 1991). In case of protozoa, the mucous layer formed on the surface of the mucosal epithelial cells inhibited the contact of *Entamoeba histolytica* and *Giardia lamblia* to the mucosal epithelial cells, and made mucosal penetration of those parasites impossible (Chadee *et al.*, 1988). In the present study, probably the earlier increase and wide spreading in the small intestine of goblet cells were related with the antibody stimuli produced with the primary infection. Thus the worm expulsion in the reinfection group occurred earlier.

The villous changes by pathological examination were nonspecific findings which could be seen in other intestinal trematode infections such as *M. yokogawai* and *Echinostoma hortense* (Chai, 1979; Lee *et al.*, 1990). But in *N. seoulensis* reinfection, these findings appeared earlier in the duodenum. V/C ratio increased more in the reinfection group at 2 weeks after infection. Probably the earlier process of pathological healing was due to the earlier worm expulsion, because the

mechanical stimuli by the worm and the localized cell mediated immune reaction could be responsible for the histopathological changes of the duodenum. By the experiment of Ferguson and Jarrett (1975), when *N. brasiliensis* was infected to athymic albino rats, the infection period was maintained longer and the pathological lesion of the small intestine was hardly formed. Thus T-cell mediated hypersensitive reaction was suggested to be related to the villous and crypt changes (Ferguson and Jarrett, 1975).

The activities of sucrase, trehalase and alkaline phosphatase of the mouse small intestine infected with *N. seoulensis* changed markedly at the duodenum and upper jejunum (Lee *et al.*, 1991). These activities were lowest at 12 days after infection when the pathologic lesion of the small intestine appeared most intensively (Lee *et al.*, 1985; Lee *et al.*, 1991). Therefore we compared the enzyme activities only at 2 weeks after infection between the primary infection and reinfection groups. The activities of disaccharidases and alkaline phosphatase in *N. seoulensis* infected mouse duodenum decreased as half of the uninfected control group from 7 to 32 days after infection (Lee *et al.*, 1991). In the present study, the enzyme activities in the duodenum of the reinfection group were recovered at 2 weeks after infection. Increased epithelial cells which had normal enzyme activities due to morphological recovery might be one of the reasons. On the contrary, it was hard to explain the fact that sucrase activity of the duodenum in the reinfection group increased

more than in the uninfected control group. The finding of the decreased enzyme activities in the primary infected group was also related with the mucosal degenerative changes of the small intestine. In other words, loss of the brush border membrane and the increased population of immature cells due to increased desquamation on the mucosal surface by mechanical stimulation of worms would be resulted in decreased enzyme activities in the primary infection group. However, the degenerative changes of the mucosa only could not explain all of the decreased enzyme activities, because in case of *G. lamblia* infection, disaccharidase activities decreased without morphological changes of the small intestine (Burret *et al.*, 1990). It was suggested that the decreased enzyme activities could inhibit the last stage of nutrient digestion in the small intestine, and consequently, osmotic diarrhea would be induced.

In the first human case of *N. seoulensis*, the patient suffered from acute gastrointestinal symptoms and fever from 5 days after ingestion of the viscera of the snakes (Seo *et al.*, 1982). Among the fifteen cases of field survey or ten cases of soldiers of Korean Army, however, no one had clinical manifestations (Hong *et al.*, 1984 & 1986). It was thought that the former was a typical case of acute primary infection and the latter typical cases of chronic repeated infection, because the latter cases ate the snake or frog muscle several times which had small amount of metacercariae (Hong *et al.*, 1986). The faster worm expulsion, recovery of intestinal morphology and the enzyme activities as observed in this study could partly explain the chronic asymptomatic patients encountered in the field (Hong *et al.*, 1984 & 1986).

REFERENCES

- Andersen KJ, Schjonsby H, Skagen DW (1983) Jejunal mucosal enzymes in untreated and treated coeliac disease. *Scand J Gastroenterol* **18**(2): 251-256.
- Asp NG, Gudmand-Hoyer E, Andersen B, Berg NO, Dahliqvist A (1975) Distribution of disaccharidases, alkaline phosphatase, and some intracellular enzymes along the human small intestine. *Scand J Gastroenterol* **10**(3): 648-651.
- Burret A, Gall DG, Nation N, Olson ME (1990) Intestinal protozoa and epithelial cell kinetics, structure and function. *Parasitology Today* **6** (12): 375-380.
- Chadee K, Johnson ML, Orozco E, Petri WA, Ravdin JI (1988) Binding and internalization of rat colonic mucins by the galactose/N-acetyl-D-galactosamine adherence lectin of *Entamoeba histolytica*. *J Inf Dis* **158**(2): 398-406.
- Chai JY (1979) Study on *Metagonimus yokogawai* (Katsurada, 1912) in Korea V. Intestinal Pathology in experimentally infected albino rats. *Seoul J Med* **20**(2): 104-117.
- Ferguson A, Jarret EEE (1975) Hypersensitivity reactions in the small intestine I. Thymus dependence of experimental 'partial villous atrophy'. *Gut* **16**: 114-117.
- Gushima H (1939) On the development of *Metagonimus yokogawai* in the mouse and chicken. *Igaku Kenku* **13**(3): 637-655.
- Hong ST, Cho TK, Hong SJ, Chai JY, Lee SH, Seo BS (1984) Fifteen human cases of *Fibricola seoulensis* infection in Korea. *Korean J Parasitol* **22**(1): 61-65.
- Hong ST, Chai JY, Lee SH (1986) Ten human cases of *Fibricola seoulensis* infection and mixed one with *Stellantchasmus* and *Metagonimus*. *Korean J Parasitol* **24**(1): 94-96.
- Hong ST, Shoop WL (1994) *Neodiplostomum seoulensis* N. Comb. (Trematoda: Neodiplostomidae). *J Parasitol* **80**(4): 660-663.
- Huh S, Chai JY, Hong ST, Lee SH (1988) Clinical and histopathological findings in mice heavily infected with *Fibricola seoulensis*. *Korean J Parasitol* **26**(1): 45-53.
- Kang SY, Cho SY, Chai JY, Lee JB, Jang DH (1983) A study on intestinal lesions of experimentally reinfected dogs with *Metagonimus yokogawai*. *Korean J Parasitol* **21**(1): 58-73.
- Lee CG, Hong ST, Ko KW, *et al.* (1991) Activities of brush border membrane bound enzymes in the small intestine of mice infected with *Fibricola seoulensis*. *Seoul J Med* **32**(3): 139-148.
- Lee SH, Yoo BH, Hong ST, Chai JY, Seo BS, Chi JG (1985) A histopathological study on the intestine of mice and rats experimentally infected by *Fibricola seoulensis*. *Korean J Parasitol* **23**(1): 58-72.
- Lee SH, Noh TY, Sohn WM, Kho WG, Hong ST, Chai JY (1990) Chronological observation of

- intestinal lesions of rats experimentally infected with *Echinostoma hortense*. *Korean J Parasitol* **28**(1): 45-52.
- Lee SH, Kim BI, Hong ST, Sohn WM, Chai JY (1989) Observation of mucosal pathology after praziquantel treatment in experimental *Fibricola seoulensis* infection in rats. *Korean J Parasitol* **27**(1): 35-40.
- Lowry OH, Rosebrough NJ, Farr AL, Randall RJ (1951) Protein measurement with the Folin phenol reagent. *J Biol Chem* **193**: 265-275.
- Raul F, Gosse F, Doffoel M, Darmenton P, Wessely JY (1988) Age related increase of brush border enzyme activities along the small intestine. *Gut* **29**: 1557-1563.
- Seo BS, Rim HJ, Lee CW (1964) Studies on the parasitic helminths of Korea I. Trematodes of Rodents. *Korean J Parasitol* **2**(1): 20-26.
- Seo BS, Lee SH, Hong ST, Hong SJ, Kim CY, Lee HY (1982) Studies on intestinal trematodes in Korea V. A human case infected by *Fibricola seoulensis* (Trematoda: Diplostomatidae). *Korean J Parasitol* **20**(2): 93-99.
- Song IS, Yoshioka M, Erickson RH, Miura S, Guan D, Kim YS (1986) Identification and characterization of brush-border membrane-bound neutral metalloendopeptidases from rat small intestine. *Gastroenterology* **91**: 1234-1242.
- Stoll NR (1929) The occurrence of self-cure and protection in typical nematode parasitism. *J Parasitol* **15**: 107-148.
- Tse SK, Chadee K (1989) The interaction between intestinal mucus glycoproteins and enteric infections. *Parasitology Today* **7**(7): 163-172.

=초록=

서울주걱흡충의 재감염이 흰쥐 소장의 조직병리 및 미소용모막효소 활성도에 미치는 영향

유재란¹⁾, 홍성태²⁾, 채종일²⁾, 이순형²⁾

건국대학교 의과대학 기생충학교실¹⁾, 서울대학교 의과대학 기생충학교실 및 풍토병연구소²⁾

서울주걱흡충(*Neodiplostomum seoulensis*) 재감염시 숙주에 미치는 영향을 알아보기 위해 총체 회수율, 소장의 조직병리 및 미소용모막효소 활성도를 관찰하였다. 자연감염된 뱀에서 피낭유충을 얻어 500개씩 흰쥐에 감염시키고 20일 후에 프라지퀀텔로 치료하였다. 치료후 3주째에 피낭유충 500개씩 경구투여하여 재감염 시킨다음 3일, 1주, 2주 후에 도살하여 일차감염군과 비교하였다. 총체회수율은 일차감염시 각각 32.8%, 59.2%, 41.5%에서 재감염시 25.9%, 35.7%, 7.6%로 감소되었는데 특히 2주후에 급격히 감소되었다. 십이지장의 조직병리 소견은 일차감염시 1주 후부터 음모의 융합, 단축등의 퇴행성 변화와, 선와의 증식, 기질층의 염증세포 침윤 등이 나타나 2주 까지 지속되었으나 재감염시는 3일 후부터 병변이 나타나다가 1주째부터 회복되었다. 미소용모막효소 활성도 측정결과 십이지장에서 일차감염시 alkaline phosphatase와 자당분해효소의 활성도가 대조군의 절반수준으로 감소하였으나 재감염시에는 대조군 수준과 동일하거나 오히려 증가하였다. 이상의 결과로 이 흡충의 재감염시 총체의 배출이 빨라짐과 동시에 형태학적으로 회복이 빨리 이루어지며 기능적으로도 소장의 미소용모막효소 활성도의 회복이 빠르게 이루어짐을 알 수 있었다.

(기생충학잡지 33(1): 37-43, 1995년 3월)