

## Two rare cases of *Diphyllobothrium latum* parvum type infection in Korea

Soon-Hyung Lee<sup>1)</sup>, Jong-Yil Chai<sup>1)\*</sup>, Min Seo<sup>1)</sup>, Jina Kook<sup>1)</sup>, Sun Huh<sup>2)</sup>,  
Yong-Suk Ryang<sup>3)</sup> and Yung-Kyum Ahn<sup>4)</sup>

Department of Parasitology and Institute of Endemic Diseases, Seoul National University College of Medicine, Seoul 110-799<sup>1)</sup>, Department of Parasitology, College of Medicine, Hallym University, Chunchon 200-702<sup>2)</sup>, Department of Medical Technology, College of Health Sciences, Yonsei University, Wonju 222-701<sup>3)</sup>, and Department of Parasitology, Yonsei University Wonju College of Medicine, Wonju 220-701, Korea<sup>4)</sup>

**Abstract:** Two rare cases of human infection with parvum (dwarf) type of *Diphyllobothrium latum* [syn. *D. parvum* (Stephens, 1908)], were discovered in Korea. The first case was a 46-year old housewife, from whom a kind of pseudophyllidean tapeworm eggs was detected in the feces. She was treated with praziquantel and purged, and a complete strobila with scolex, 120 cm in total length, was recovered. She recalled that she had eaten raw trouts at a raw-fish restaurant near the Chungju Lake. Another patient was a 22-year old medical student (male), who used to eat raw sea-foods. He discovered a chain of tapeworm proglottids, 15 cm in length, discharged spontaneously in his stool and brought it for identification. The worms from the two cases were compatible with *D. parvum* (Stephens, 1908) of which the taxonomic significance has long been questioned. After a detailed morphological study and review of literature, we designated the worms as *D. latum* parvum type. This is the first report on the occurrence of this rare type of *D. latum* infection in Korea.

**Key words:** *Diphyllobothrium latum* parvum type, trout, sea-food, human, case report

Human diphyllobothriasis is chiefly caused by infection with *Diphyllobothrium latum* through eating raw or improperly cooked fish such as salmon, trout or perch. However, species other than *D. latum* have been reported also causing human infections in many countries including Japan and Korea. They include *D. yonagoense* (Yamane *et al.*, 1981; Lee *et al.*, 1989), *D. pacificum* (Kamo *et al.*, 1982), *D. cameroni* (Kamo *et al.*, 1981), *D. scoticum* (Fukumoto *et al.*, 1988), and *D. hians* (Kamo *et al.*, 1988).

*D. parvum* (Stephens, 1908), the dwarf fish

tapeworm morphologically similar to *D. latum*, is another kind reported from Australia, Rumania and Japan (Leon, 1915; Yoshida and Ogata, 1924), although its taxonomic validity remained uncertain. Recently, the authors found 2 rare cases of human infection by this tapeworm in Korea. After a detailed morphological study and review of literature, we designated the worms as *D. latum* parvum type.

One patient (Case 1), a 46 year-old Korean housewife was quite healthy, but eggs of a pseudophyllidean tapeworm were discovered from her feces in February 1988. The eggs were typical oval shape (Fig. 2), and tinged with yellow-brown color. Their size (10 eggs

• Received May 6 1994, accepted May 24 1994.

\* Corresponding author

were measured) ranged from 55.6 to 59.6  $\mu\text{m}$  in length (av. 57.5  $\mu\text{m}$ ), and 33.1 to 40.7  $\mu\text{m}$  (av. 37.4  $\mu\text{m}$ ) in width. They were slightly smaller than but closely resembled *D. latum*, with an operculum and shoulder rims at the anterior end, and an abopercular protuberance at the posterior end (Fig. 2). Under the basis of laboratory studies, she had mild anemia (hemoglobin 11.6 g/dl, hematocrit 33.3%, RBC  $3.84 \times 10^6$ ) and elevated eosinophil count (6%).

She was treated with praziquantel 13 mg/kg and purged with 30 g  $\text{MgSO}_4$  an hour later. From her diarrhetic stool, a complete tapeworm strobila with scolex was recovered. The specimen (Fig. 1) was characteristically small, 120 cm in length and 0.4 cm in maximum breadth, only 1/3-1/5 length of typical *D. latum*, and consisted with total 201 proglottids. This feature was compatible with the descriptions of *D. parvum* (Stephens, 1908). She recalled she had eaten three trouts with her family at a raw-fish restaurant near the Chungju Lake a year before. The eggs were also discovered from the stool of her husband, but the adult worm was not recovered.

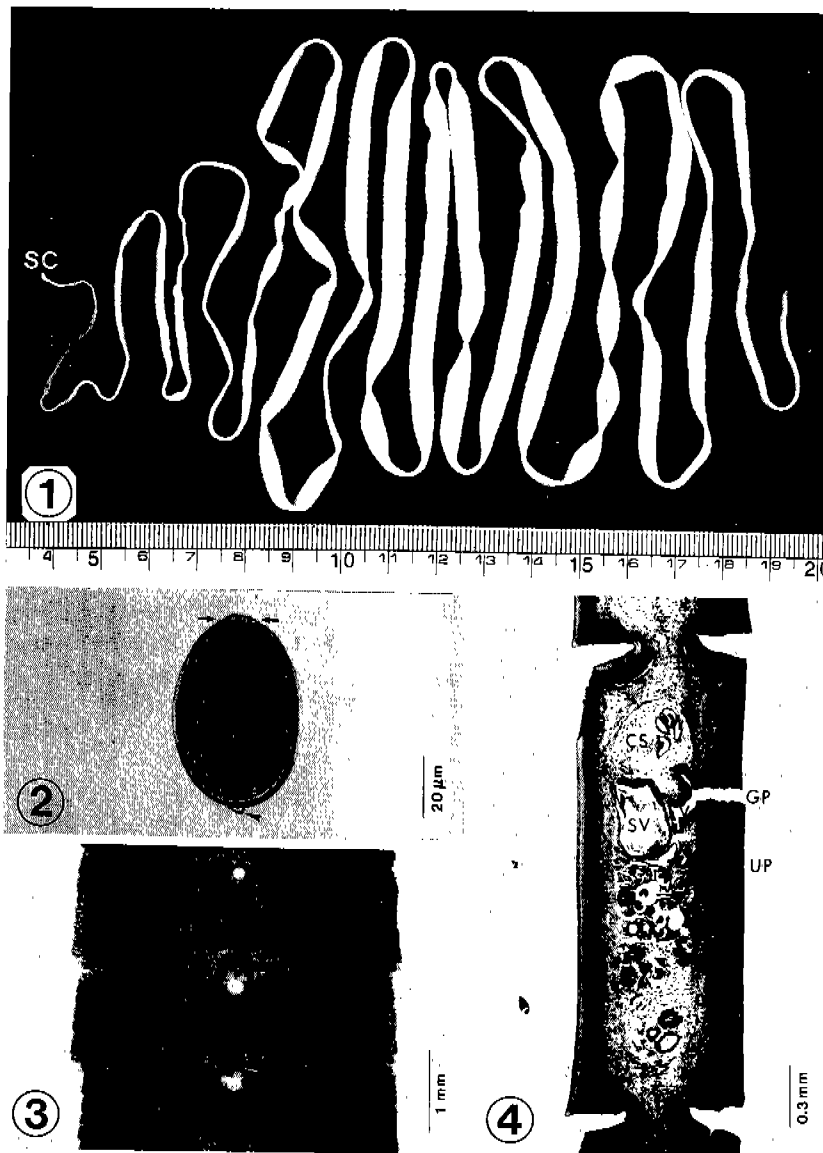
Another patient (Case 2) was a 22-year old medical student (male), residing in Seoul. When he observed a chain of whitish, thread-like tapeworm segments spontaneously discharged in his stool, he collected it and brought to the Department of Parasitology, Seoul National University College of Medicine, in June 1988. The segment was 15 cm long, and consisted of mature and gravid proglottids of a pseudophyllidean tapeworm, without scolex. Each proglottid was very small, 0.28-0.32 cm broad and 0.10-0.12 cm long, and compatible with *D. parvum* (Stephens, 1908). He used to eat raw sea-foods and recalled he had consumed raw flatfish, sea eel, ormer, and trepang in Ulchin, Kangwon-do 1 month before the discharge of the proglottids. He did not complain of any special symptoms.

From the specimens recovered from Case 1 and Case 2, a part of proglottids was cut and fixed in 10% formalin under slight pressure, and whole mounts or 5  $\mu\text{m}$  longitudinal thin sections were made for a detailed morphological study. The genital opening of each proglottid was situated on the midline,

and the uterus appeared as rosettes each with four to six loops (Fig. 3). Although the size of each organ was smaller than that of *D. latum*, the cirrus opening and vagina made a common genital pore, and the uterine pore is opened separately (Fig. 4), which was consistent with *D. latum*. These observations confirmed that the present specimens are morphologically compatible with *D. parvum* and *D. latum*, except in the small size of their body, eggs, and internal organs. Under the consideration that *D. parvum* is not a distinct species but a morphological variant of *D. latum*, we proposed to diagnose our specimens as *D. latum parvum* type.

*D. parvum* was first found from a man in Australia, and as the worm was much smaller in size than *D. latum*, Stephens (1908) created a new species for this worm. Later, human infections with this worm were reported from Rumania and Japan (Leon, 1915; Yoshida and Ogata, 1924). Creating as a new species, Stephens (1908) gave several differential characters of his species, which were based on external morphology, especially in the size of the worm and eggs. However, the taxonomic validity of *D. parvum* has long been put to questions. For example, Magath (1929) reported that a poorly developed *D. latum* specimen obtained from an experimentally infected dog was quite similar to *D. parvum*, and considered *D. parvum* as a young stage of *D. latum*. Eguchi (1973) also recovered several proglottids quite similar to those of *D. parvum* after an experimental infection of *D. latum* to man, dog and cat.

In the present study, we made longitudinal sections of the proglottids from our specimens for a more detailed morphological study, but could not find any differential feature from those of *D. latum*, except in the size of internal organs. Therefore, we adopted the name *D. latum parvum* type for this rare type of fish tapeworm, *D. parvum* (Stephens, 1908). However, we could not completely agree with Magath (1929) in the point that *D. parvum* is merely a young stage of *D. latum*, since the age of infection of our Case 1 was about 1-year, based on the history of eating raw trout by the patient. Rather, we regard *D. parvum* a morphological variant of *D. latum*.



**Fig. 1.** A complete strobila with scolex (SC) of *D. latum* parvum type recovered from Case 1 after praziquantel treatment. Its whole length was only 120 cm, and the maximum breadth 0.4 cm. **Fig. 2.** An egg of *D. latum* parvum type obtained from the feces of Case 1. The operculum (arrows) and the abopercular protuberance (arrowhead) are distinctively seen. **Fig. 3.** Gravid proglottids of *D. latum* parvum type discharged from Case 2, showing medially located genital opening and rosette form uterine branches. Acetocarmine stain. **Fig. 4.** Sagittal section of mature proglottids of *D. latum* parvum type from Case 2, showing the common genital pore (GP) incorporating the cirrus opening and vagina (V). The cirrus sac (CS), seminal vesicle (SV), and uterine pore (UP) are also distinctively seen. H-E stain.

*D. latum* is worldwide distributed, but not a common parasite of humans, and its prevalence in Korea is not high. The first worm-proven case of *D. latum* infection was first reported by Cho *et al.* (1971), and until present total 29 cases have been reported in

the available literature (Lee *et al.*, 1983 & 1989; Min, 1990). However, with the increasing popularity of eating raw salmon, trout and perch, this tapeworm infection tends to increase in Korea.

REFERENCES

Cho SY, Seo BS, Ahn JH (1971) One case report of *Diphyllobothrium latum* infection in Korea. *Seoul J Med* **12**: 157-163.

Eguchi S (1973) *Diphyllobothrium latum* (Linnaeus, 1758). *Progress of Med Parasit in Japan* **5**: 129-144.

Fukumoto S, Yazaki S, Maejima J, Kamo H, Takao Y, Tsutsumi H (1988) The first report of human infection with *Diphyllobothrium scoticum*. *Jpn J Parasitol* **37**: 84-90.

Kamo H, Maejima J, Yazaki S, Otsuru M, Hasegawa H, Kuniyoshi S, Asato R (1982) Occurrence of human infection with *Diphyllobothrium pacificum*. *Jpn J Parasitol* **31**: 165-170.

Kamo H, Yamane Y, Kawashima K (1981) The first record of human infection with *Diphyllobothrium cameroni* Rausch, 1969. *Jpn J Trop Med Hyg* **9**: 199-205.

Kamo H, Yazaki S, Fukumoto S, Fujino T, Koga M, Ishii Y, Mastuo E (1988) The first human case infected with *Diphyllobothrium hians*. *Jpn J Parasitol* **37**: 29-35.

Leon N (1915) Notices helminthologiques. *Centrabl f Bakt* (Abt. 1) **76**: 522.

Lee SH, Seo BS, Chai JY, Hong ST, Hong SJ, Cho SY (1983) Five cases of *Diphyllobothrium latum* infection. *Korean J Parasit* **21**(2): 150-156 (in Korean).

Lee SH, Chai JY, Hong ST, Sohn WM, Huh S, Cheong EH, Kang SB (1989) Seven cases of *Diphyllobothrium latum* infection. *Korean J Parasit* **27**(3): 213-216(in Korean).

Magath TB (1929) Experimental studies on *Diphyllobothrium latum*. *Am J Trop Med* **9**: 17-48.

Min DY (1990) Cestodes infections in Korea. *Korean J Parasit* **28**(Suppl.): 123-144

Stephens JWW (1908) Two new human cestodes and a new linguatulid. *Ann Trop Med Parasit* **1**: 549-551.

Yamane Y, Kamo H, Yazaki S, Fukumoto S, Maejima J (1981) On a new marine species of the genus *Diphyllobothrium* (Cestode: Pseudophyllidea) found from a man in Japan. *Jpn J Parasitol* **30**: 101-111.

Yoshida S, Ogata S (1924) Two rare specimens of human cestodes. *Ann Med Parasit* **18**(1): 15-23.

=국문초록=

광절열두조충 parvum형에 의한 희귀한 인체 감염 2례

이순형<sup>1)</sup>, 채종일<sup>1)</sup>, 서민<sup>1)</sup>, 국진아<sup>1)</sup>, 허선<sup>2)</sup>, 양용석<sup>3)</sup>, 안영겸<sup>4)</sup>

서울대학교 의과대학 기생충학교실 및 풍토병연구소<sup>1)</sup>, 한림대학교 의과대학 기생충학교실<sup>2)</sup>, 연세대학교 보건과학대학 임상병리학과<sup>3)</sup>, 연세대학교 원주의과대학 기생충학교실<sup>4)</sup>

광절열두조충(*Diphyllobothrium latum*)의 parvum형(syn. *Diphyllobothrium parvum* (Stephens, 1908))에 의한 희귀한 인체 감염 2례를 발견하여 보고하고자 한다. 첫 환자는 46세 된 가정주부로서 대변검사에서 의엽조충류의 충란이 발견되어 프라지관텔과 하계를 투여하여 치료한 결과 두절이 있는 길이 120 cm인 열두조충의 완전한 충체 1마리를 회수하였다. 환자는 충주호 부근의 횡집에서 송어회를 먹은 적이 있다고 하였다. 또 한 명의 환자는 평소 각종 생선회를 즐겨 먹는 22세 남자 의과대학생으로, 대변에서 길이 15 cm 정도의 조충류 편질이 자연 배출되어 동정을 의뢰해 왔다. 자세한 형태학적 검토 결과 충체들은 *D. parvum*으로 과거 문헌에 기록된 충체와 동일하였으나 *D. parvum*의 분류학적 위치가 정립되어 있지 않으며, 충체, 충란 및 각 기관의 크기가 광절열두조충보다 작다는 점 이외에 별다른 차이점을 인정할 수 없었다. 따라서 본 충체들을 광절열두조충의 소형(parvum형)으로 동정하였고, 이 유형에 의한 국내 최초의 감염 증례들로 보고하는 바이다.

(기생충학잡지 31(2):117-120, 1994년 6월)