

Promoting role of *Clonorchis sinensis* infection on induction of cholangiocarcinoma during two-step carcinogenesis

Jae-Hyun Lee*, Hyun-Mo Yang, Ung-Bok Bak and Han-Jong Rim

Department of Parasitology and Institute for Tropical Endemic Diseases, College of Medicine
Korea University, Seoul 136-705, Korea

Abstract: Chronic *Clonorchis sinensis* (CS) infection is etiologically related to cholangiocarcinoma (CHCA) in human and animals. This study was carried out to clarify the role of CS infection on dimethylnitrosamine (DMN)-induced cholangiocarcinogenesis. Fifteen hamsters were administered with 15 ppm DMN for 4 weeks and one week later, the hamsters were infected with 15 metacercariae of CS (DMN → CS group). The other 15 hamsters were infected with CS and after 5 weeks they were treated with the drug, praziquantel. Again one week later, the hamsters were administered with DMN (CS → DMN group). The other 15 hamsters were administered with DMN and CS simultaneously (CS + DMN group). Histopathological examination of the livers showed CHCA with papillary or adenomatous hyperplasia of bile ductules in 3 of 15 hamsters of DMN → CS group and in 11 of 15 hamsters of DMN + CS group. These results suggest that CS infection to hamsters may have a promoting effect on the development of CHCA.

Key words: *Clonorchis sinensis*, cholangiocarcinoma, dimethylnitrosamine, two-step carcinogenesis, initiator, promoter

INTRODUCTION

By Haswell-Elkins *et al.* (1992), liver fluke-associated CHCA has never been widely studied, although it has several advantages as a model for carcinogenesis of human. First, the liver fluke infection appears to increase the susceptibility to carcinogens. Second, the liver fluke *per se* probably does not alter DNA directly. Third, the liver fluke can be eliminated by simple treatment with praziquantel.

The relationship of CS infection with the development of cholangiocarcinoma (CHCA) has been established by epidemiological studies (Hou, 1956; Kim *et al.*, 1974; Chung

and Lee, 1976). Some investigators had showed that CS infection might be a causative agent of CHCA (Hou, 1955; Flavell, 1981). Experimental animals such as rats, rabbits, guinea pigs and hamsters infected with CS alone have never developed bile duct tumors (Wykoff, 1958; Lee *et al.*, 1978a; Lee *et al.*, 1978b; Bhamarapravati *et al.*, 1978). They have the strong mitotic activity and proliferation of the bile duct epithelium but do not develop the bile duct tumor. Bile duct hyperplasia which was irritated by CS infection underwent a carcinomatous transformation through a stage of dysplasia (Kim, 1984).

Preston-Martin *et al.* (1990) suggested that cell proliferation was associated with the development of many human cancer and resulted in molecular genetic errors or altered growth control of malignant cells. Cell proliferation is required for the fixation of mutant cells for neoplastic transformation

* Received Jan. 29 1994, accepted after revision Mar. 4 1994.

* Corresponding author

(Cohen *et al.*, 1990). The incidence of cancer involves sequential generations of cells during two-stepwise carcinogenesis within which initiation and promotion can be phenomenologically defined (Farber, 1984). Development of CHCA may be resulted from a stepwise process involving two-stepwise carcinogenesis.

However, the evidence for a direct role of CS infection in liver carcinogenesis is still tentative. As the general pathway of carcinogenesis, CHCA may be induced through multiple steps that can be broadly divided into "initiation" and "promotion". The study was carried out to clarify the role of CS in the development of CHCA during two-step carcinogenesis.

MATERIALS AND METHODS

1. Animals

Syrian golden hamsters (the animal laboratory, College of Medicine, Korea University) weighing 50-60g were housed, five to a cage (polycarbonate) in a air conditioned

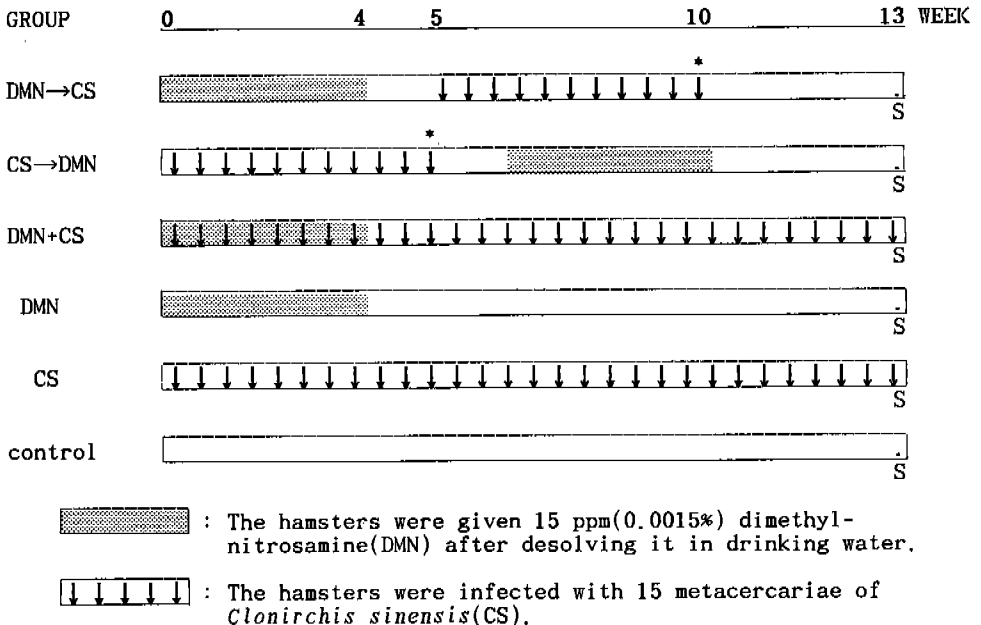
room ($22 \pm 1^\circ\text{C}$).

2. Clonorchis sinensis preparation

Collection of metacercariae of CS was prepared as described previously by Lee *et al.* (1993). The whole muscle of *Pseudorasbora parva* harbouring metacercariae of CS was removed and digested in artificial gastric juice (0.6% pepsin, pH 2) for half an hour at 37°C . The digested materials were filtered through a sieve ($147 \mu\text{m}$ in diameter) and washed several times with saline. The metacercariae of CS were identified under a stereoscopic microscope.

3. Experimental protocol

Ninety animals were divided into 6 groups and treated as indicated in the experimental design (see Fig. 1). For DMN → CS group, 15 hamsters were treated with 15 ppm dimethylnitrosamine (DMN) in drinking water for 4 weeks. After an interval of DMN-free water for one week, each hamster was infected with 15 metacercariae of CS and 5 weeks later treated with praziquantel (Biltricide®, 200



S: 15 hamsters were sacrificed in each group.

* : The hamsters were orally dosed with praziquantel for 3 days at 200 mg/kg B.W./day.

Fig. 1. Experimental design for study of the role of *C. sinensis* infection on the development of cholangiocarcinoma.

mg/kg body weight) for 3 days. For CS → DMN group, 15 hamsters were applied in the reverse order to DMN → CS group. The hamsters were infected with the same metacercariae of CS group and treated with praziquantel after 5 weeks. One week later, DMN solution was given for 4 weeks. For DMN + CS group, 15 hamsters were administered with CS and the DMN simultaneously, and the DMN maintained for 4 weeks. The hamsters of this group were not given praziquantel for treatment of clonorchiasis. Other fifteen hamsters in DMN group were treated with 15 ppm DMN alone, other 15 hamsters were infected with CS alone for CS group, and other 15 hamsters were nontreated as a control. All hamsters were sacrificed at 13 weeks after the beginning of the experiment.

4. Histopathological examination

After gross examination for sacrificed hamsters, the body weights were recorded. The livers and kidneys were fixed in 10% buffered formalin. Paraffin sections were prepared according to the routine histologic techniques. All sections were cut at approximately 4 μm and stained with haematoxylin and eosin (HE), and periodic acid-Schiff (PAS) for microscopic examination.

RESULTS

1. Gross observation

Changes of mean body weight of the hamsters in each group are compared. The animals in DMN → CS, CS → DMN and DMN + CS group showed changes of lighter body weight than those of DMN, CS and nontreated group during the experiment, and the growth ratio was significantly lower in the hamsters treated with DMN administration and/or CS

infection than in nontreated hamsters (control group). Gross findings of the livers in each group at 13 weeks after the beginning of the experiment are shown in Table 1. The livers in 3 of 15 hamsters of DMN → CS group and in 11 hamsters of DMN + CS group were pale and showed nodular cut surface 0.3 to 0.7 cm in diameter and were showed multiple subcapsular masses 0.3 to 0.5 cm in diameter or granular surface with white spots and gray-white nodules. Most animals infected with CS showed the dilatation of the extrahepatic bile duct and gallbladder.

2. Histopathological findings

Histopathological changes and tumor incidences are given in Table 2. This shows that 3 of 15 hamsters treated with DMN followed by CS infection (DMN → CS), and eleven of 15 hamsters administrated with DMN and CS simultaneously (DMN + CS) developed mucin-producing cholangiocarcinoma in liver, whereas the hamsters infected with CS followed by DMN treatment (CS → DMN) and other hamsters (DMN, CS and control group) showed no cholangiocarcinoma. The livers of hamsters infected with CS only developed papillary or adenomatous hyperplasia, and the inflammatory infiltration. In the portal triads of the liver of these hamsters, a lot of ovoid cells which were similar to bile duct cells were proliferated.

The tumors often occurred as multiple foci or nodules in every portal triad of the liver and were shown glandular acini which were very irregular and varied from small to large cysts. The bile duct showed adenomatous and papillary hyperplasia containing necrotic area. The cells were columnar or cuboidal and the nucleus was often large and hyperchromatic. The fibrous stroma was occasionally invaded

Table 1. Gross findings of the livers in the hamsters in each group

Group (No. of examined)	DMN → CS (15)	CS → DMN (15)	DMN + CS (15)	DMN (15)	CS (15)	Nontreated (15)
Lesions						
Granular surface with white spots	6	0	12	0	0	0
White nodule	5	0	12	0	0	0
Severe nodularity of cut surface	3	0	11	0	0	0
Dilatation of bile duct or gallbladder	8	7	15	0	15	0

Table 2. Histopathological changes and tumor incidence in the livers of the hamsters of each group

Lesions	Group (No. of examined)	DMN → CS (15)	CS → DMN (15)	DMN + CS (15)	DMN (15)	CS (15)	Nontreated (15)
Cholangiocarcinoma		3	0	11	0	0	0
Cholangiofibroma		3	0	3	4	0	0
Cholangiofibrosis		6	11	1	5	12	0
Bile duct hyperplasia		3	4	0	6	3	15

by small polymorphic cells, eosinophils, lymphocytes and plasma cells. In addition to cholangiocarcinoma, we observed cystic cholangioma and/or cholangiofibroma in 6 hamsters from DMN → CS group and in 14 hamsters from DMN + CS group. Cholangiofibroma in portal triads of DMN → CS and DMN + CS group appears to be in well differentiated pattern with severe cholangiofibrosis but some lining cells of the bile duct showed more or less atypism. Almost every hamster infected with CS in this experiment showed the dilatation of pre-existing bile duct and occasionally granulomatous inflammation with eggs of CS in the parenchyma of the liver.

DISCUSSION

Some investigations reported the synergism between the liver fluke infection and N-nitrosamides on the development of CHCA in the liver of hamsters (Thamavit *et al.*, 1978; Flavell and Lucas, 1982; Thamavit *et al.*, 1987; Lee *et al.*, 1993). These experimental evidences supported the importance of the liver fluke in induction of CHCA. In fact, epidemiological and pathological studies suggested that CS infection to human have the aetiological influence on the development of CHCA since the reports by Brumpt (1936) and Hou (1956).

The induction of CHCA was clearly observed in the hamsters administered with DMN and CS, but the role of CS infection is unclear in the development of CHCA (Lee *et al.*, 1993). In a number of models of chemical carcinogenesis, the multi-step mechanism give rise to two-step theory which can be divided into initiation and promotion (Farber, 1984). Initiation is a rapid, permanent change in target tissue induced by exposure to a

carcinogen, whereas promotion is a slow process showing a progression of reversible effects, and initiation must take place before promotion.

Three of 15 hamsters in CS-promoted group (DMN → CS), and eleven of 15 hamsters in CS-costimulated group (DMN + CS) had mucin-producing CHCA, whereas the hamsters in CS-initiated group (CS → DMN) did not have CHCA. DMN, a low dose of carcinogen, was used to initiate the liver cells in these groups. Therefore CS infection acts as a promoter in cholangiocarcinogenesis of hamsters initiated with DMN. The difference in incidence rate of CHCA between DMN + CS group and DMN → CS group may be due to the duration of CS infection and the applied time of the initiator.

Also, we hypothesize that bile duct proliferation induced by CS infection is associated with the development of cholangiocarcinoma. In addition to DMN used in this experiment, there are several environmental risk factors which can alter DNA of the biliary epithelium as following agents: (a) a lot of fungal toxins as aflatoxin B₁; (b) azo dye; (c) endogenously producing materials such as N-nitroso compounds. It is also suggested that the biliary lesions such as inflammatory and immune response in addition to proliferative response by CS infection enhance the susceptibility of biliary epithelium to these initiating agents.

In this study, we observed more incidence rate in CS + DMN hamsters with the infective period of 13 weeks than in DMN → CS hamsters with that of 5 weeks. This might show the promoting effect of CS infection on the development of CHCA during DMN-induced cholangiocarcinogenesis.

REFERENCES

- Bhamarapavati N, Thamavit W, Vajrasthira S (1978) Liver changes in hamsters infected with a liver fluke of man, *Opisthorchis viverrini*. *Am Soc Trop Med Hyg* **27**: 787-794.
- Brumpt E (1936) *Precisde Parasitologie* (6th edit.) Paris: Masson 607. (cited in Flavell, 1981)
- Chung CS, Lee SK (1976) An epidemiological study of primary liver carcinoma in Busan area with special reference to clonorchiasis. *Korean J Pathol* **10**(1): 33-46.
- Cohen SM, Ellwein LB (1990) Cell proliferation in carcinogenesis. *Science* **249**: 1007-1011.
- Farber E (1984) The multifil nature of cancer development. *Cancer Res* **44**: 4217-4223.
- Flavell DJ (1981) Liver fluke infection as an aetiological factor in bile duct carcinoma of man. *Trans Roy Soc Trop Med Hyg* **75**: 814-824.
- Flavell DJ, Lucas SB (1982) Potentiation by the human liver fluke, *Opisthorchis viverrini*, of the carcinogenic action of N-nitroso-dimethylamine upon the biliary epithelium of the hamster. *Br J Cancer* **46**: 985-989.
- Haswell-Elkins MR, Satarug S, Elkins DB (1992) *Opisthorchis viverrini* infection in Northeast Thailand and its relationship to cholangiocarcinoma. *J Gastroenterol Hepatol* **7**: 538-548.
- Hou PC (1955) The pathology of *Clonorchis sinensis* infestation of the liver. *J Pathol Bacteriol* **70**: 53-64.
- Hou PC (1956) The relationship between primary carcinoma of the liver and infestation with *Clonorchis sinensis*. *J Pathol Bacteriol* **72**: 293-246.
- Kim YI, Yang DH, Chang KR (1974) Relationship between *Clonorchis sinensis* infestation and cholangiocarcinoma of the liver in Korea. *Seoul J Med* **15**(3): 247-255.
- Kim YI (1984) Liver carcinoma and liver fluke infection. *Arzneim-Forsch/Drug Res* **34**(II): 1121-1126.
- Lee JH, Rim HJ, Bak UB (1993) Effect of *Clonorchis sinensis* and dimethyl-nitrosamine administration on the induction of cholangiocarcinoma in Syrian golden hamsters. *Korean J Parasitol* **31**: 21-30.
- Lee SH, Shim JS, Lee SM, Chi JG (1978a) Studies on pathological changes of the liver in albino rats infected with *Clonorchis sinensis*. *Korean J Parasit* **16**: 148-155.
- Lee YS, Lee SH, Chi JG (1978b) Ultrastructural changes of the hepatocytes and biliary epithelia due to *Clonorchis sinensis* in guinea pigs. *Korean J Parasit* **16**: 88-102.
- Preston-Martin S, Pike MC, Ross RK, Jones PA, Henderson BE (1990) Increased cell division as a cause of human cancer. *Cancer Res* **50**: 7415-7421.
- Thamavit W, Bhamarapavati N, Sahaphong S, Vajrasthira S, Angsubhakorn S (1978) Effects of dimethylnitrosamine of induction of cholangiocarcinoma in *Opisthorchis viverrini*-infected Syrian golden hamsters. *Cancer Res* **38**: 4634-4639.
- Thamavit W, Kongkanuntn R, Tiwatech D, Moore MA (1987) Level of *Opisthorchis* infestation and carcinogen dose dependence of cholangiocarcinoma induction in Syrian golden hamsters. *Virchows Arch [B]* **54**: 52-58.
- Wykoff DE (1958) Studies on *Clonorchis sinensis*. III. The host-parasite relations in the rabbit and observations on the relative susceptibility of certain laboratory hosts. *J Parasitol* **44**: 461-466.

=국문초록=

이단계 발암기전상에서 담관암발생에 관한 간흡충감염의 역할

고려대학교 의과대학 기생충학교실

이재현, 양현모, 박응복, 임한중

간흡충은 담관내에 기생하면서 만성적 감염의 결과 최종적으로 담관암을 유발시키는 것으로 알려져 왔다. 실험동물에서 간흡충의 감염만으로는 담관암이 발생하지 않으며, 어떠한 외적 혹은 내적 발암성의 물질들과 병합하여 담관암이 형성하는 것으로 보고된 바 있다. 본 실험은 햄스터에서 간흡충의 감염과 dimethylnitrosamine(DMN)의 병합작용으로 담관암이 발생되었다는 모델을 이용하여 “발암기전의 2단계이론” 상에서 간흡충의 역할을 밝혀보고자 하였다. 총 90마리의 햄스터를 15마리씩 6군으로 나누었다. DMN → CS군의 햄스터에서는 먼저 15 ppm의 DMN을 4주 동안 음수 투여하고, 1주 후에 간흡충을 15마리씩 인공감염시켰다. 그리고 5주 후에 praziquantel로 간흡충을 치료하였다. CS → DMN군에서는 먼저 간흡충을 감염시키고 5주 후에 praziquantel로 치료하였으며 1주 후부터 DMN을 4주동안 투여하였다. DMN + CS군에서는 DMN과 간흡충을 동시에 투여하였으며 4주 후에는 DMN을 제거하였다. DMN군과 CS군은 각각 DMN과 간흡충만을 투여하였고 대조군은 아무것도 투여하지 않았다. 모든 실험동물은 13주 후에 부검하였으며 조직병리학적인 방법으로 간장을 검경하여 진단하였다. 실험결과 담관암은 DMN → CS군에서 3마리, DMN + CS군에서 11마리가 발생하였으며 나머지 군들에서는 암이 발생하지 않았다. 본 실험으로 2단계 발암기전상에서 간흡충은 담관암발생을 촉진하는 효과를 보였음을 알수 있었다.

(기생충학잡지 32(1): 13-18, 1994년 3월)