

AESTHETIC FACIAL BONE CONTOURING SURGERY IN KOREANS

Sang Hyun Woo, Kyung Ho Lee, Jung Hyun Seul

*Department of Plastic and Reconstructive Surgery
College of Medicine, Yeungnam University
Taegu, Korea*

Introduction

The problems of profile correction surgery in orientals have commonly been treated by simply modifying the facial soft tissues for the past decades. The results were unsatisfactory and unnatural for both patients and surgeons because surgery was confined to the soft tissue structure.

After the introduction of craniofacial surgical technique into aesthetic plastic surgery, facial contouring surgery, developed dramatically, and was widely accepted even in the orient. The face of orientals, which in the case of Koreans, is different from the caucasian, as orientals are usually mesocephalic when compared to the dolichocephalic caucasian. To obtain a beautiful facial frontal and profile view in orientals, the facial bone contouring surgery includes a wide variety of osteotomies of the protruded frontal bone, prominent malar eminence, protruded mandibular angle and retruded or protruded chin.

Materials and Methods

This retrospective study of 72 cases, includes patients with a protruded frontal bone (five cases), prominent malar eminence (21 cases), protruded mandibular angle (32 cases) and chin problems (14 cases) treated surgically by the authors from January of 1987 to September of 1990 were 8 male patients and 64 female patients. The indication for surgery was cosmetic in all cases and all of the patients were self-referred.

The amount of bone to be resected or to be grafted was determined by first examining the patient's photograph, x-rays and deciding on the amount of contouring desired.

Surgical Technique

1. Protruded frontal bone and prominent malar with zygomatic arch :

Through the bicoronal incision, an extensive

Table 1. Case analysis

Diagnosis	No. of patients
Protuded frontal bone	5
Frontal bossing (2)	
Hyperpneumatization of frontal sinus (3)	
Prominent malar eminence	21
Malar bone with zygomatic arch (10)	
Only malar bone (11)	
Portruded mandibular angle	32
Bilateral protrusion (30)	
Unilateral protrusion (2)	
Chin problems	14
Long chin (5)	
Retruded or short chin (5)	
Deviated chin (4)	
Total	72

subperiosteal dissection was performed to expose the frontal bone and supraorbital rim. The protruded frontal bone and frontal sinus were reshaped by set-back osteotomy. To reduce frontal bossing, the full layer of frontal bone was removed and reshaped. However, in hyperpneumatization of the frontal sinus, only the anterior wall of the frontal sinus was removed and reshaped.

Treatment of prominent malar with zygomatic arch required segmental osteotomy on the central portion of the zygoma body and posterior margin of the arch using of oscillating saw.

After complete mobilization of the zygoma, the prominent area was shaped to the desired shape and fixed with interosseous wiring. The remaining sharp edges were contoured using

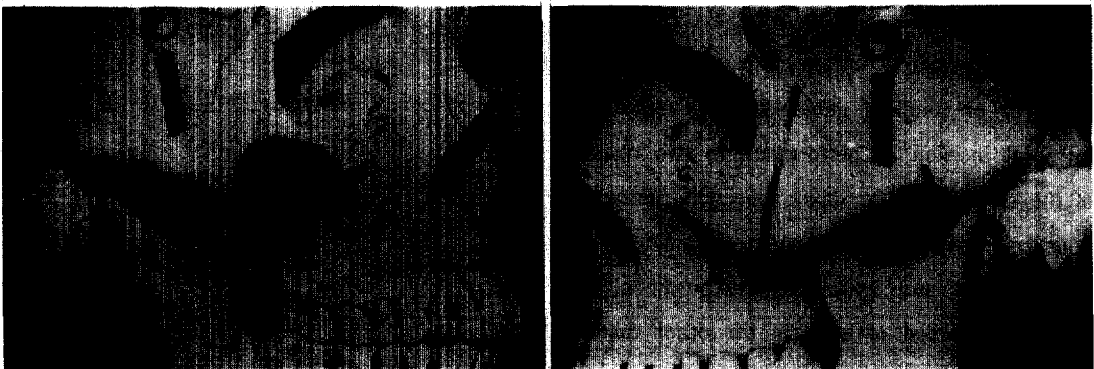


Fig. 1. CT Partial resection of the prominent malar through intraoral approach (left, black mark) and osteotomy site on the zygoma body and posterior margin of the arch through bicoronal approach in case of prominent malar with zygomatic arch (right, black line).

a high speed bur. When patient had only a prominent malar, the prominent portion was partially resected on the outer layer of zygoma through an intraoral approach (Fig. 1).

2. Protruded mandible angle :

An intra-oral incision was made over the anterior edge of the ascending ramus of the mandible, extending anteriorly to the level of the third molar. Subperiosteal dissection was performed to expose the proposed osteotomy site over the lateral mandibular ramus and angle. The masseter muscle retracted laterally. Then the lateral mandibular angle is marked according to the preoperative plan and resected using an oscillating saw, and the remaining sharp edges were contoured using a high speed bur.

The deep portion of masseter muscle was then resected as indicated.

3. Chin problems :

Long chin and deviated chin was segmentally resected. In two cases of deviated chin, resected bone from the chin was grafted on the deficient side by reversing it.

For a retruded or short chin, a sliding genioplasty or jumping genioplasty through the intraoral incision as performed. In two cases of the short chin after bone resection, autogenous bone graft was combined with genioplasty in one case and hydroxyapatite (Surgibone®) was used instead of bone in the other case.

Results

The results, determined by both patient and surgeon, were good to excellent in 65 of 72 cases (90%)

Preoperative frontal bossing and hyperpneumatization of the frontal sinus was converted to a more natural appearance of forehead after contouring surgery (Fig. 2,3).

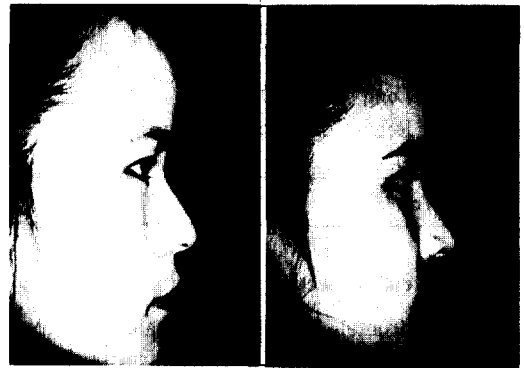

Fig. 2. Profile view of the frontal bossing. pre-operative (left) and post-operative view (right).



Fig. 3. Profile view of the hyperpneumatization of frontal sinus. Pre-operative (left) and post-operative view (right).



Fig. 4. Frontal view of the prominent malar eminence with zygomatic arch. Pre-operative (left), post-operative view (middle) and operative procedure (right).

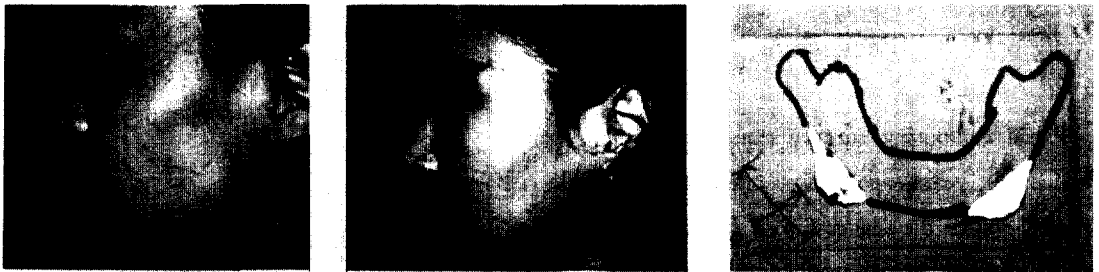

Fig. 5. Profile view of the protruded mandibular angle. pre-operative (left), post-operative view (middle) and resected bone (right).

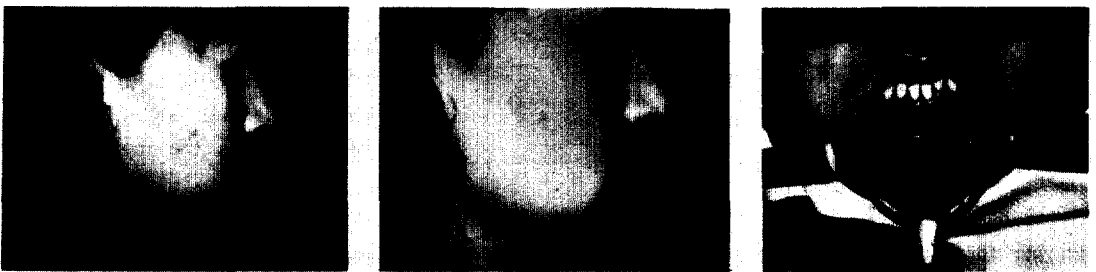

Fig. 6. Profile view of the short chin. Pre-operative (left), post-operative view (middle) and operative procedure (right).

With reduction of the prominent malar eminence, the wide face was converted into slimmer cheeks with a more feminine appearance (Fig. 4).

The square appearance of the lower face

in patient with a protruded mandibular angle has been converted to a thinner, curved contour and is more feminine (Fig. 5).

The short chin was converted to a more natural appearance (Fig. 6).

We experienced eight complications which included asymmetry (one case), maxillary sinusitis (one case), dimpling of a cheek (one case) after malar bone surgery, mandible fracture (one case), contact burn on lip (one case), hemorrhage after mandibular angle surgery (two cases) and infection (one case) after chin surgery.

Discussion

Facial contouring surgery came into prominence 20 years ago when craniofacial surgeons, under the leadership of Dr. Paul Tessier, showed that a congenital facial defect could be corrected by radical alteration of the facial skeleton¹⁾. The aesthetic facial bone contouring surgery by modifying the facial bone is established as the result.

Within the last decade, as the demand for aesthetic facial bone surgery has increased, surgeons have been challenged to discover effective methods that are safe and secure. By altering the facial skeleton, the surgeon can create a more profound aesthetic change and can enhance the patient's body images.

The shape and contour of the forehead is provided basically by the frontal bone, which is covered with relatively thin soft tissue coverages. So subtle changes in the frontal bone will change the appearance of the forehead remarkably. In Koreans, a broad forehead with minimal frontal bossing and round curva-

ture is preferred. The curvature of the forehead, which from the glabella to the forehead hairline, curves gently backward as one proceeds toward the hairline making an arc of approximately -7 degree in females and -10 degree in males (Fig. 7)²⁾.

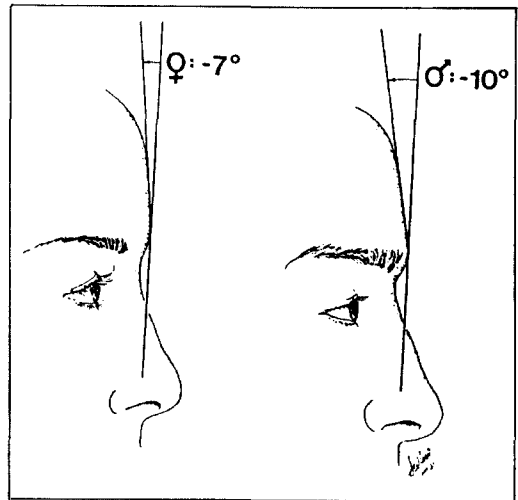


Fig. 7. The forehead inclination differs in the ideal situation in male and female. Females have a steeper inclination as shown. Also to be noted is the naso-frontal angle, which is typically acute in the males.

A mildly elevated forehead, due to hyperpneumatization of the frontal sinus, was treated with autogenous bone graft on supra-sinus and nasal root area. In severe cases, bones were removed and reshaped with an oscillating saw and interosseous wiring.

Our cases of the preoperative naso-frontal angle (± 130 degrees) converted to $140-145$ degrees after operation (normal range of the naso-frontal angle in caucasian is $115-120$ de-

gree³⁾) revealed a more natural appearance in our own concept of Korean beauty. The caucasian is more angulated in the naso-frontal junction area.

In contrast with the western concept of beauty, in which well defined and prominent cheek bones are important in facial aesthetics, malar prominences are considered as an unpleasing and undesirable feature in Koreans because they provide an aggressive and masculine appearance. The malar region constitutes an area of extreme variability in projection and form⁴⁾. However, most of Korean women prefer a more smooth and round shape in the malar and zygomatic area. In a few cases of prominent malar with full cheeks, buccal fat pads were removed simultaneously after partial resection of the malar bone through the intraoral approach⁵⁾ as done by others.

If the maxillary sinus was opened during the resection of the malar bone, copious irrigation in the antrum was done and antibiotics were given for prevention of maxillary sinusitis. When the temporal fascia was torn during the osteotomy, fascia was repaired tightly to prevent an irregular surface of lateral forehead area.

Treatment of the protruded mandible angle is the most popular contouring surgery among Koreans, especially in young females. Because it gives the face a square, coarse and masculine which is considered to be unattractive in orientals. The exact amount of bone resection is crucial in achieving successful surgery.

The amount of bone to be resected is determined by first examining the photograph and deciding on the amount of contouring desired. After resection of the angle, the masseter muscle is then partially resected in selective cases. Baek⁶⁾ described muscular hypertrophy as another problem and recommends excision of the masseter muscle.

A key factor in determining the proper vertical proportions of the anterior maxilla and mandible is the lip to tooth relationship. The lips at rest vary from lightly touching to 3 to 4 mm apart. Approximately 2 mm of maxillary incisor exposure at rest is desirable. In the lower face region, the distance from subnasale to stomion is approximately one third of total lower face height (Fig. 8)⁷⁾.

Long chin and deviated chin are segmentally resected according to this relationship. After sliding genioplasty or jumping genioplasty, in retruded or short chin, two cases revealed short length from stomion to menton. Those cases utilized autogenous bone graft (one case) and hydroxyapatite graft (one case) for lengthening of the chin.

We experienced several serious postoperative complications. Maxillary sinusitis after malar bone resection was treated by the Caldwell-Luc procedure. A mandible fracture from the angle to the glenoid fossa was managed with conservative treatment of immobilization for 3 weeks. Two patients developed massive bleeding, which in one case was treated conservatively after transfusion of 5 pints, howe-

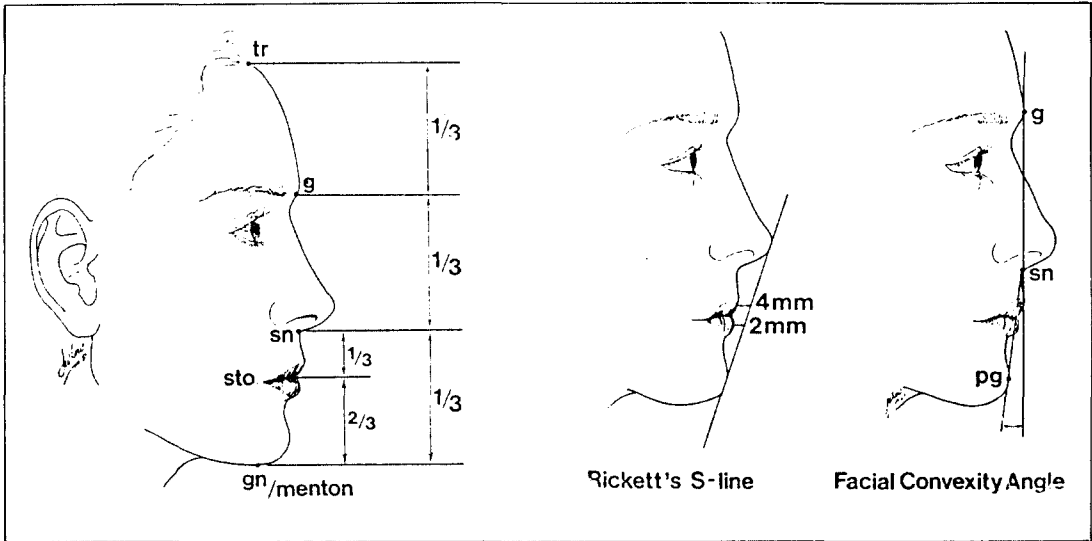


Fig. 8. (Left) The lower face height is measured from subnasale(sn) to gnathion(gn) or menton(me). In the lower face region, the distance from subnasale to stomion(sto) is approximately one third of this distance while the measurement from stomion to menton makes up two thirds of total lower face height. (Right) The position of the chin point can be assessed by several methods. Using Rickett's method a line is drawn from nasal tip to chin point. The upper and lower lip should lie 4 mm and 2 mm posterior to this line, respectively. Greater or lesser amounts of these measurements will indicate a retrusive or prominent chin if nasal and maxillary position is normal. An alternative method is to draw a perpendicular line from the glabella through the subnasale with the held in a horizontal plane. The chin point should lie within a few millimeters of such a line.

ver one case was treated after ligation of the facial artery through the external submental incision. One patient developed an infection, which manifested as a cellulitis over the operative cheek. This patient was treated with antibiotics and all of the wounds healed by secondary intention.

Those procedures especially prominent malar eminence and protruded mandible angle are commonly encountered in Koreans owing to different facial characteristics and different

aesthetic sensibilities compared to caucasians.

After complete evaluation of our approach, we concluded a long term follow up period after surgery is required.

Summary

Satisfactory results were obtained in 90% of all cases after aesthetic facial bone contouring was performed.

In these cases, no visible scar on the face resulted by using the bicoronal and intraoral approaches.

We experienced eight cases of postoperative complications. Patient selection and preoperative planning is very important in achieving superior cosmetic results in facial bone contouring.

References

1. Terino EO : Alloplastic facial contouring by zonal principles of skeletal anatomy. Clin Plast Surg 19(2) : 487-510, 1992.
2. Bartlett SP Wornom I III, Whitaker LA : Evaluation of facial skeletal aesthetic and surgical planning. Clin Plast Surg 18(1) : 1-9, 1991.
3. Krause CJ : Aesthetic facial surgery. 1st ed, J.B. Lippincott Co, Boston, 1992, p 498.
4. Whitaker LA : Aesthetic augmentation of the malar-midface structures. Plast Reconst Surg 80 : 337-346, 1987.
5. Dubin B and Jackson IT : Anatomy of the buccal fat pad and its clinical significance. Plast Reconst Surg 83 : 257-262, 1989.
6. Baek SM : The prominent mandibular angle. Plast Reconst Surg 83 : 272-290, 1989.
7. Sepa SL, Mausner ME Kawamoto HK : Sliding genioplasty as a local anesthetic outpatient procedure. Plast Reconst Surg 80 : 55-67, 1987.

- 초 록 -

한국인의 안면골 윤곽 성형술

우상현, 이경호, 설정현

영남대학교 의과대학 성형외과학교실

종래의 미용성형수술은 피부를 포함한 연부조직에 국한되었으나 아름다움에 대한 욕구의 증가와 함께 연부조직의 교정술만으로는 만족의 정도가 충분치 않아 안면골 윤곽 성형술이 많이 시행되고 있다. 이상적인 동양인의 안면윤곽 형태는 서양인과 달리 계란형의 둥근 형태를 선호하여 전두골과 관골의 돌출이나 사각지거나 앞뒤로 치진 하악골은 윤곽성형술의 적응증이 될 수 있다.

본 교실에서는 1987년부터 1990년까지 72명의 환자를 대상으로 다양한 수술방법을 이용하여 안면윤곽 성형술을 시행하여 주요 합병증없이 90% 이상에서 만족할 만한 결과를 얻었으므로 문헌 고찰과 함께 보고하는 바이다.

Key Word : Facial bone contouring surgery